

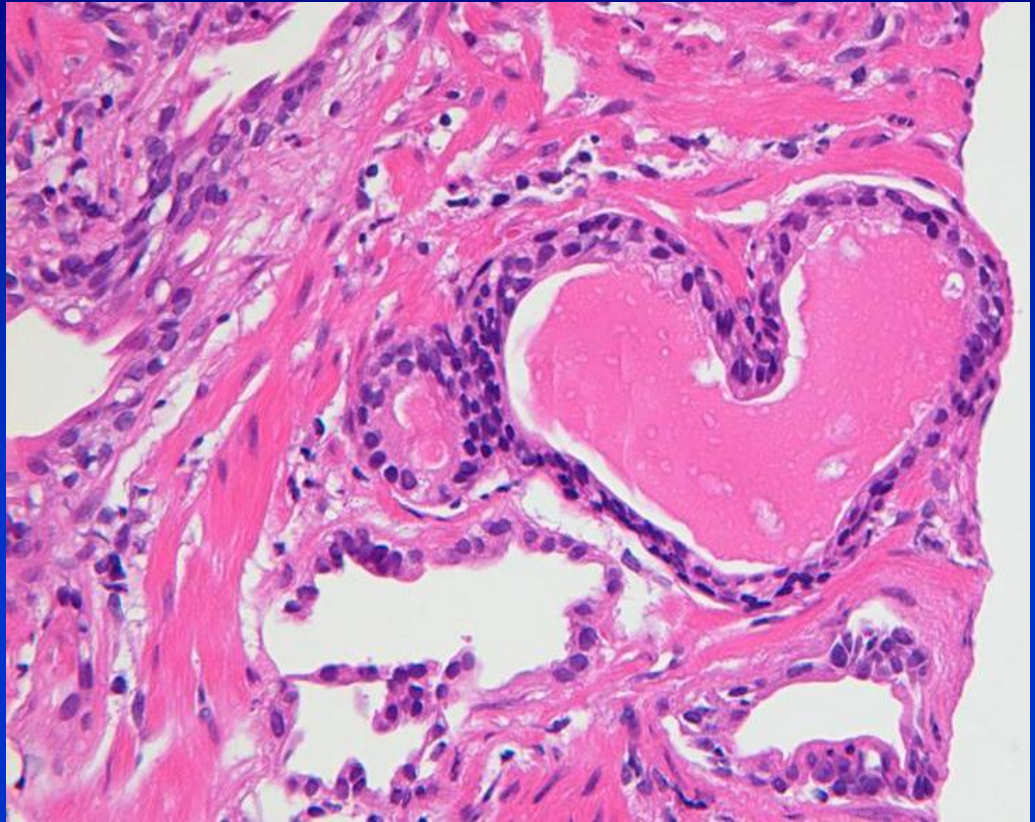
# Immunohistochemistry in prostate pathology: Recent Advances



**Jae Y. Ro, M.D., Ph.D.**

**Weill Medical College of Cornell University, Methodist Hospital,  
and UT MD Anderson Cancer Center, Houston, TX  
Yonsei and Ewha University College of Medicine,  
Seoul, Korea**

**November 9, 2013**



**Do your BeST!**

**November 9, 2013**

# Do your BeST!

- **B** represents Basic.
- e (effort)
- **S** represents Study.
- **T** represents Think.
- **E** represents Enjoy.

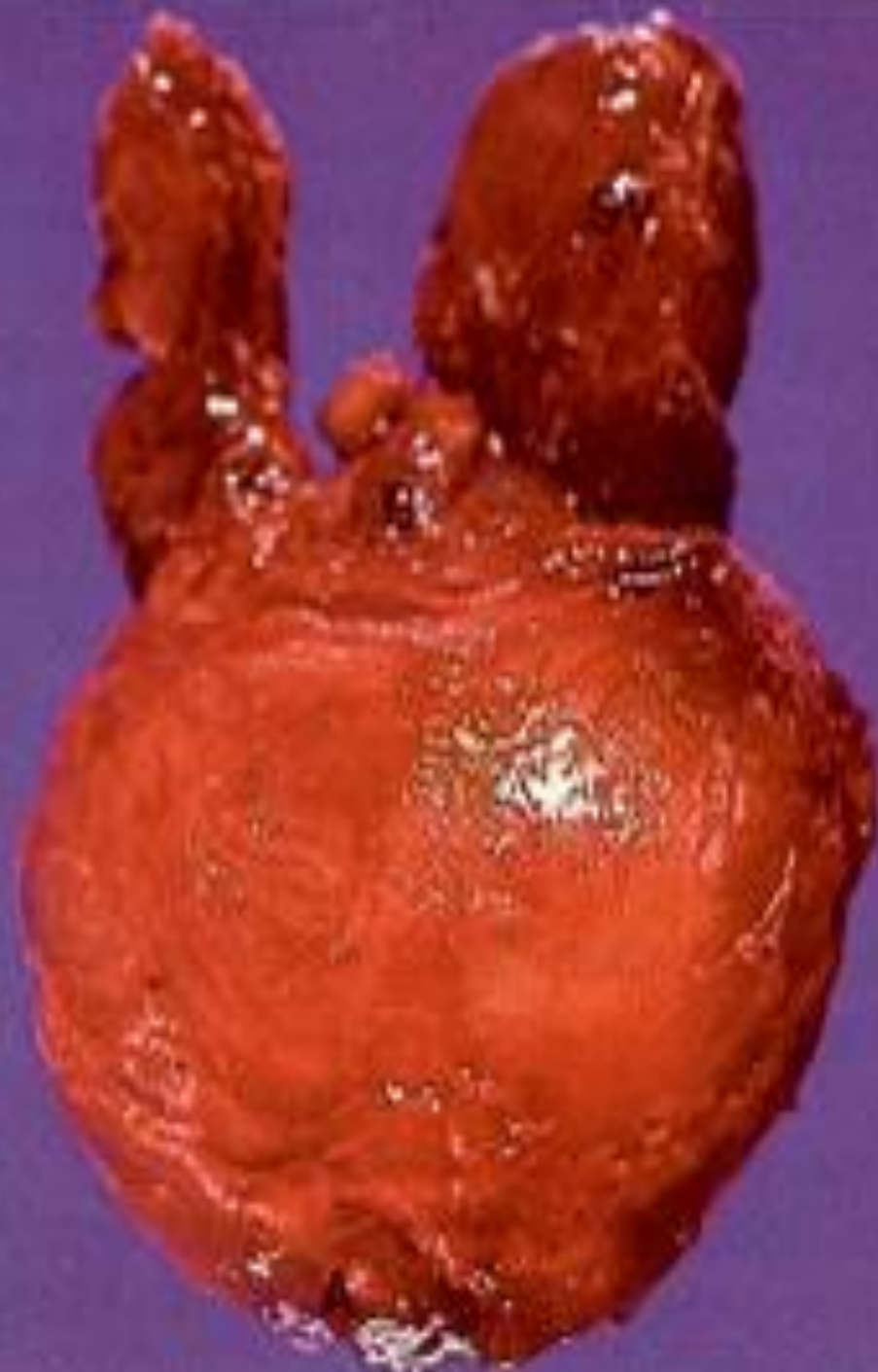# Contents

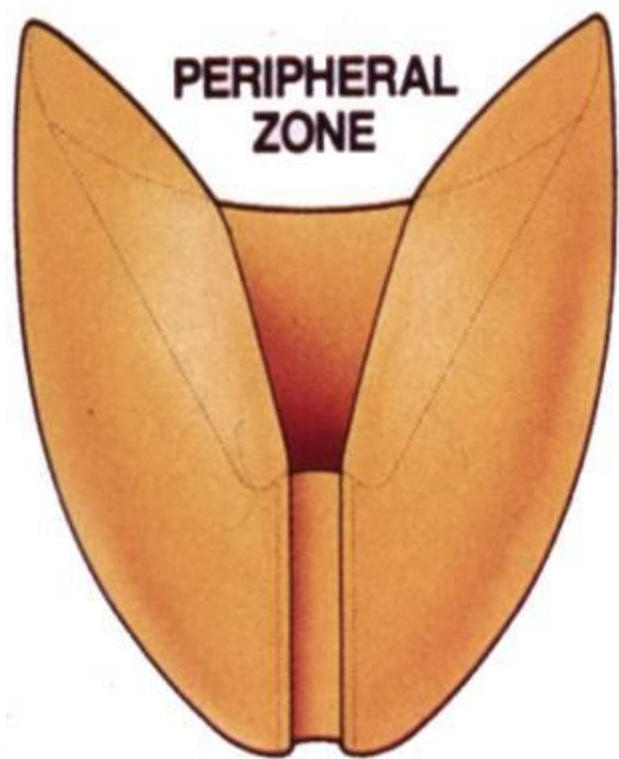
- 1) Basic
- 2) Study
- 3) Think
- 4) Enjoy

# 1. Basic

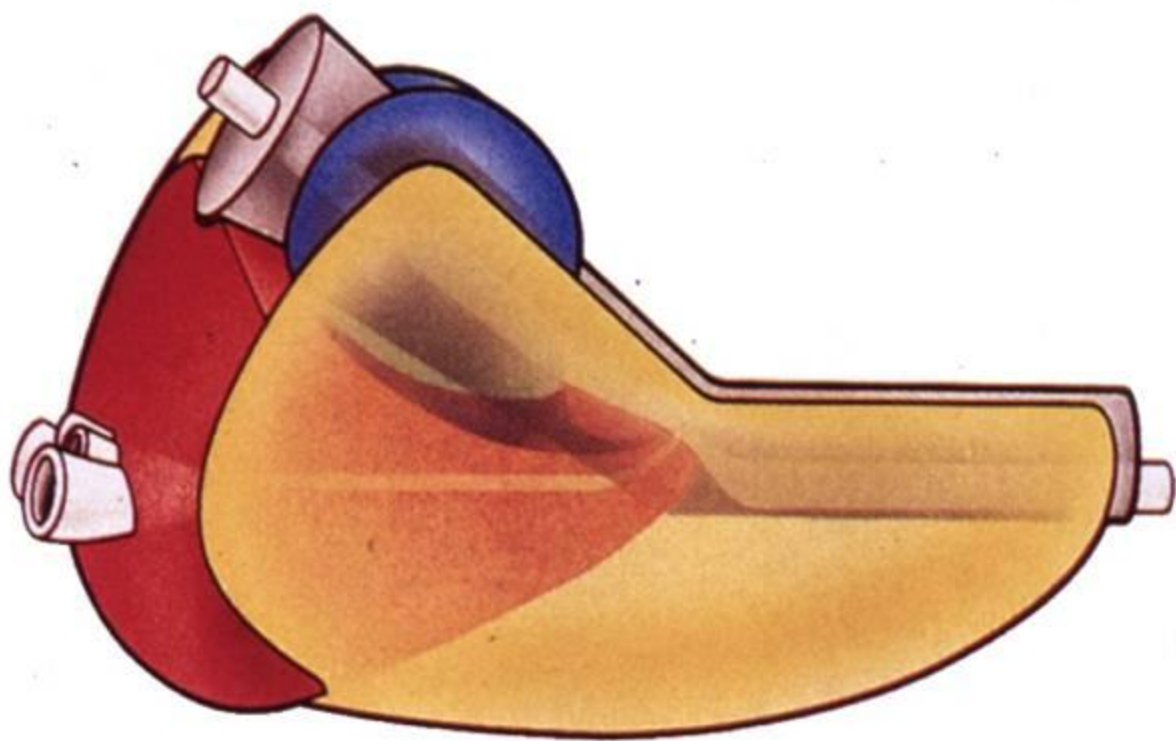
- Prostate anatomy
- Prostate histology
- Immunohistochemistry
- Your limitation
- Get second opinion

**(Consultation. Communication and Collaboration)**





a.



b.

# Disease of Prostate

P. Zone (70%) T. Zone (5-10) C. Zone (20)

CA (70%)

PIN

CA (25%)

BPH

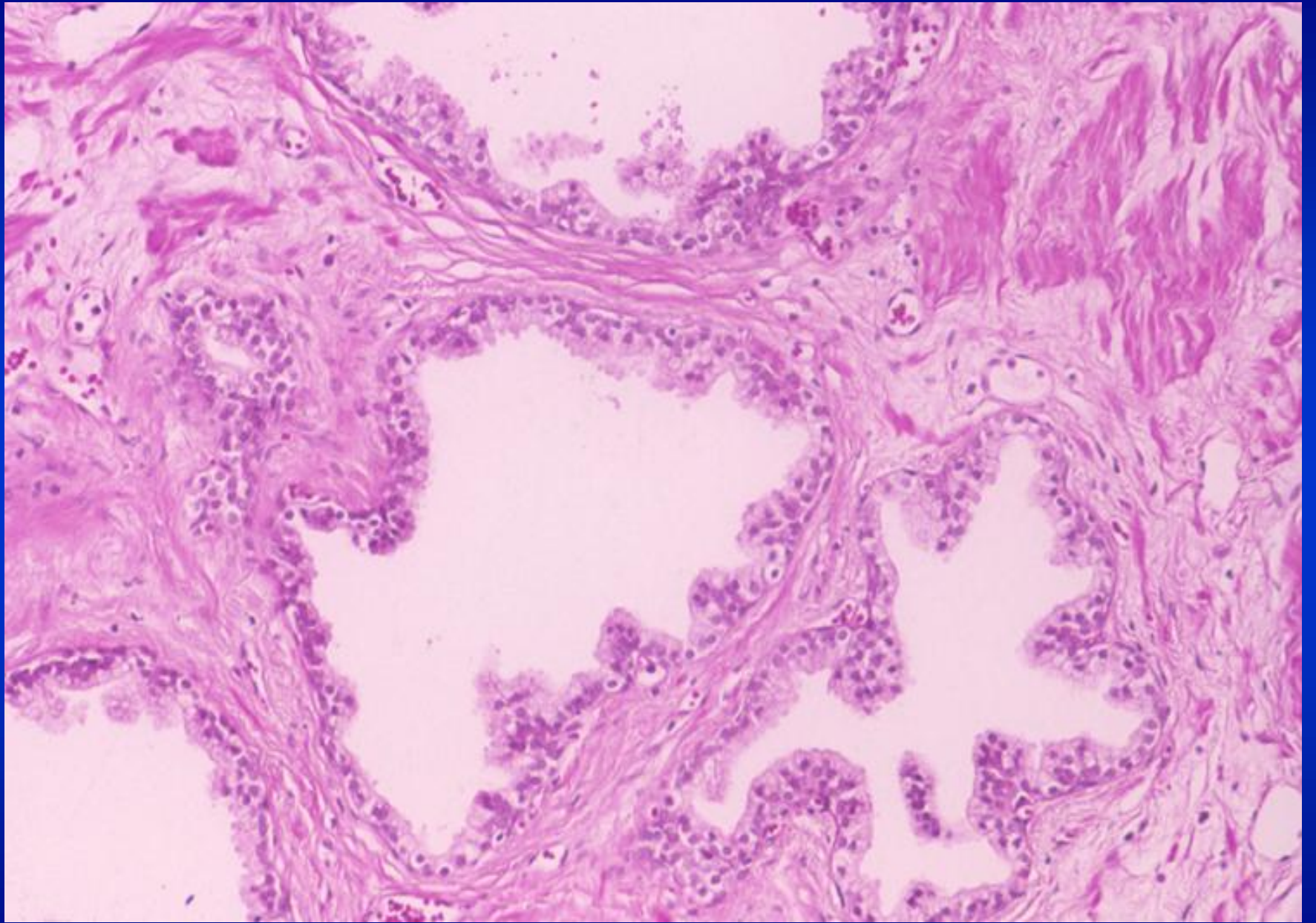
AAH

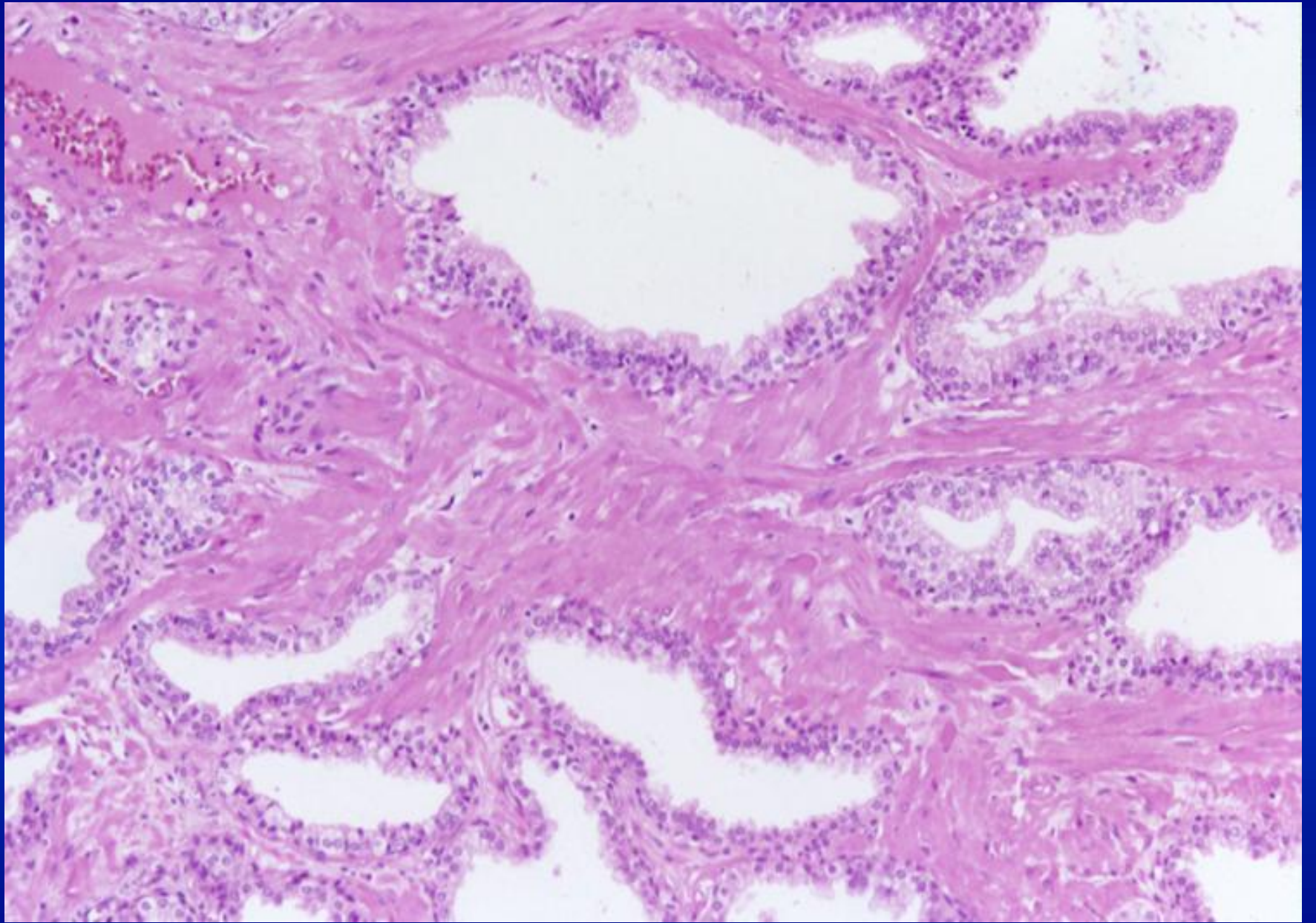
BCH

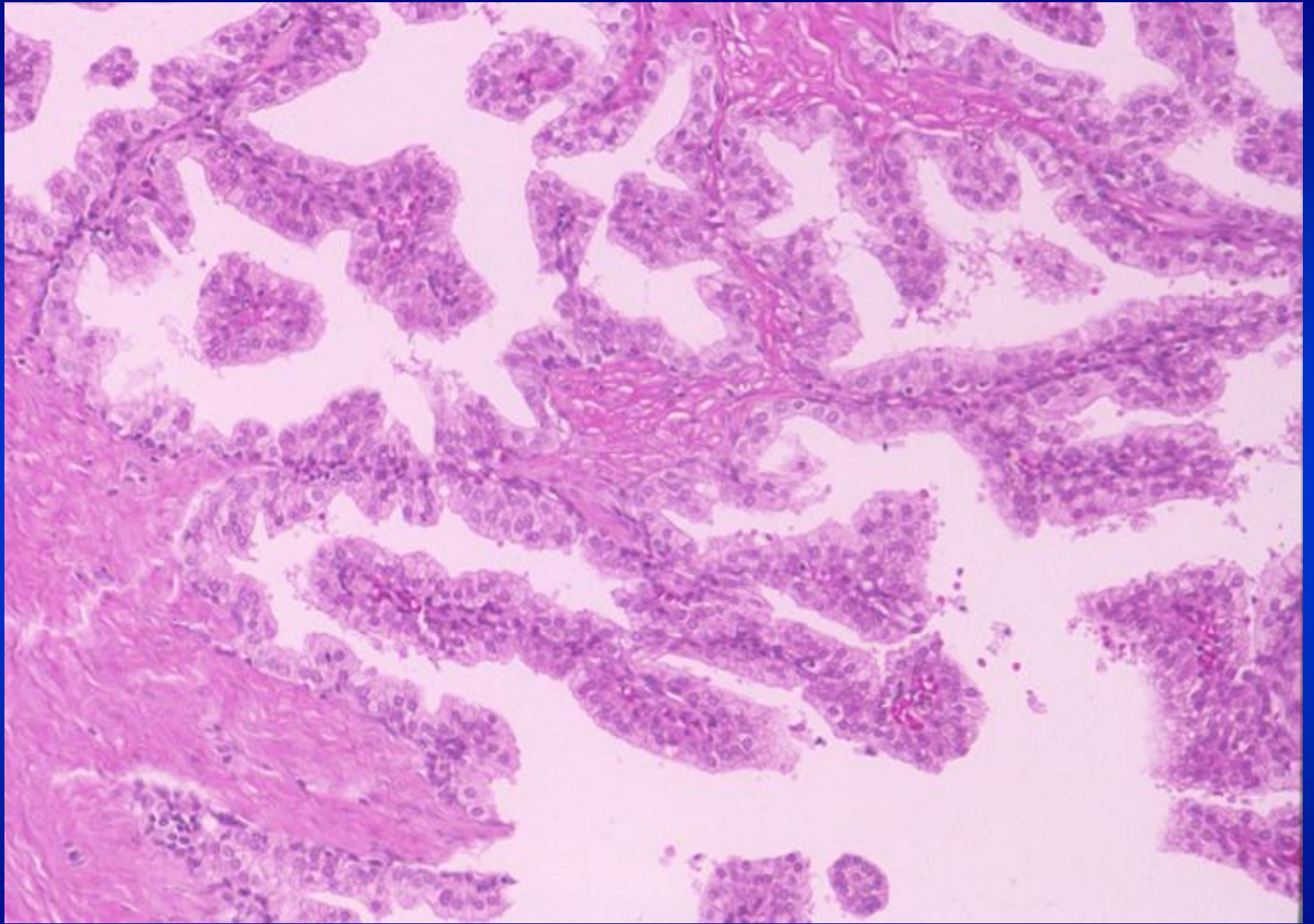
CCCH

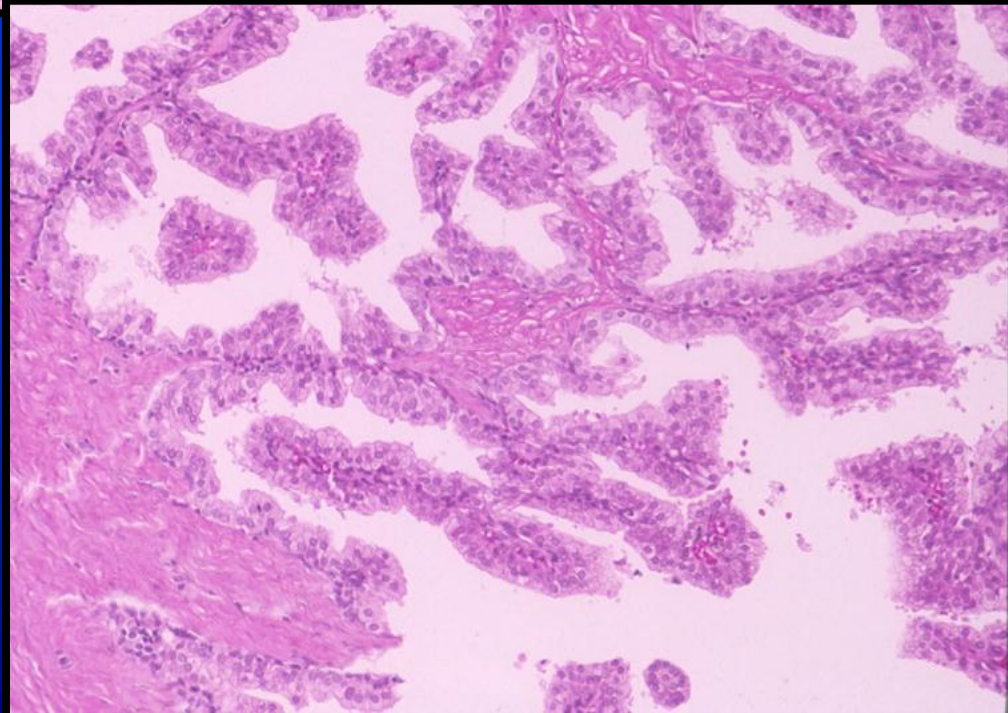
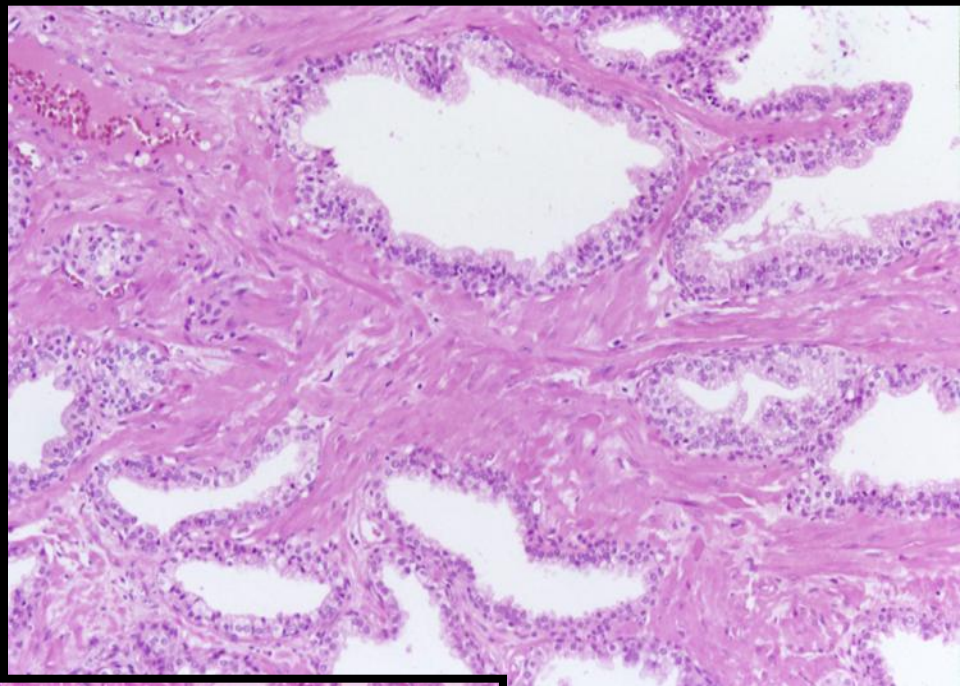
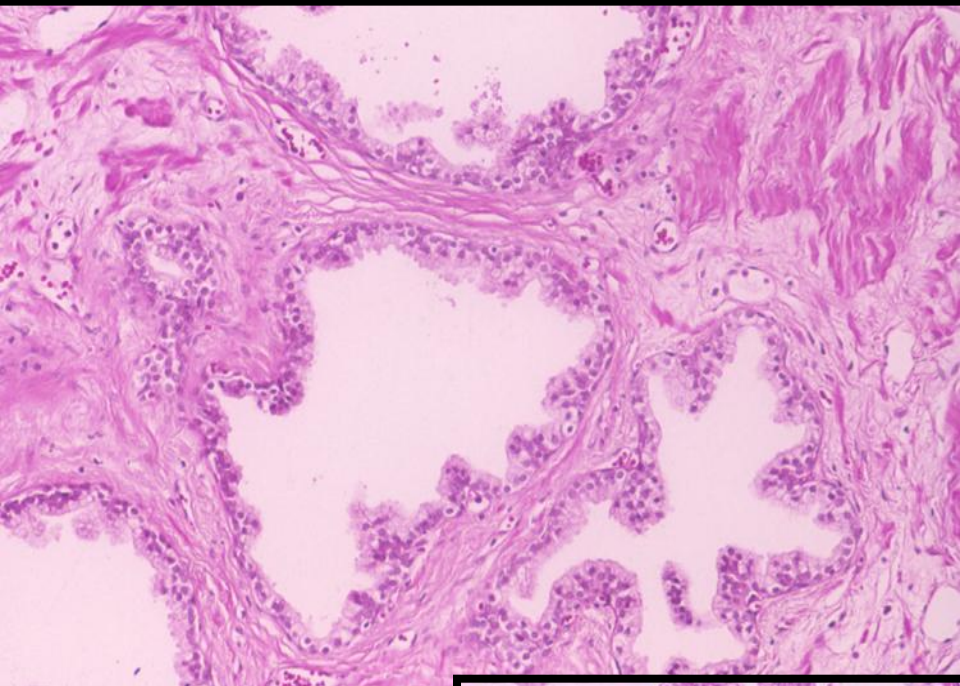
SA

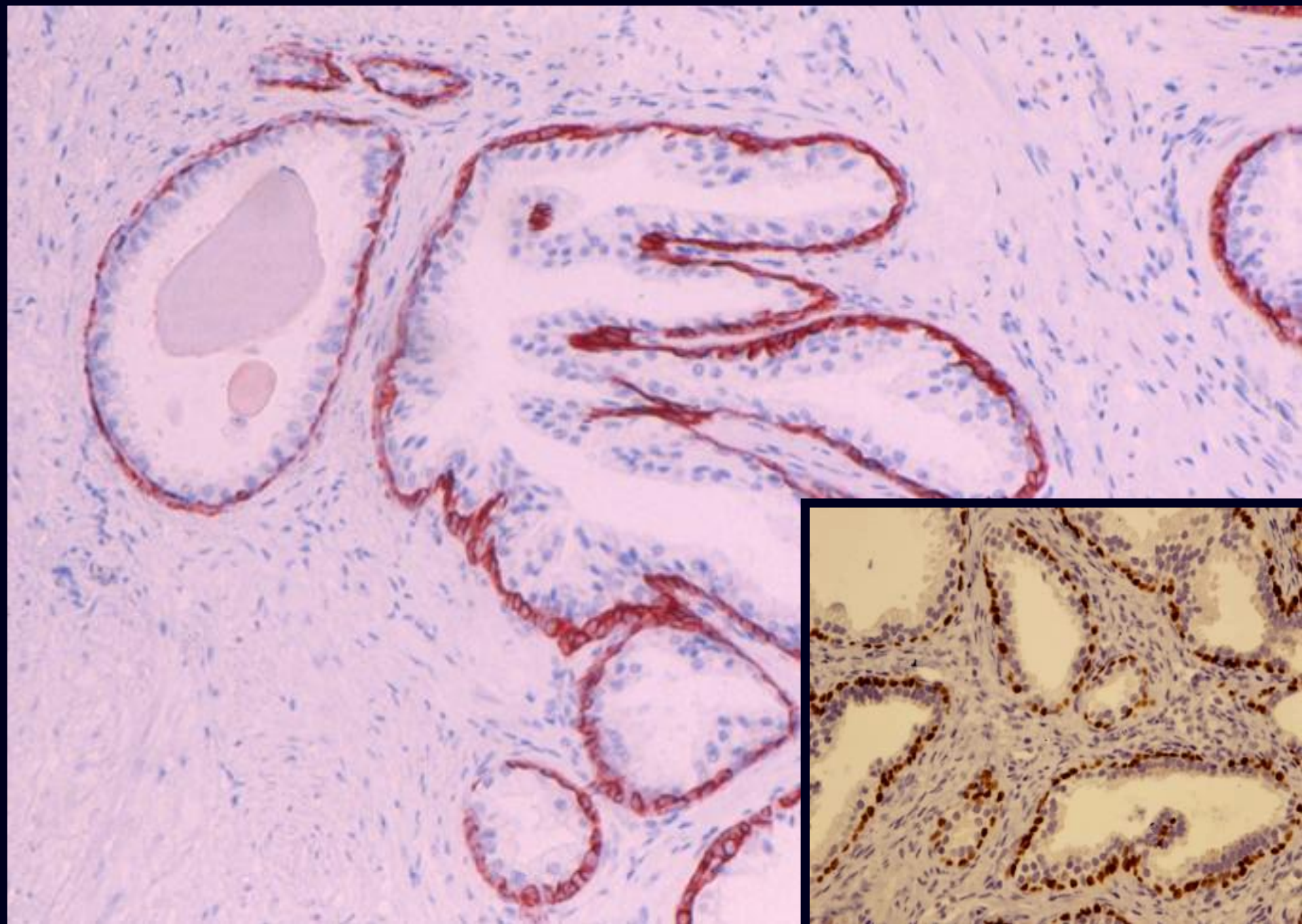
CA (<5%)





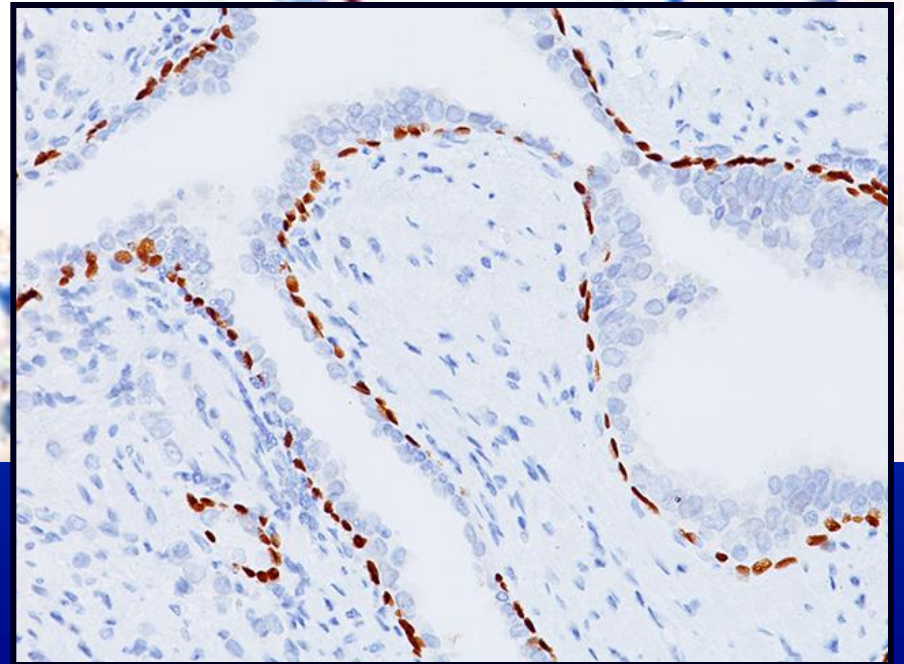
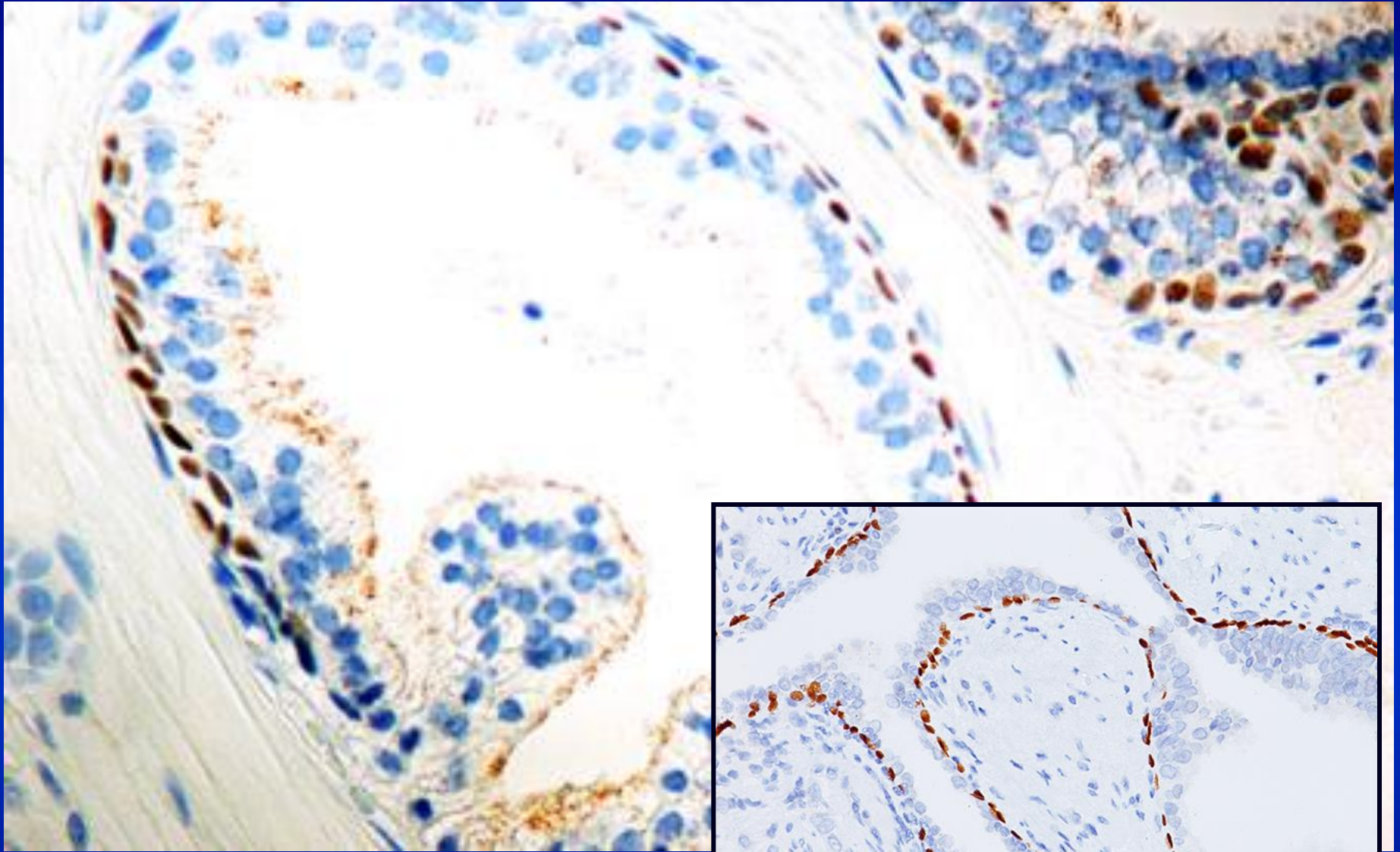


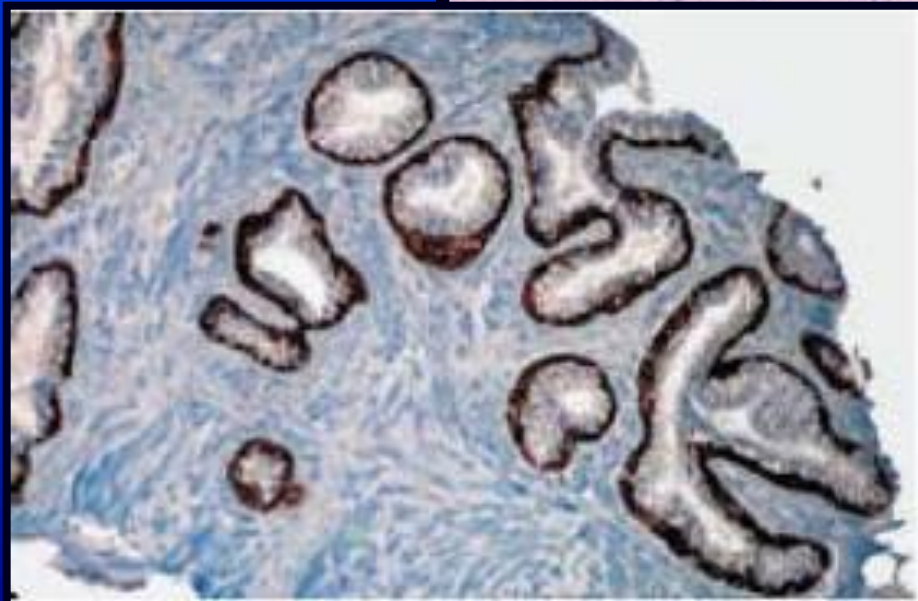
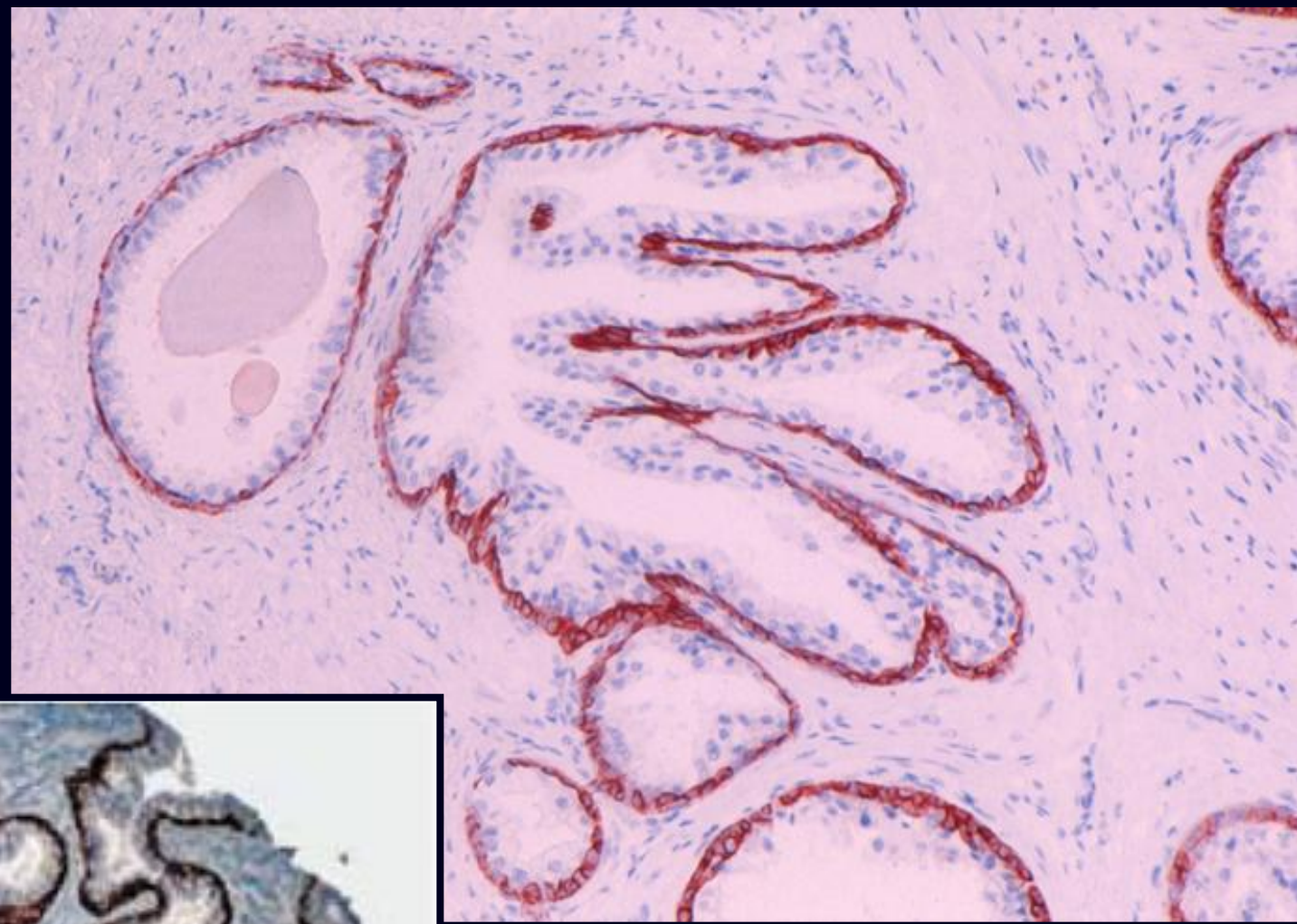



# Basal cell markers

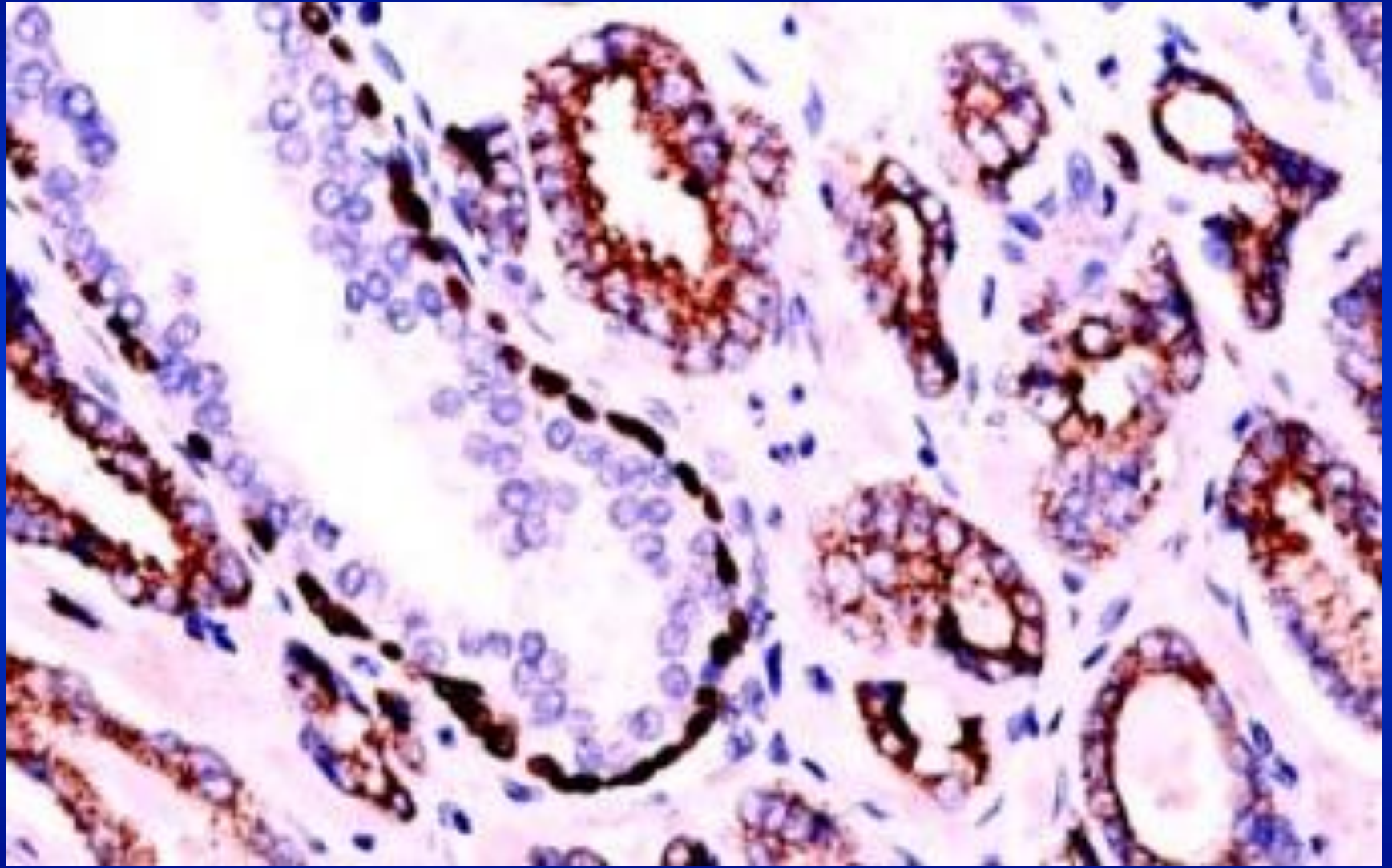
- P63
- ✓ cancer cells aberrantly +: AJSP  
2008;32:1890-1895
- High molecular cytokeratin  
(34 $\beta$ E12)
- ✓ cancer cells aberrantly +: AJSP  
2008;32:1890-1895
- CK5/6
- P63 combined with 34 $\beta$ E12 or CK5/6

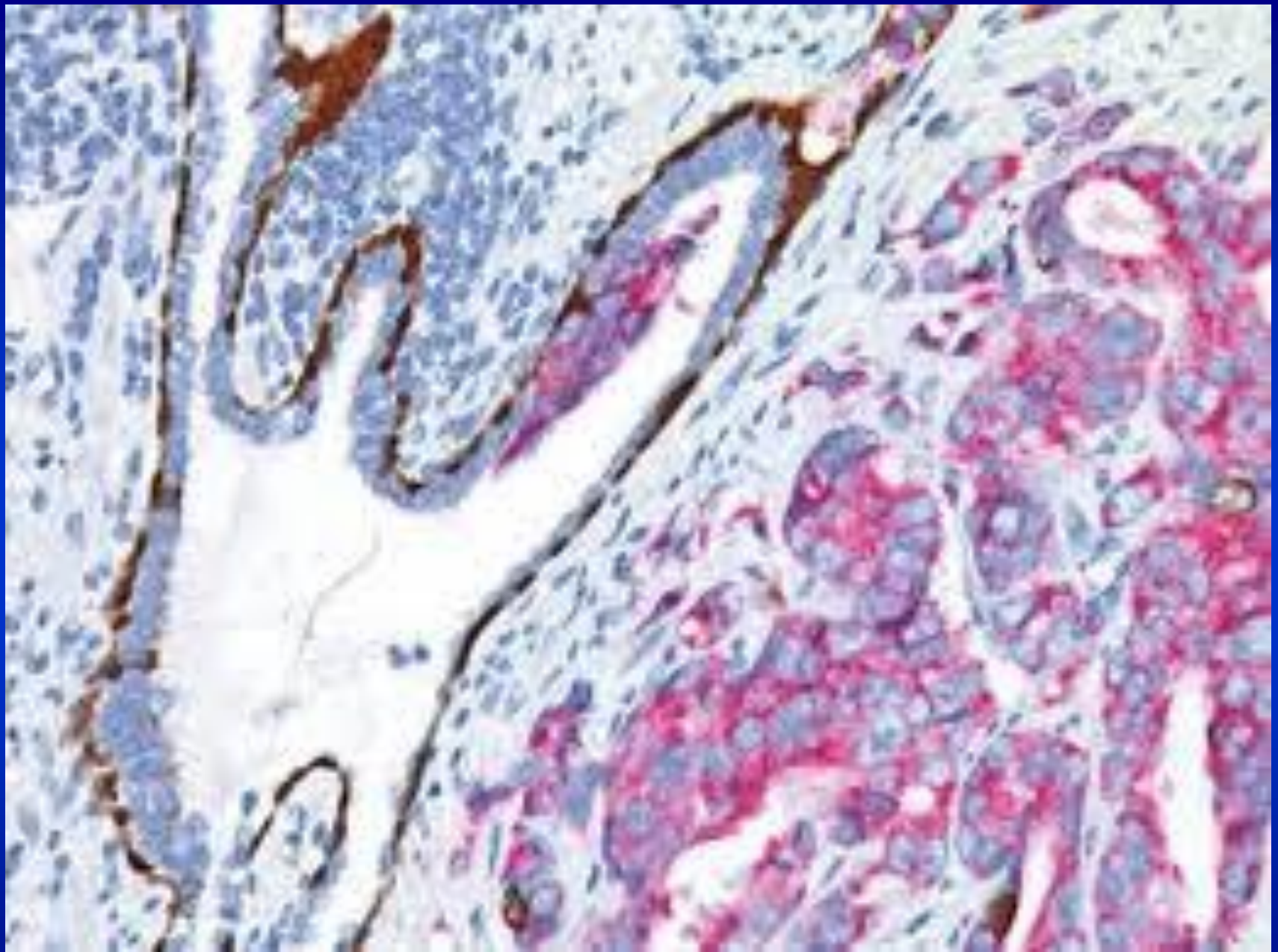




# Markers for Prostate Cancer

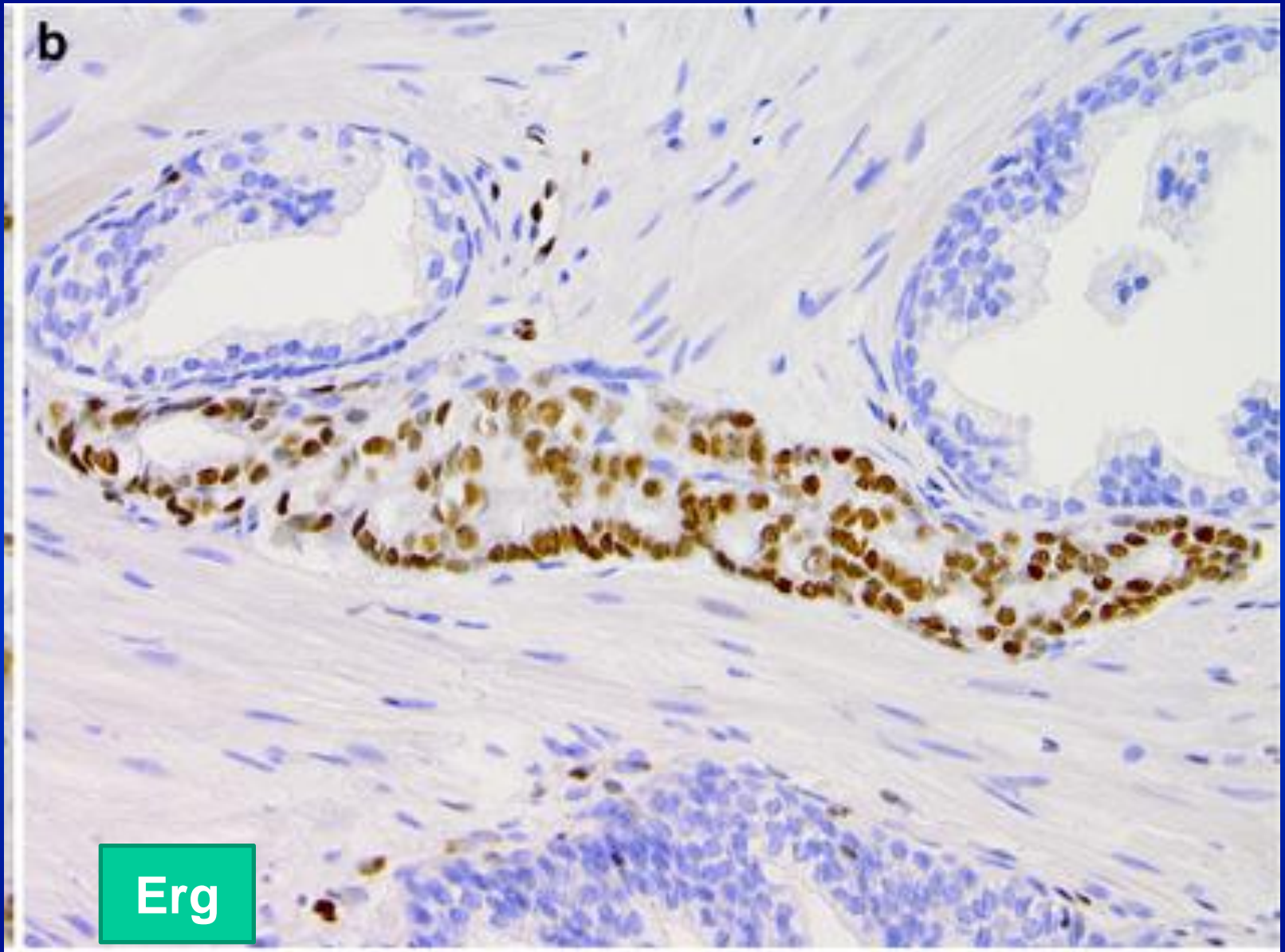
- Alpha-methyl-CoA-Recemase (AMACR)
- ERG (TMPRSS2-ERG fusion)
- Cocktailes of AMACR and Basal cell markers
  - ✓ AMACR + P63
  - ✓ **AMACR +HMWCK + p63 (PIN4)**
- Other markers
  - ✓ PAX2 and PAX8/MUC6 (Seminal vesicle)
  - ✓ Ki-67 (MIB-1)
  - ✓ NKX3.1, human glandular kallikrein 2 (hK2), proPSA, Ep-CAM, Ataxia-telangiectasia Mutated



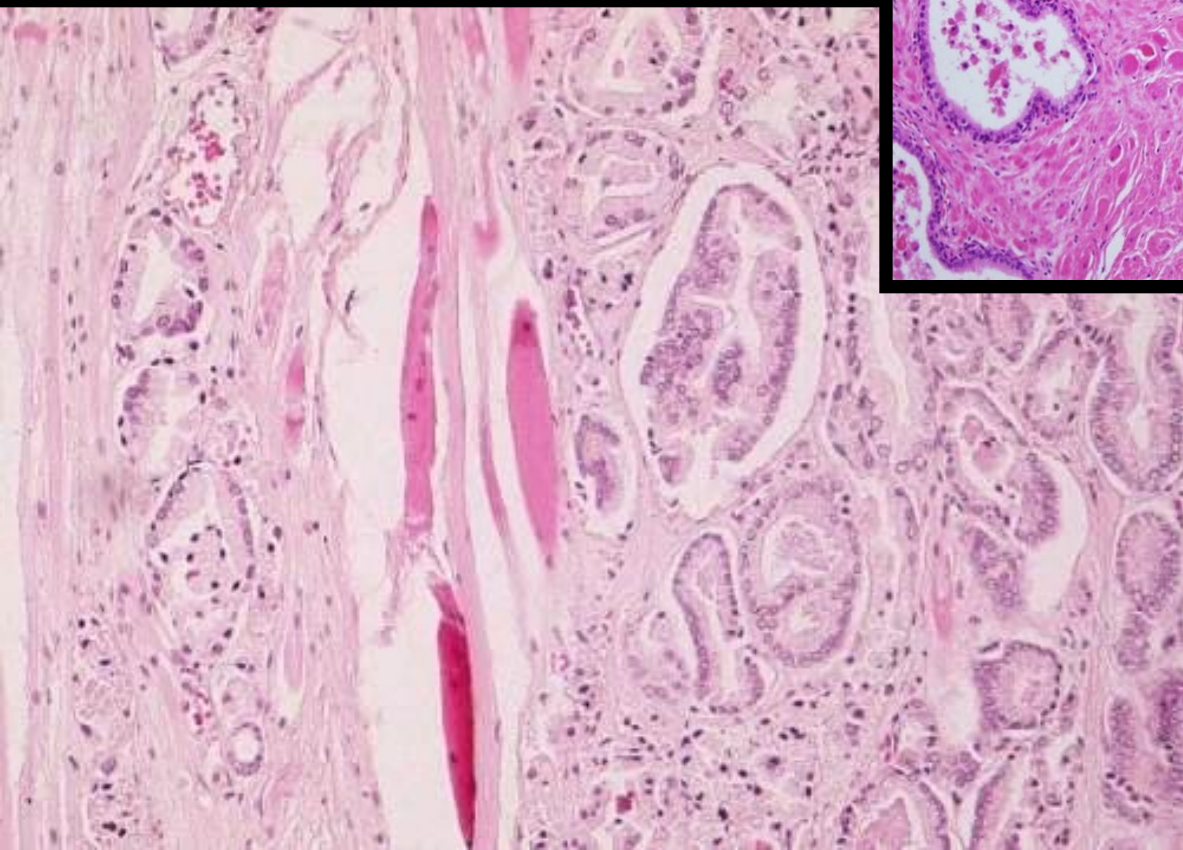
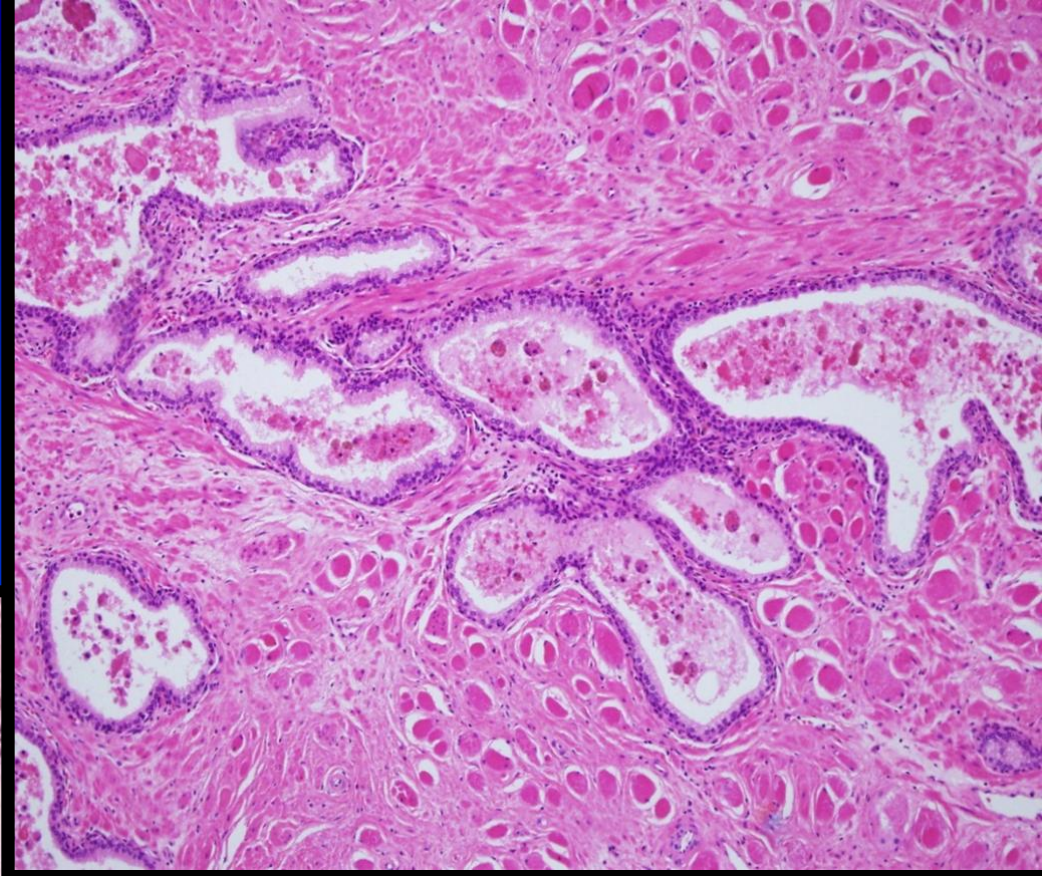


**PIN4 cocktail (AMACR, P63, HMCK)**

**b**



**Erg**

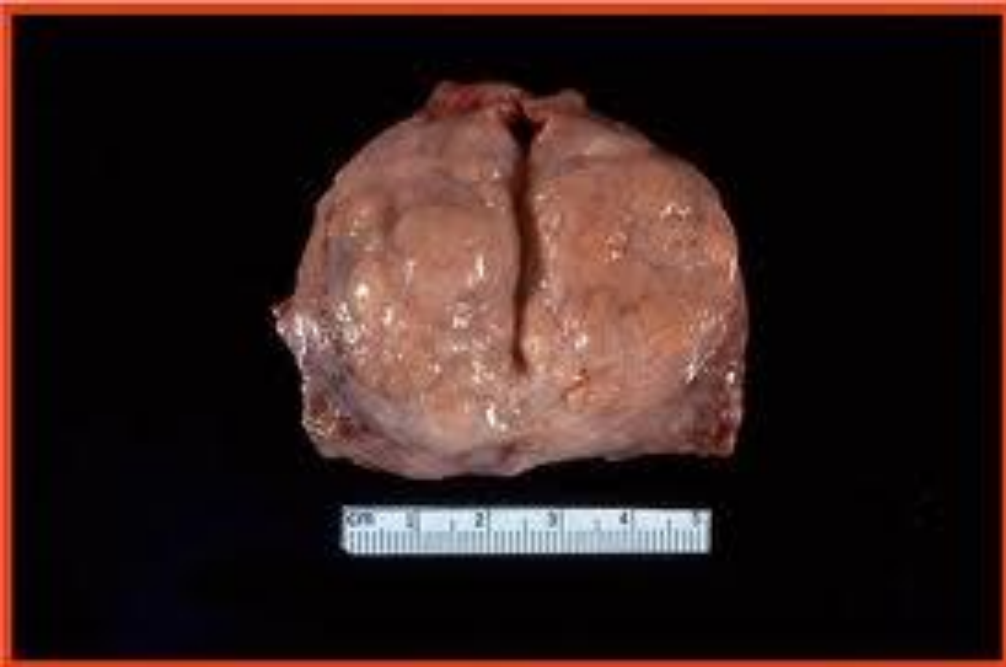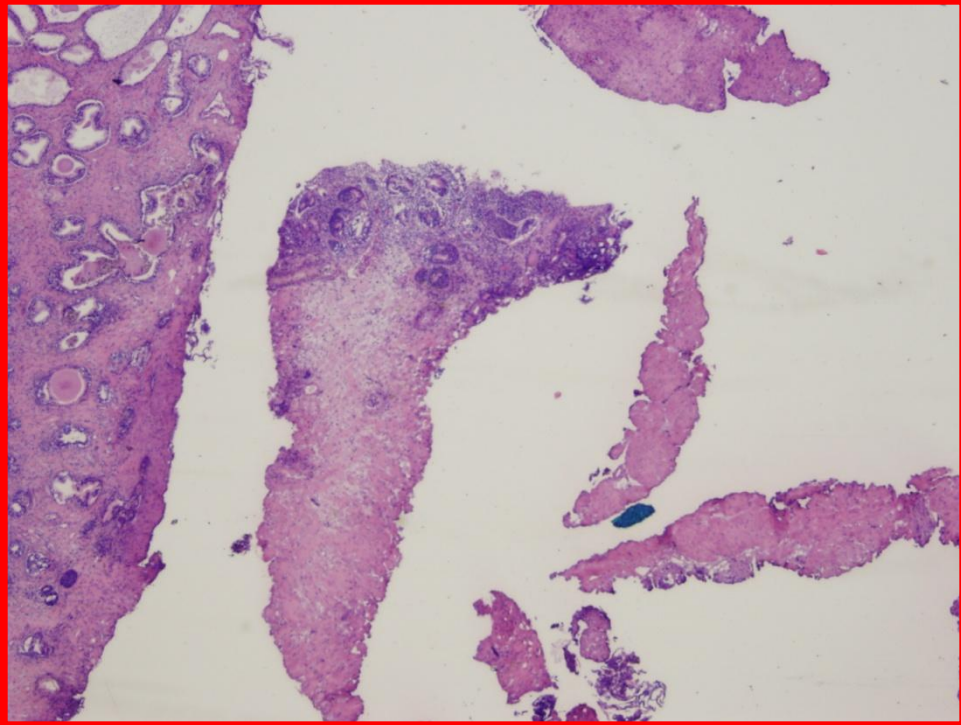
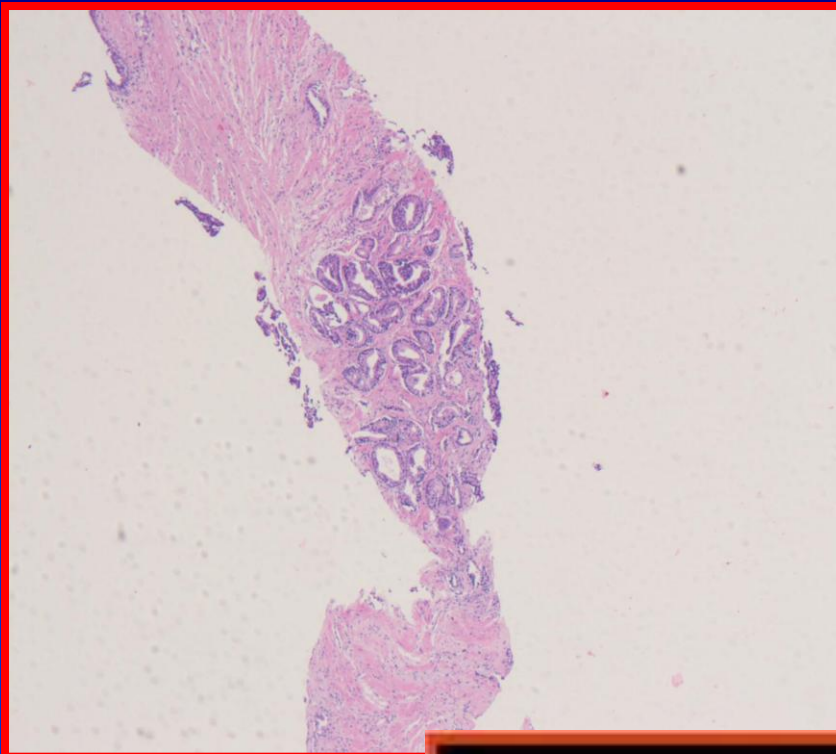




# 2. Study

## Immunohistochemistry

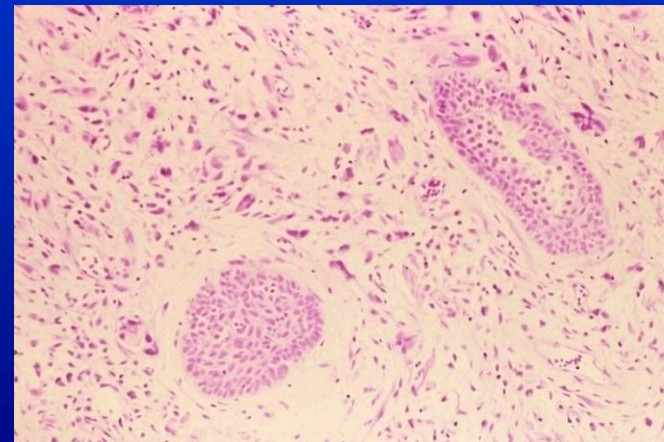
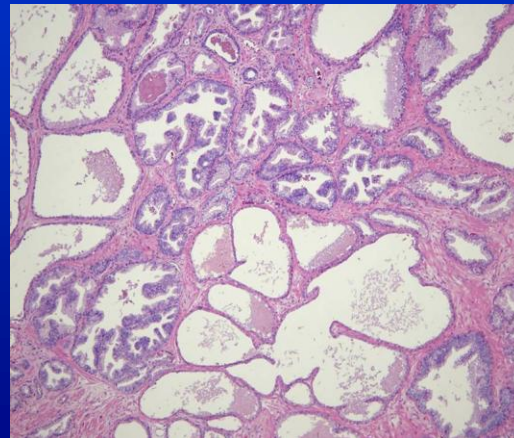
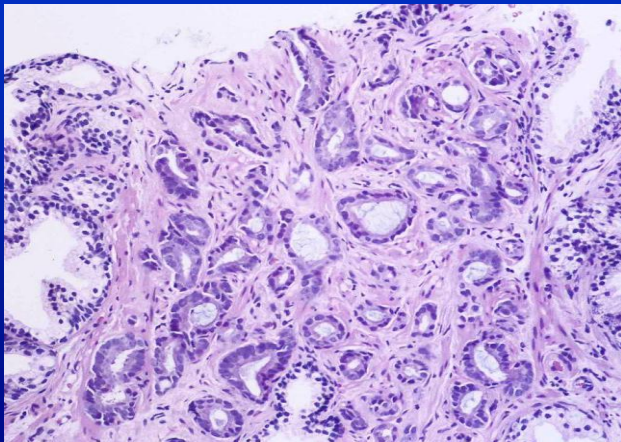
- Prostate cancer
- ✓ Cancer mimickers
- ✓ ASAP
- Intraductal cribriform lesions
- DD between prostate cancer vs. non-prostate cancer
- Prognosis/predictive markers

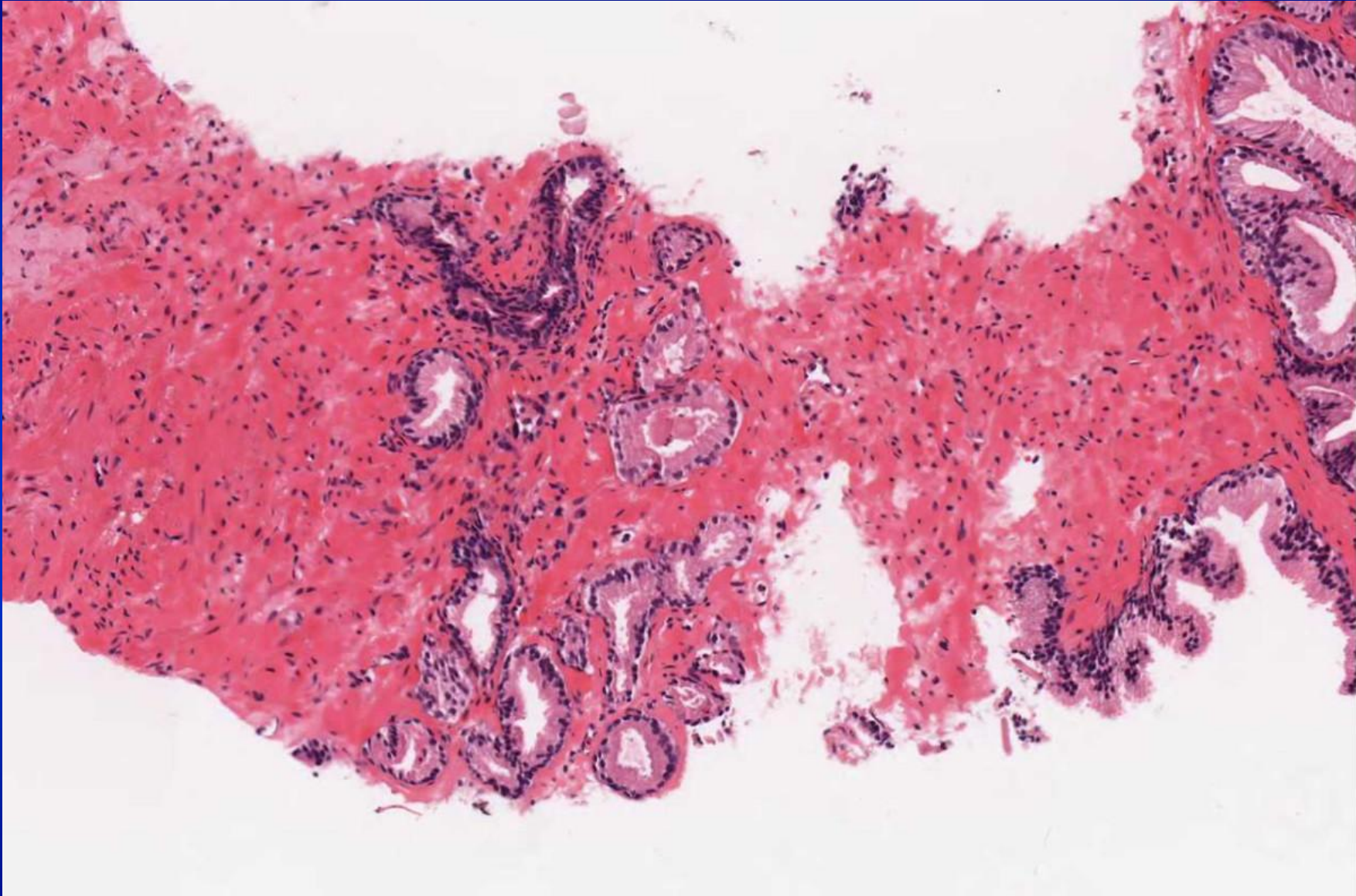


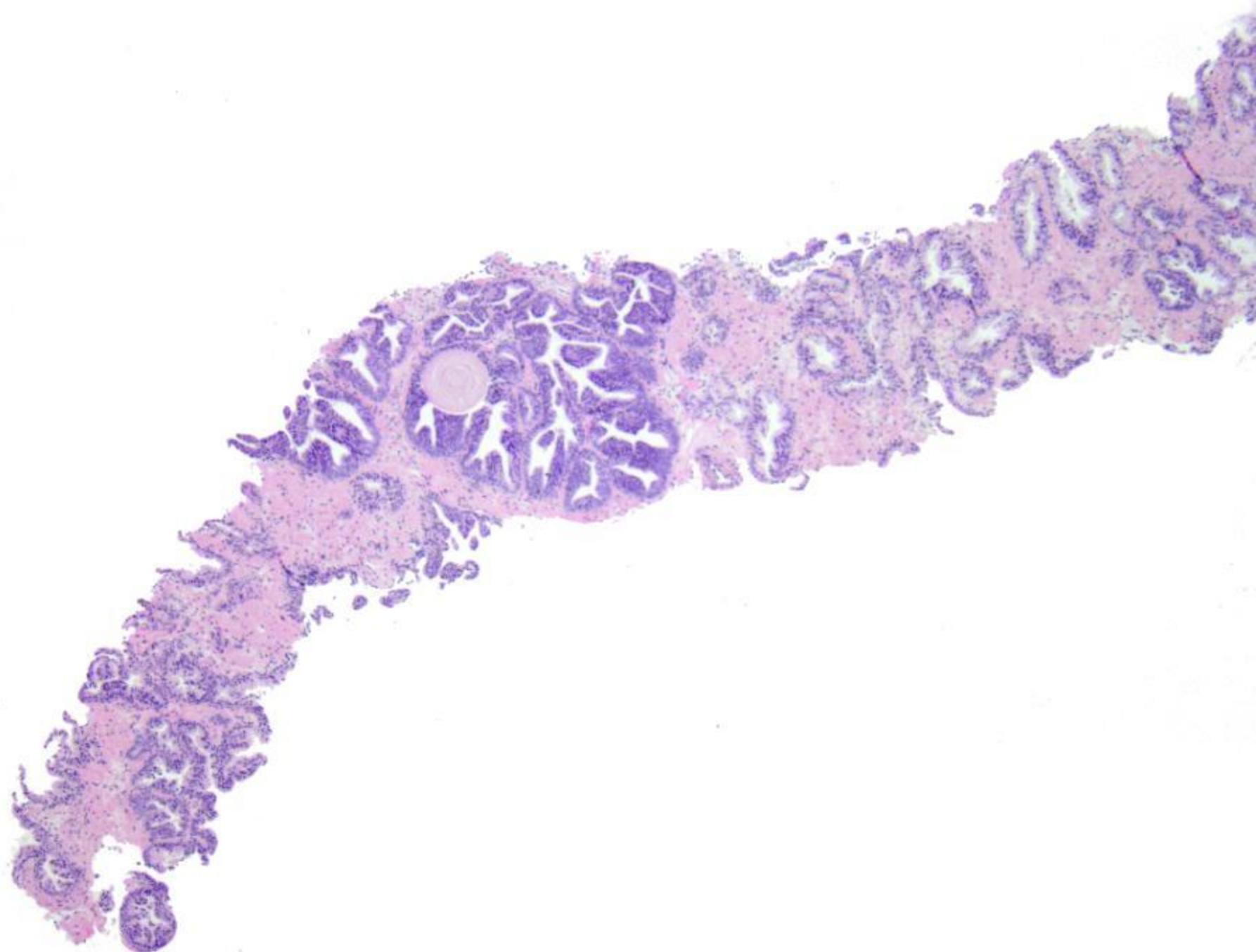
# You have to look for **3** things!

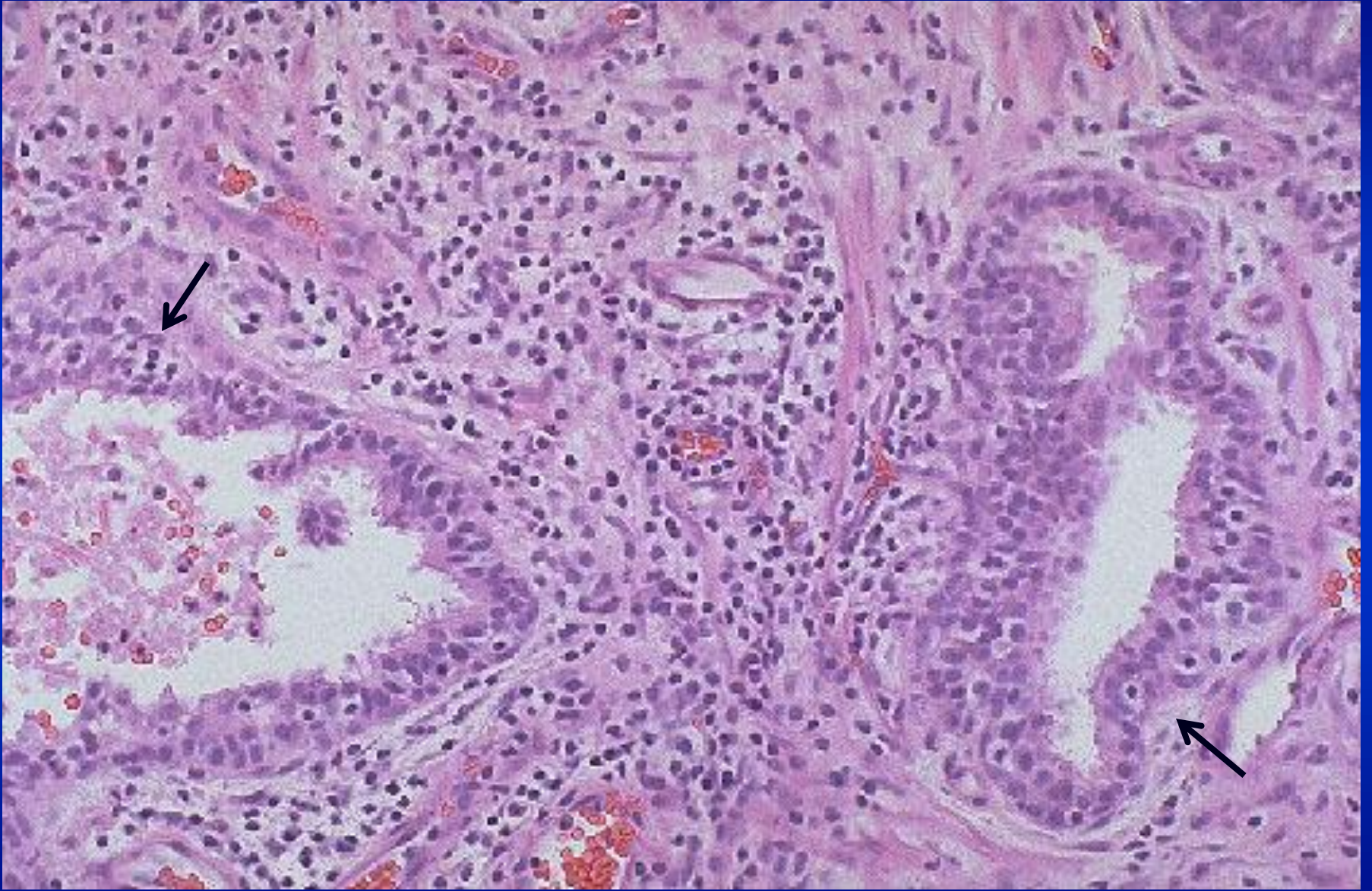
## In any specimens

- Small glands
- Medium/Large glands with atypia
- Stromal abnormalities











# Diagnostic Approach

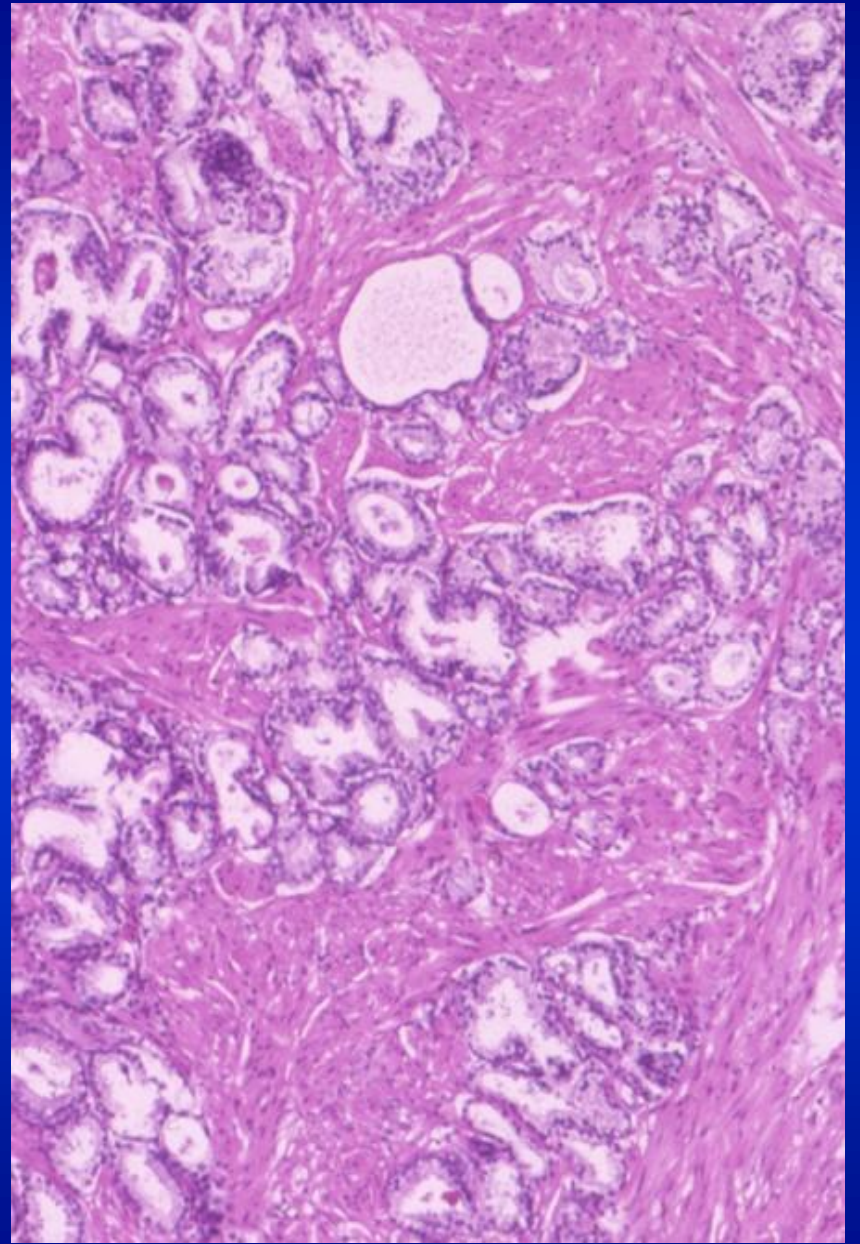
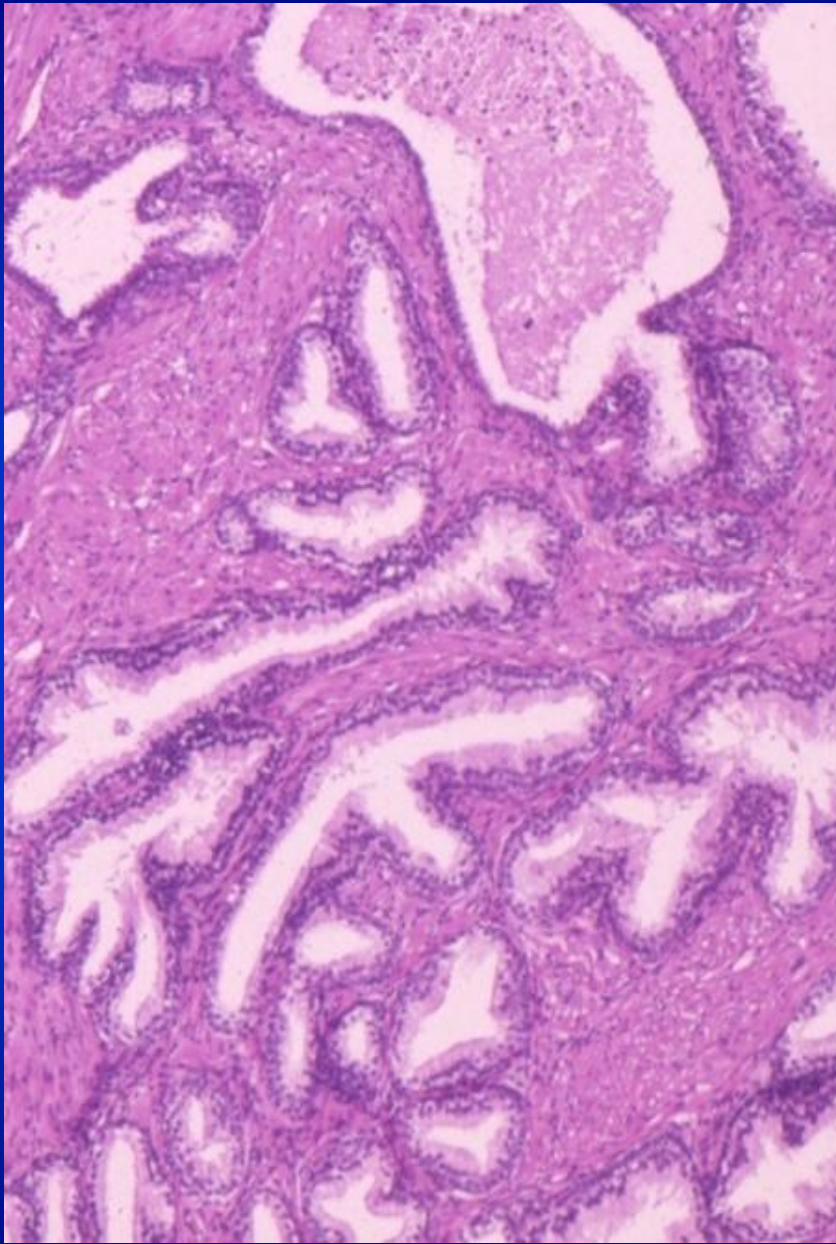


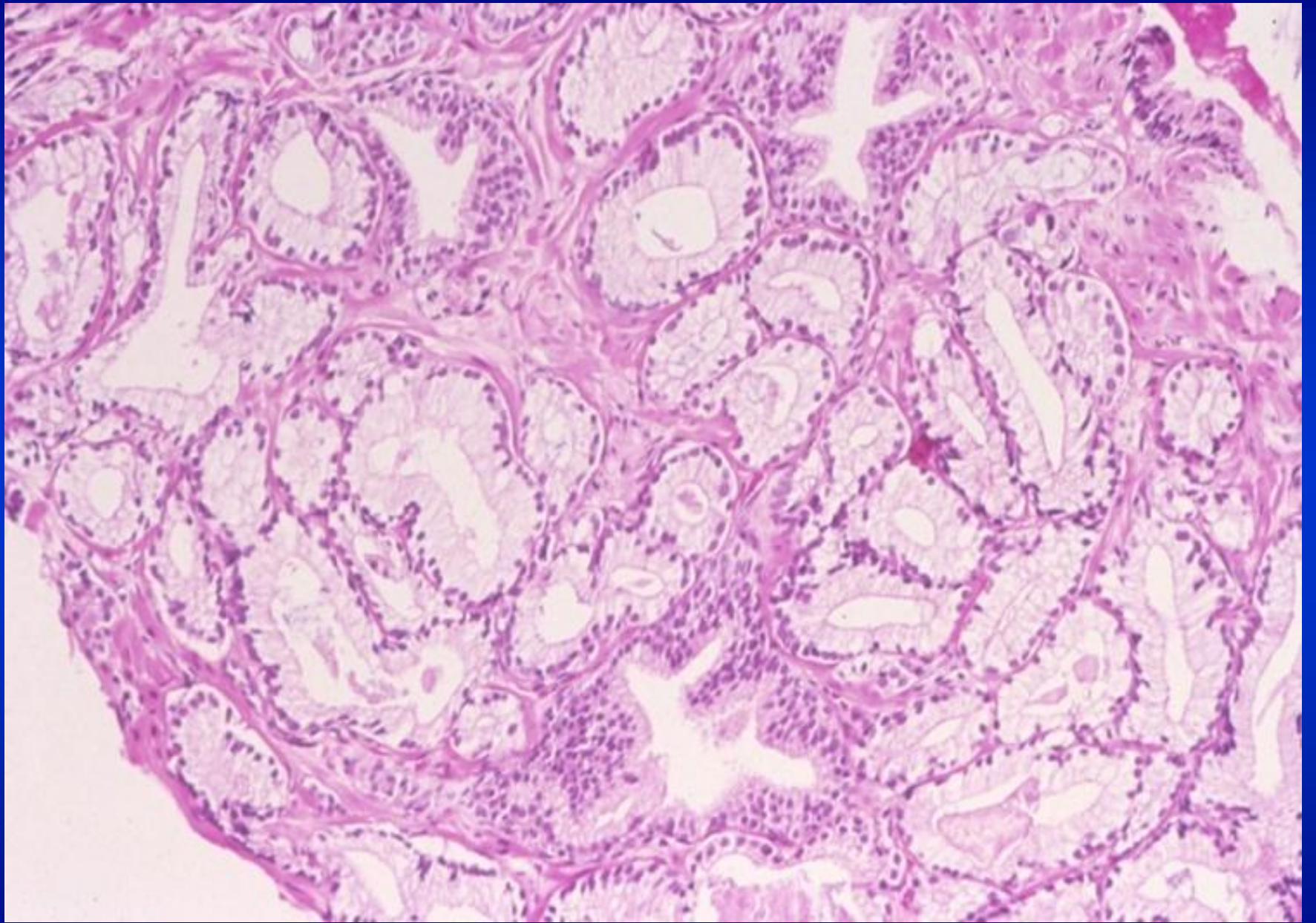


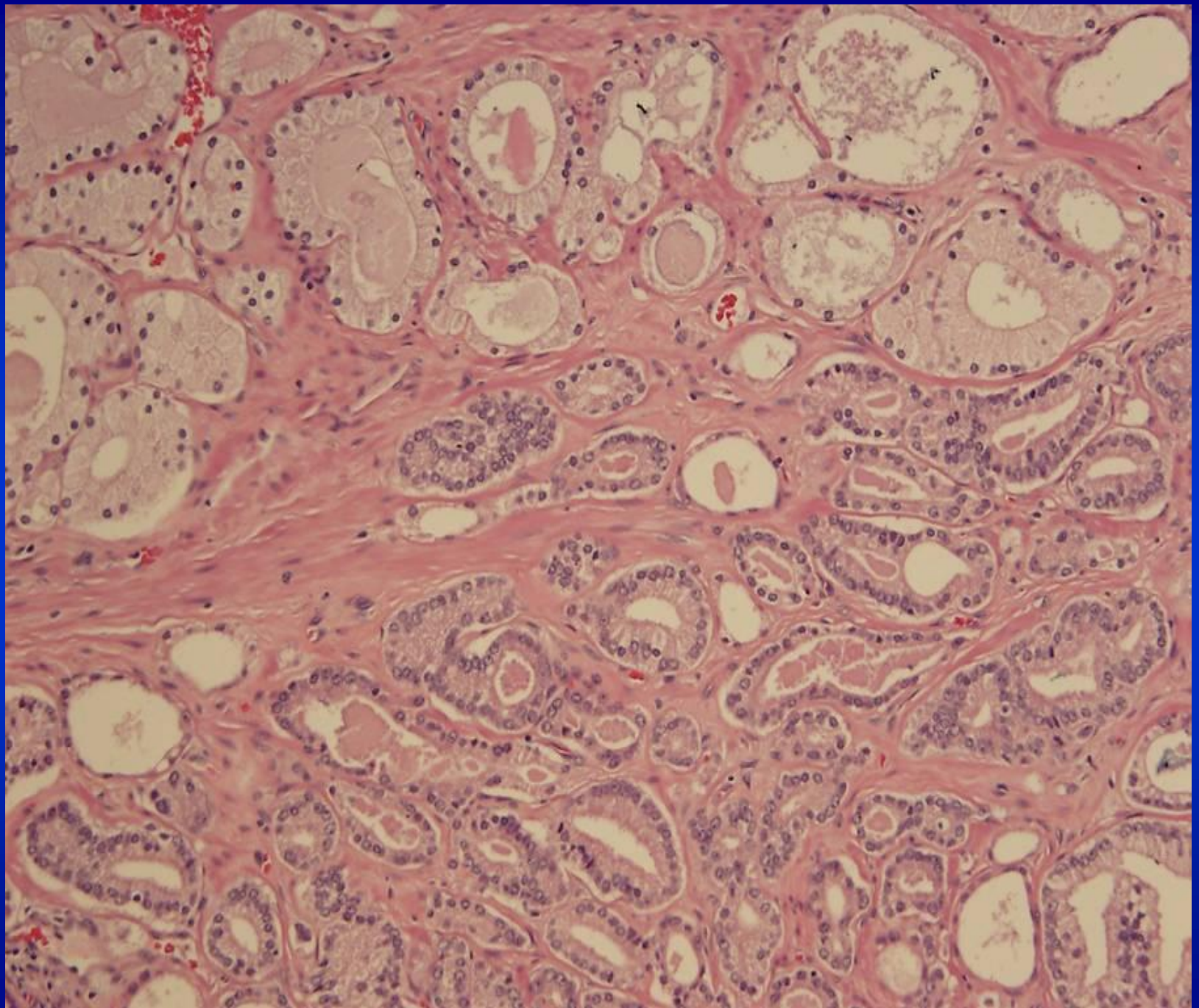
# Prostate Carcinoma

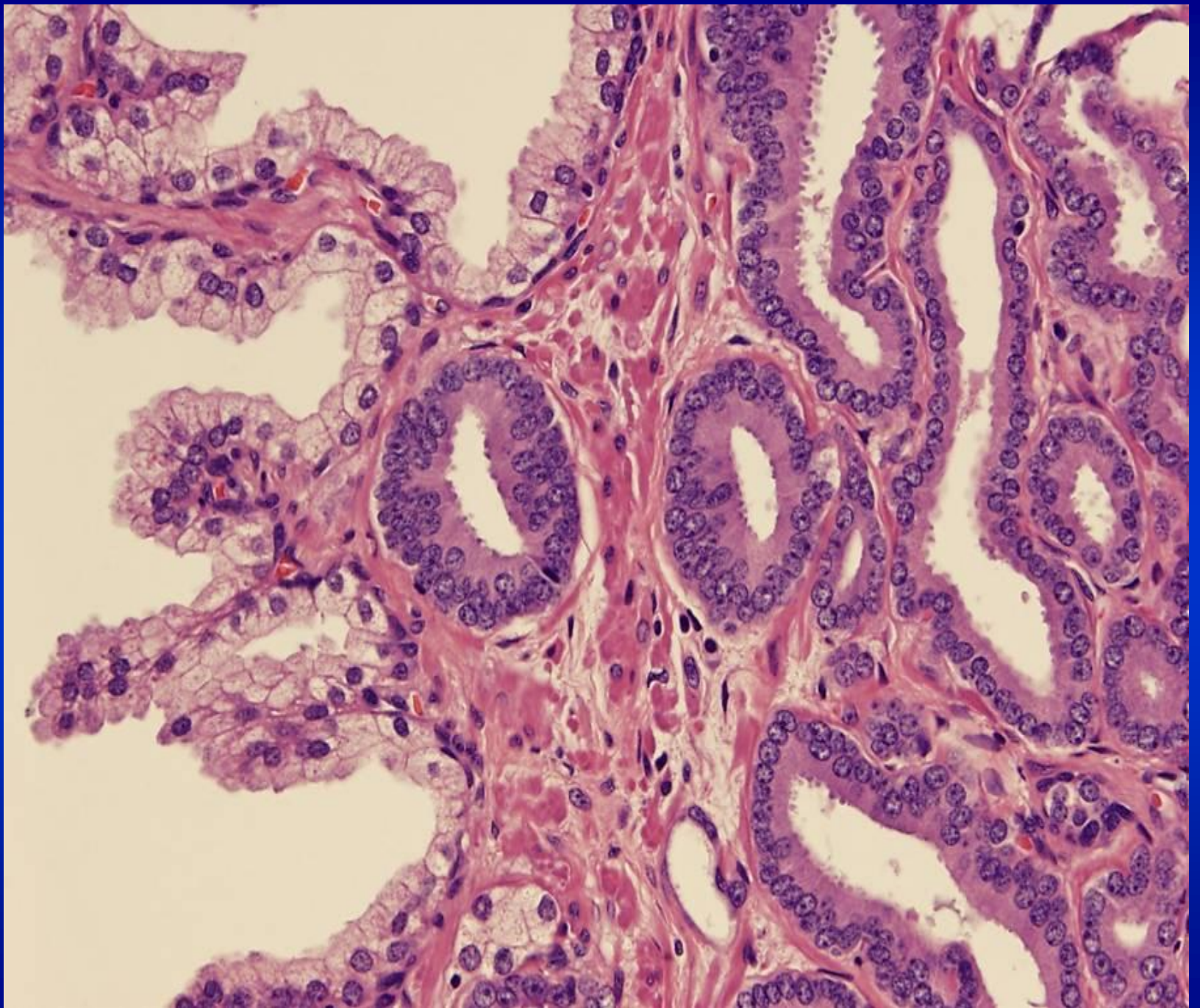
## Well-diff. and poorly diff. adenocarcinoma

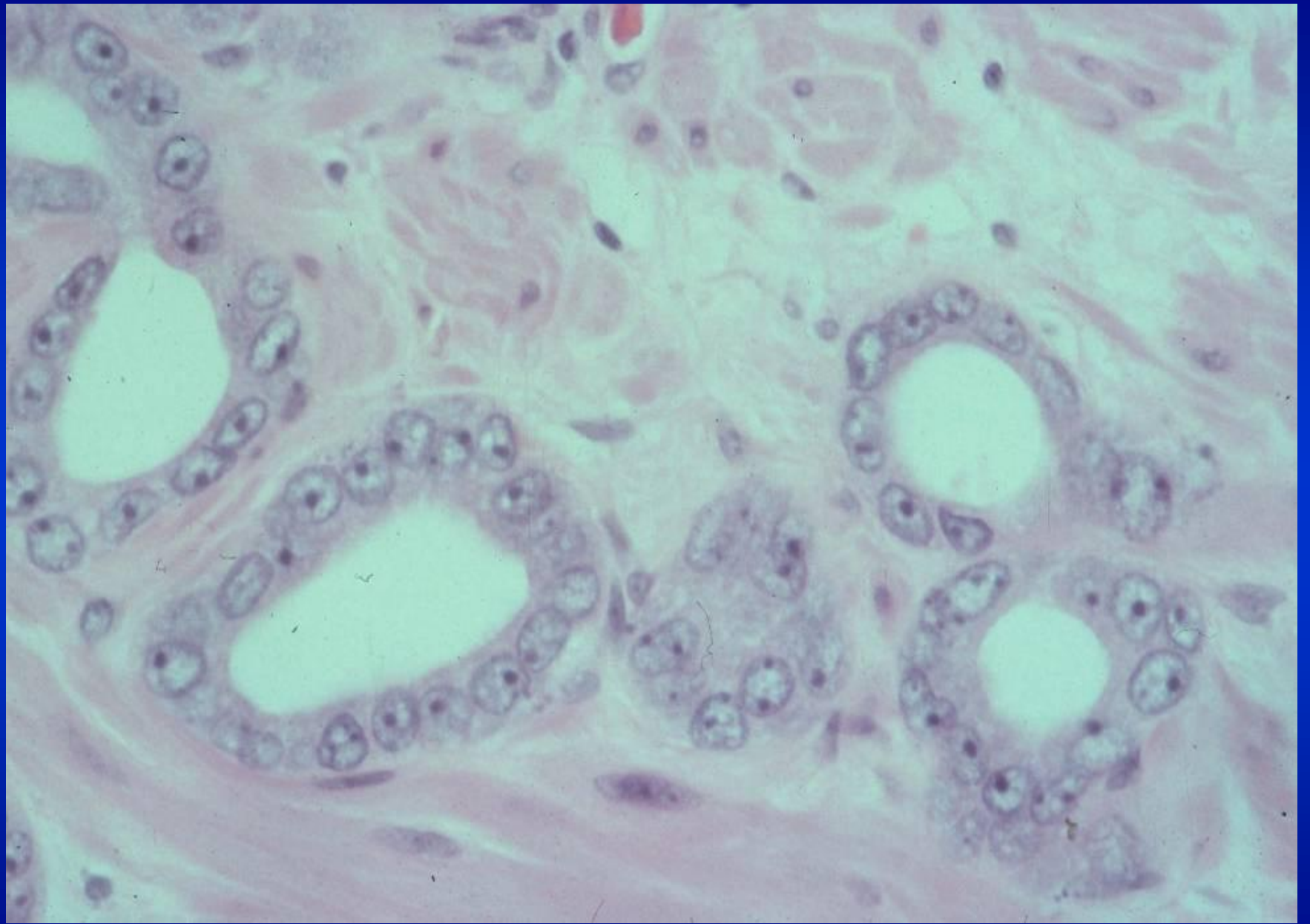
- well-diff. adenocarcinoma
  - For screening: three Too's  
(too small, too crowded, and too clear)
  - For confirmation: nuclear enlargement, prominent nucleoli and lack of basal cells
- poorly diff. adenoca
  - Uniformity, p. nucleolus, no or low mitoses

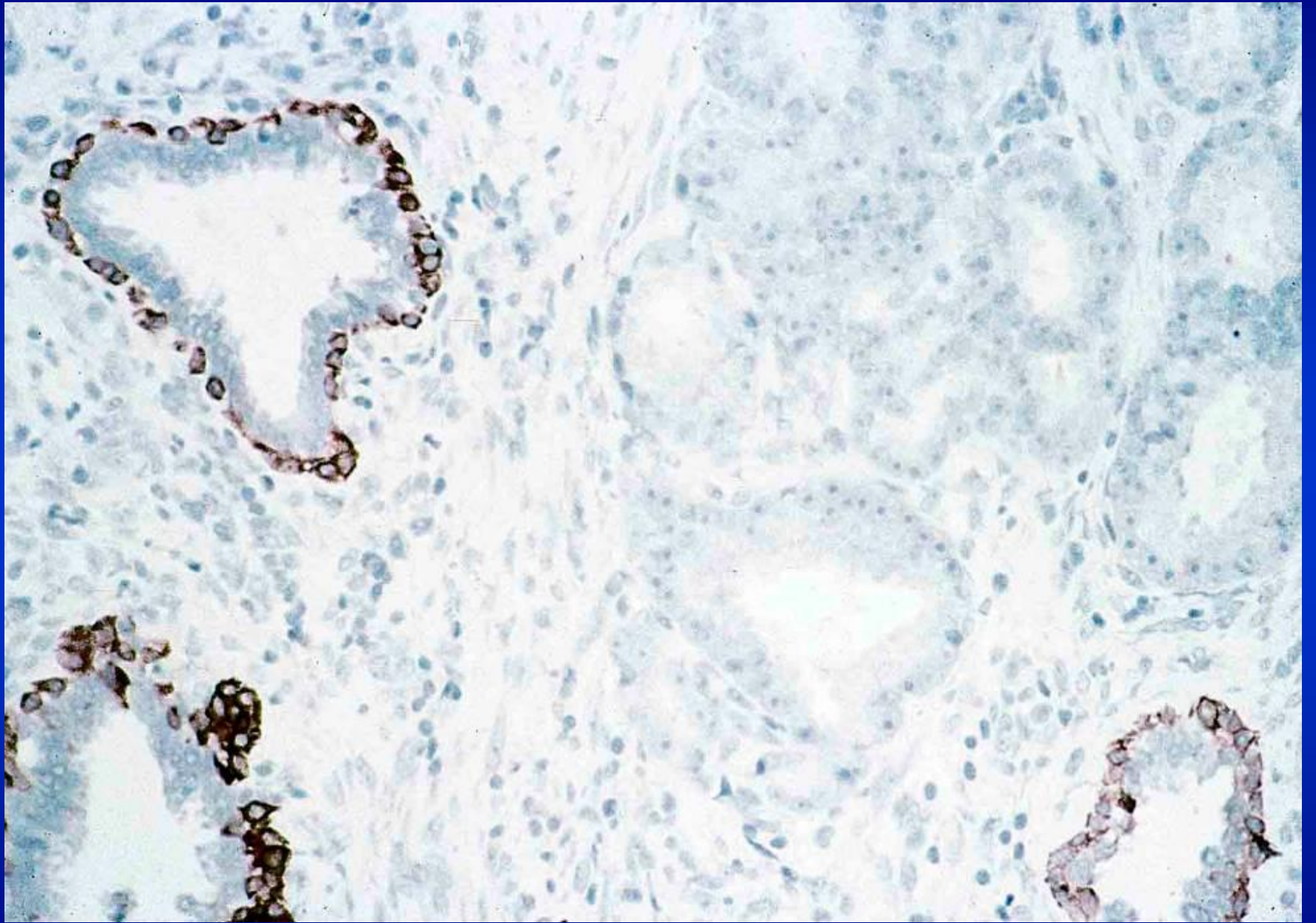


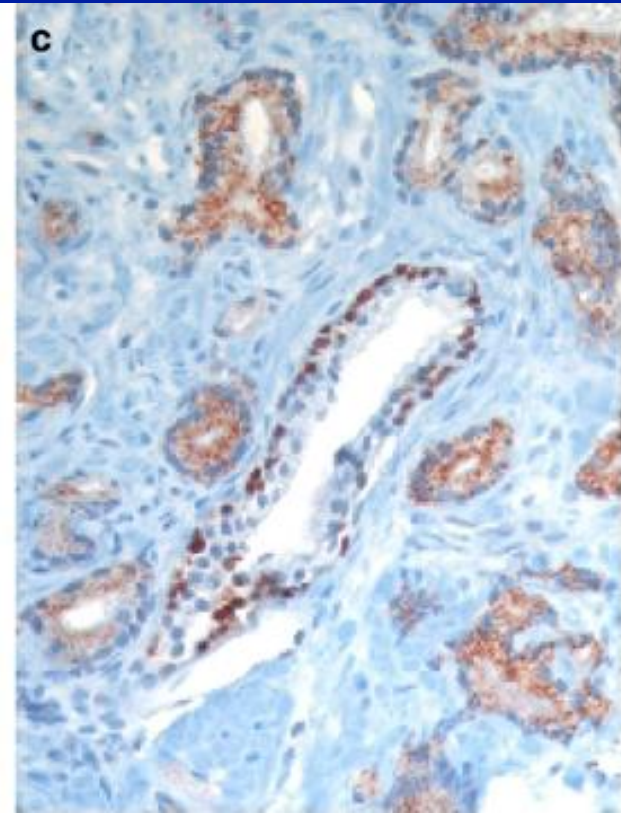
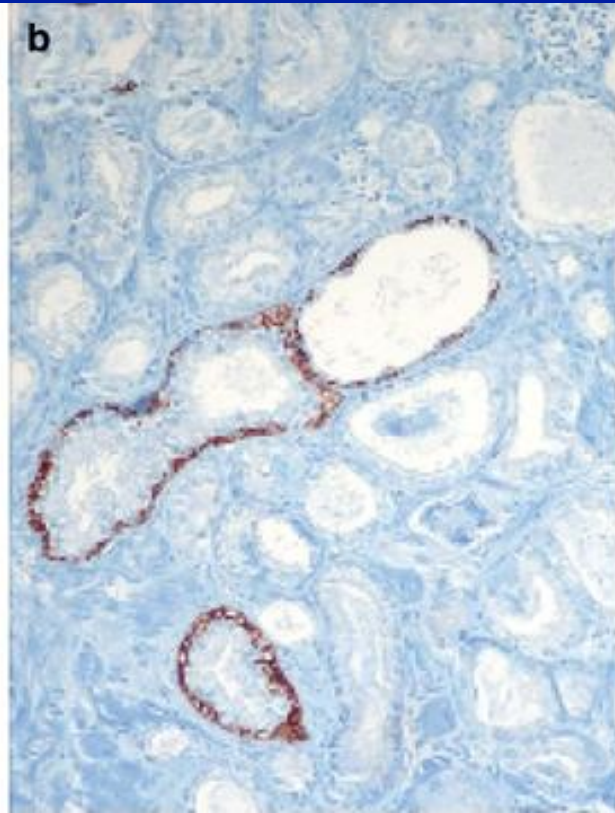
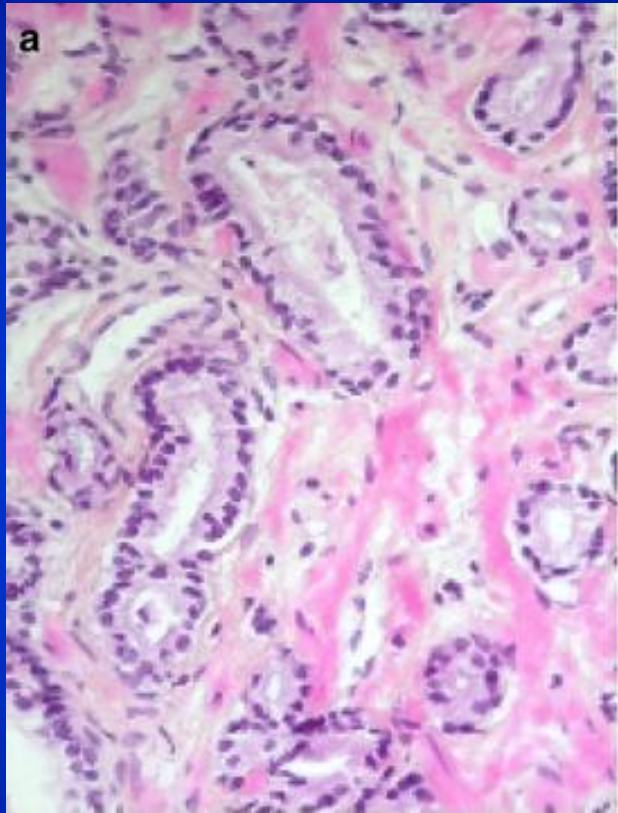


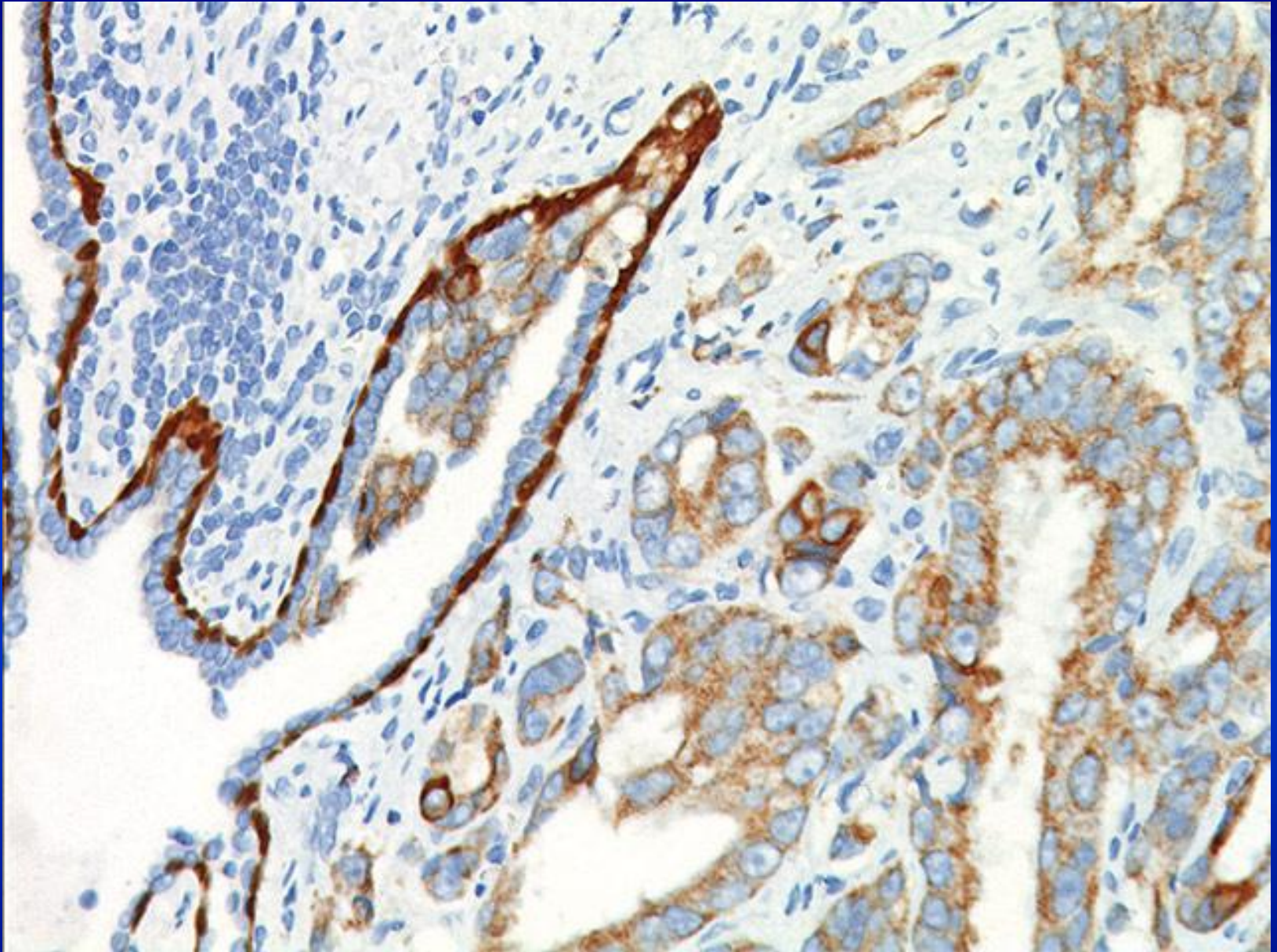




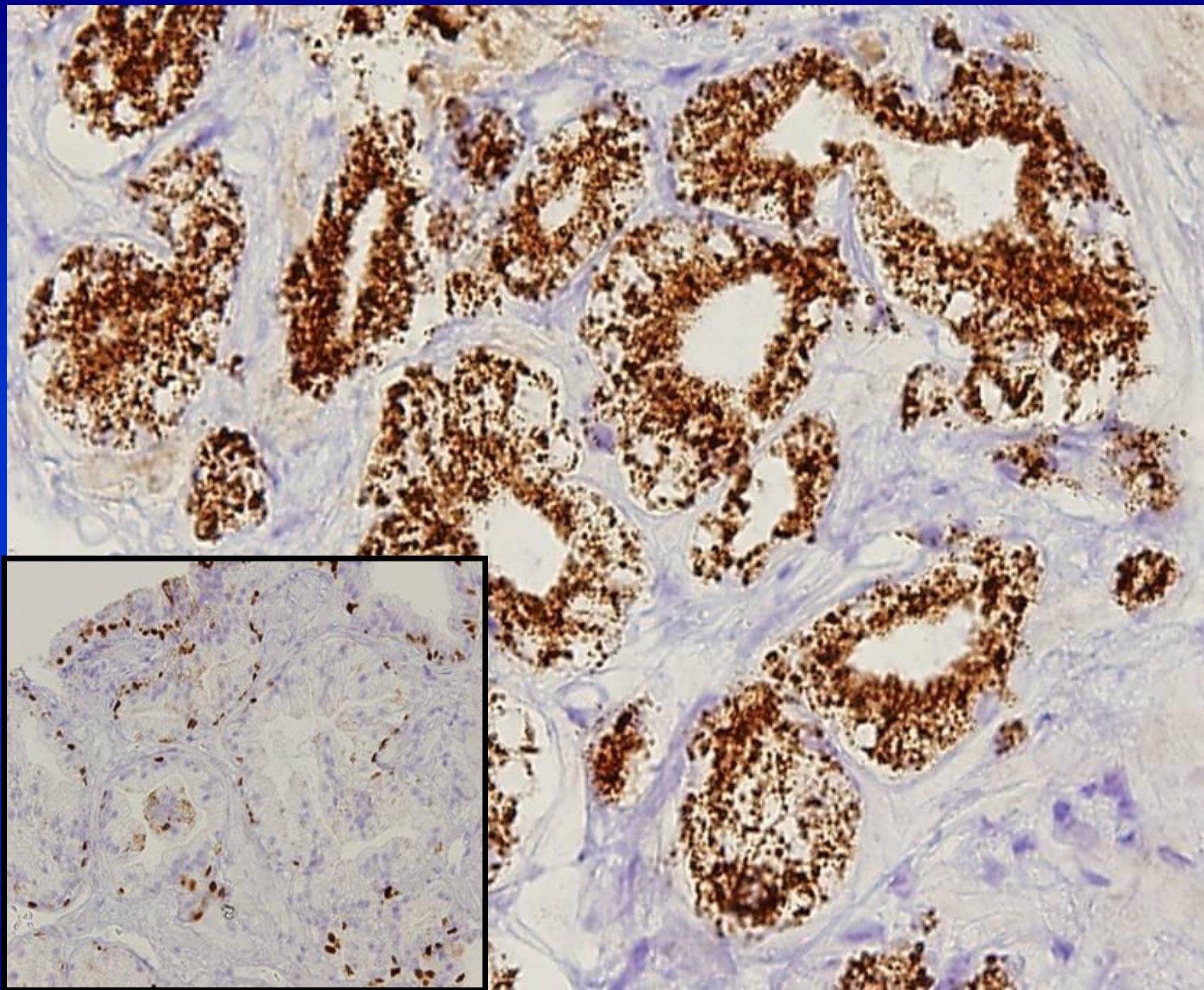


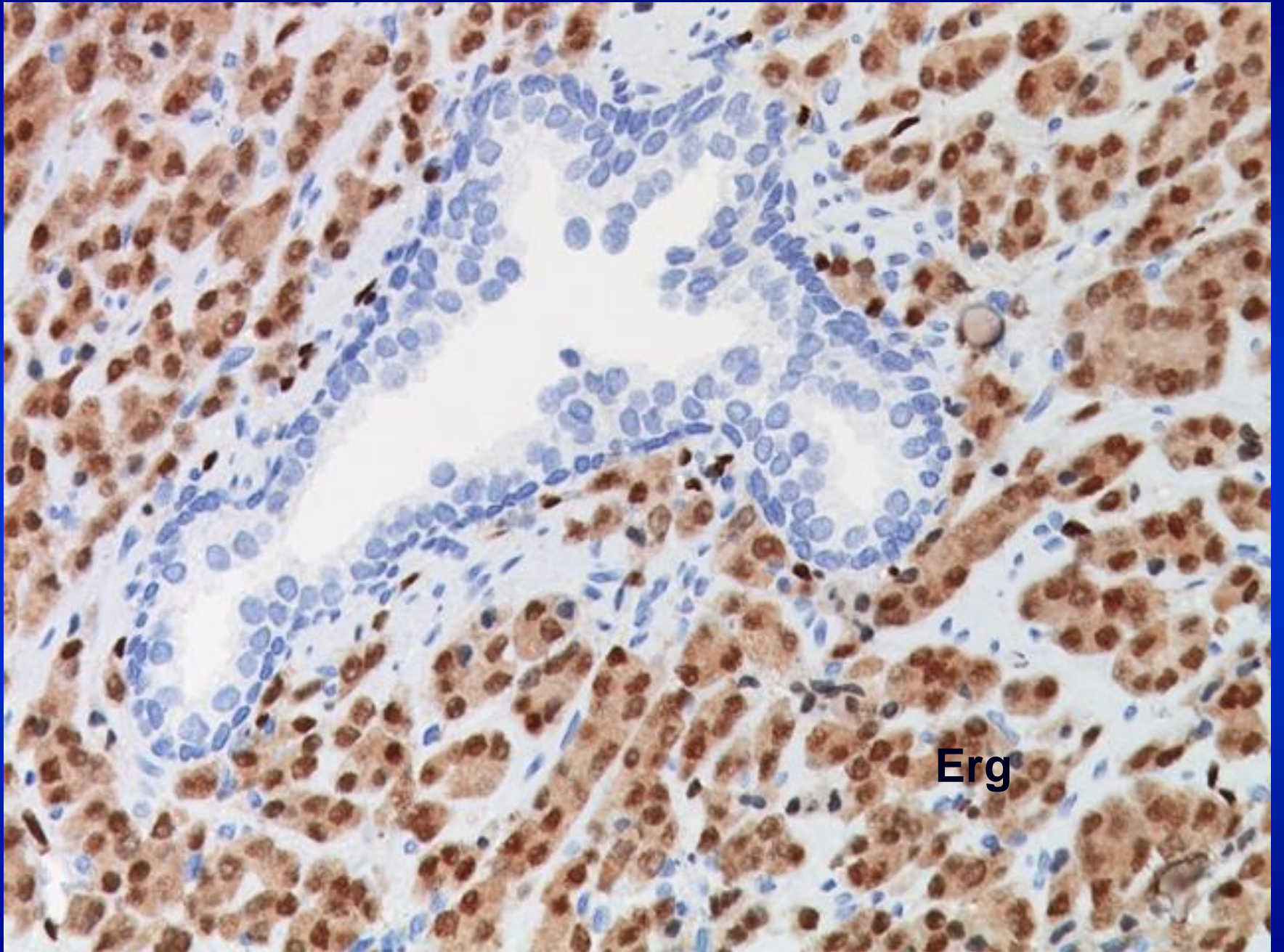




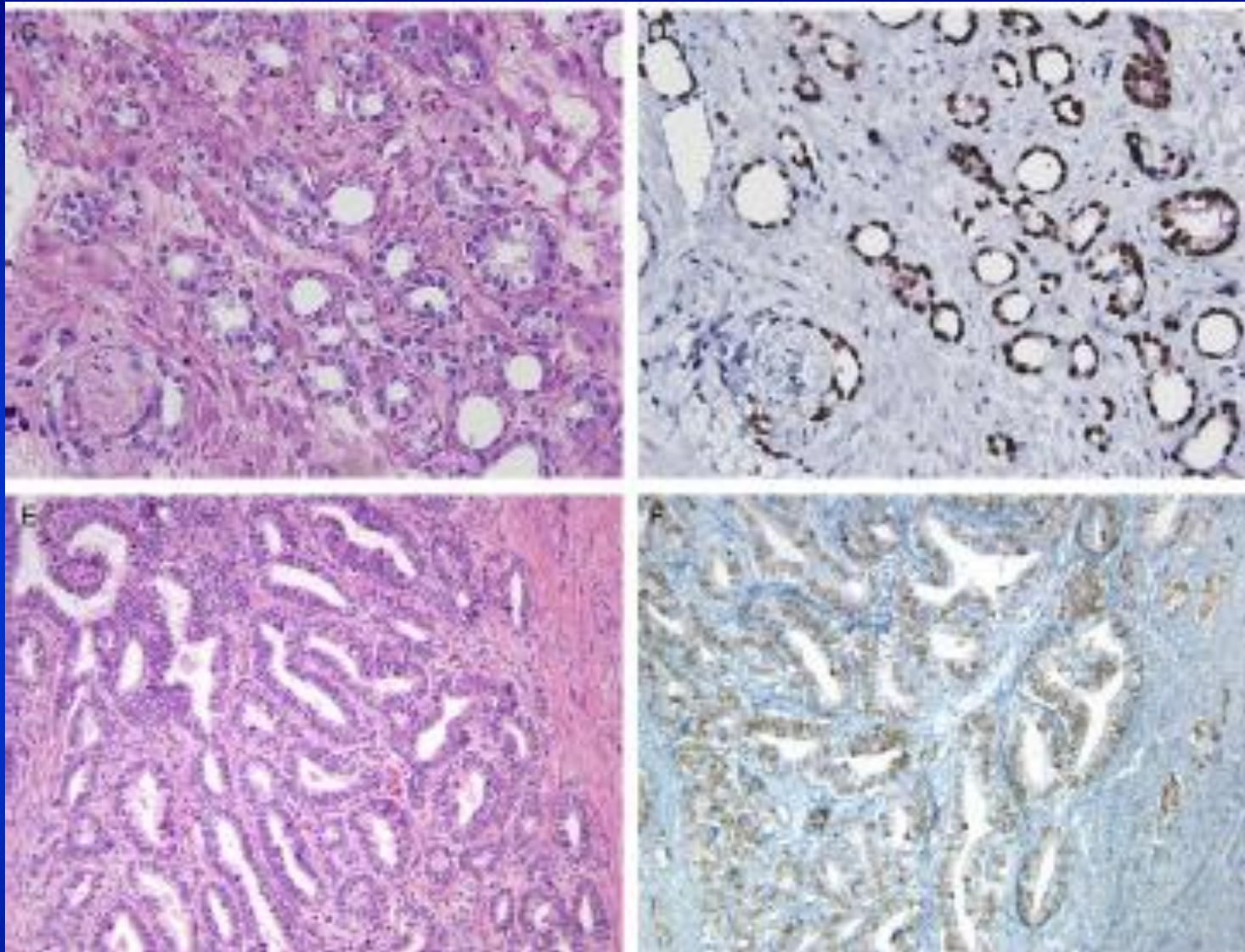


**PIN4: p63+HMCK+AMACR**





Erg



**P63 expression in prostate ca. Am J Surg Pathol 2013;37:1401–06  
However, HMWCK negative**

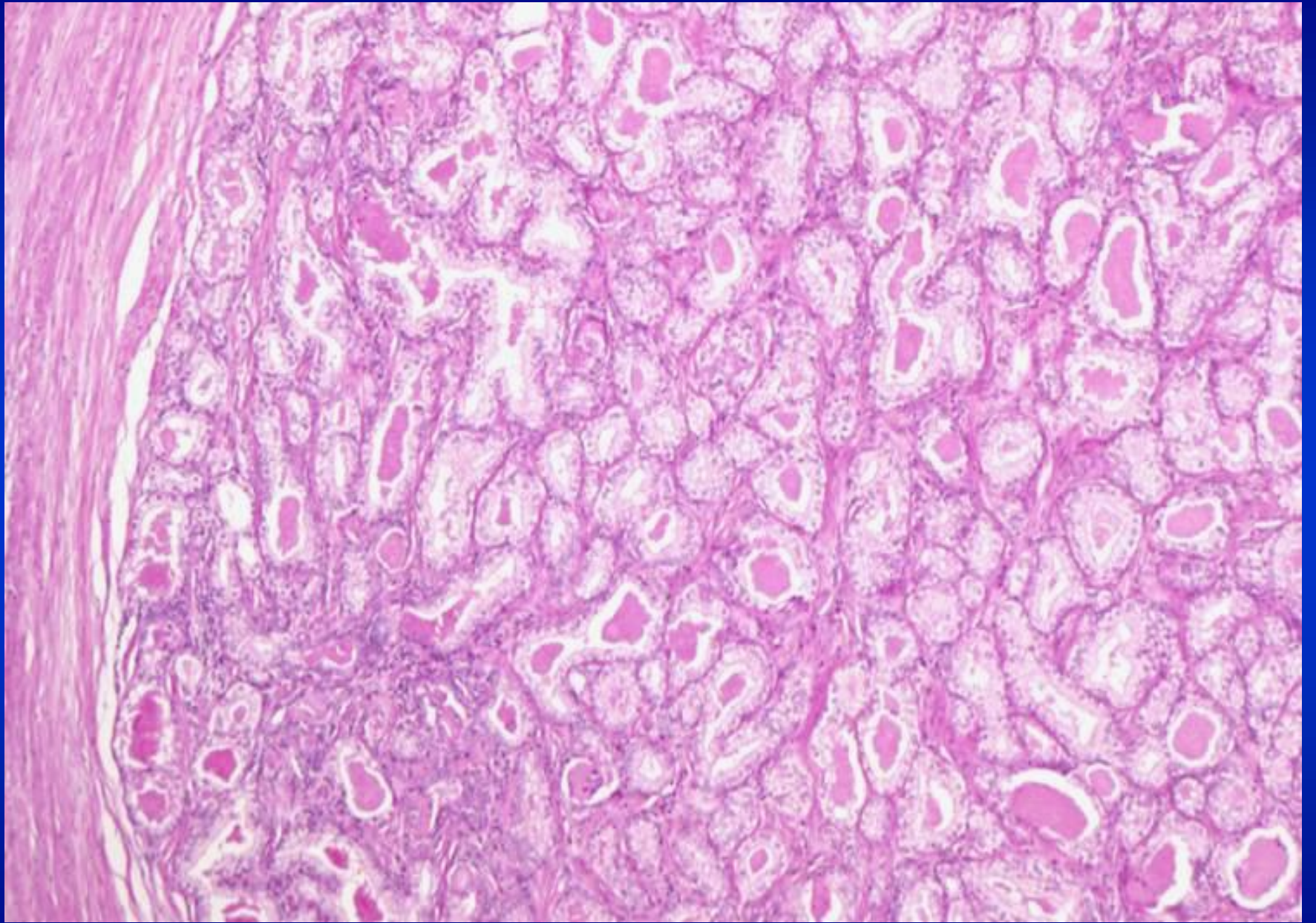


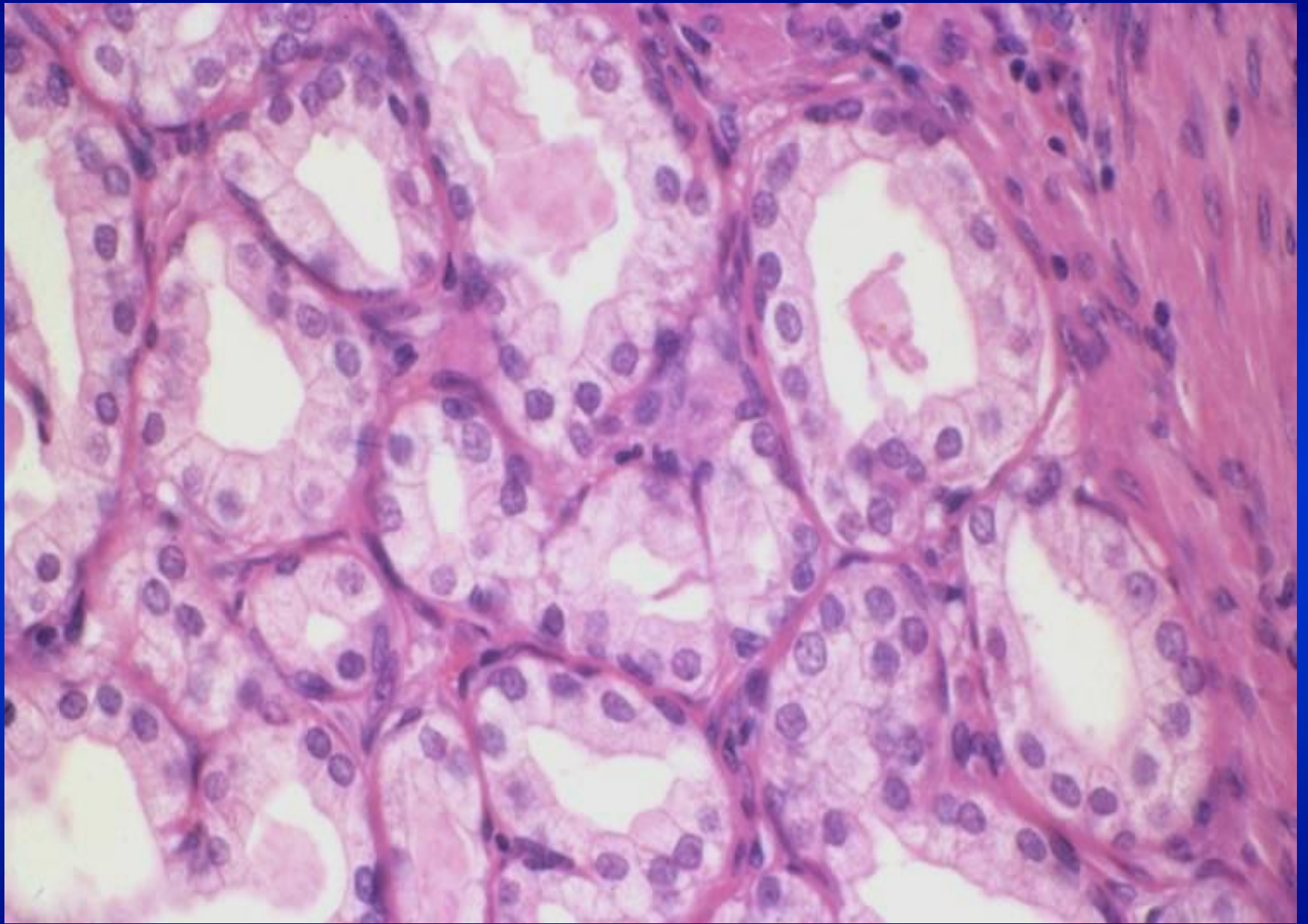
# Cancer Mimickers

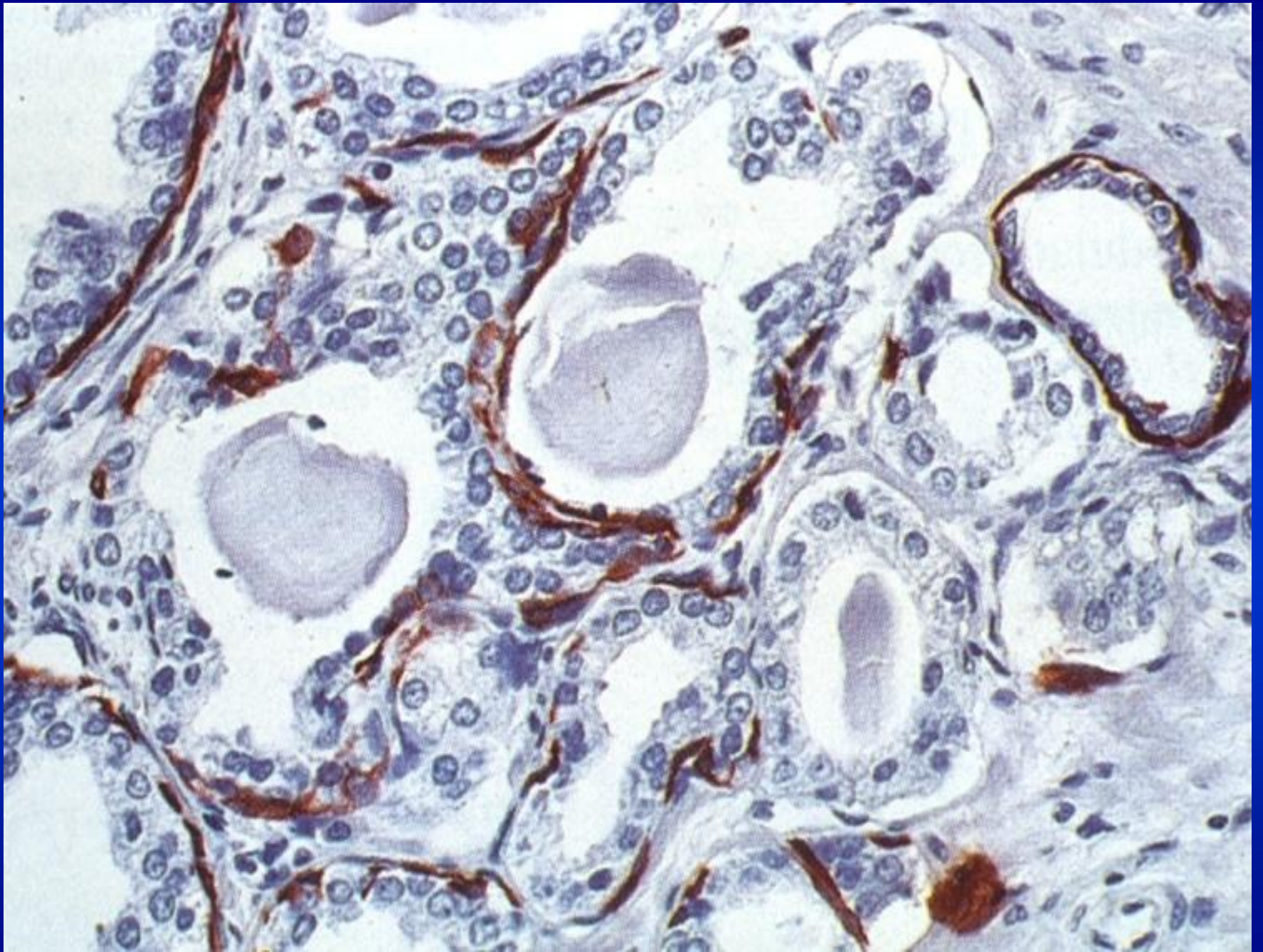
- **Small gland pattern**
- **Large and cribriform pattern**
- **Solid and non-glandular pattern**

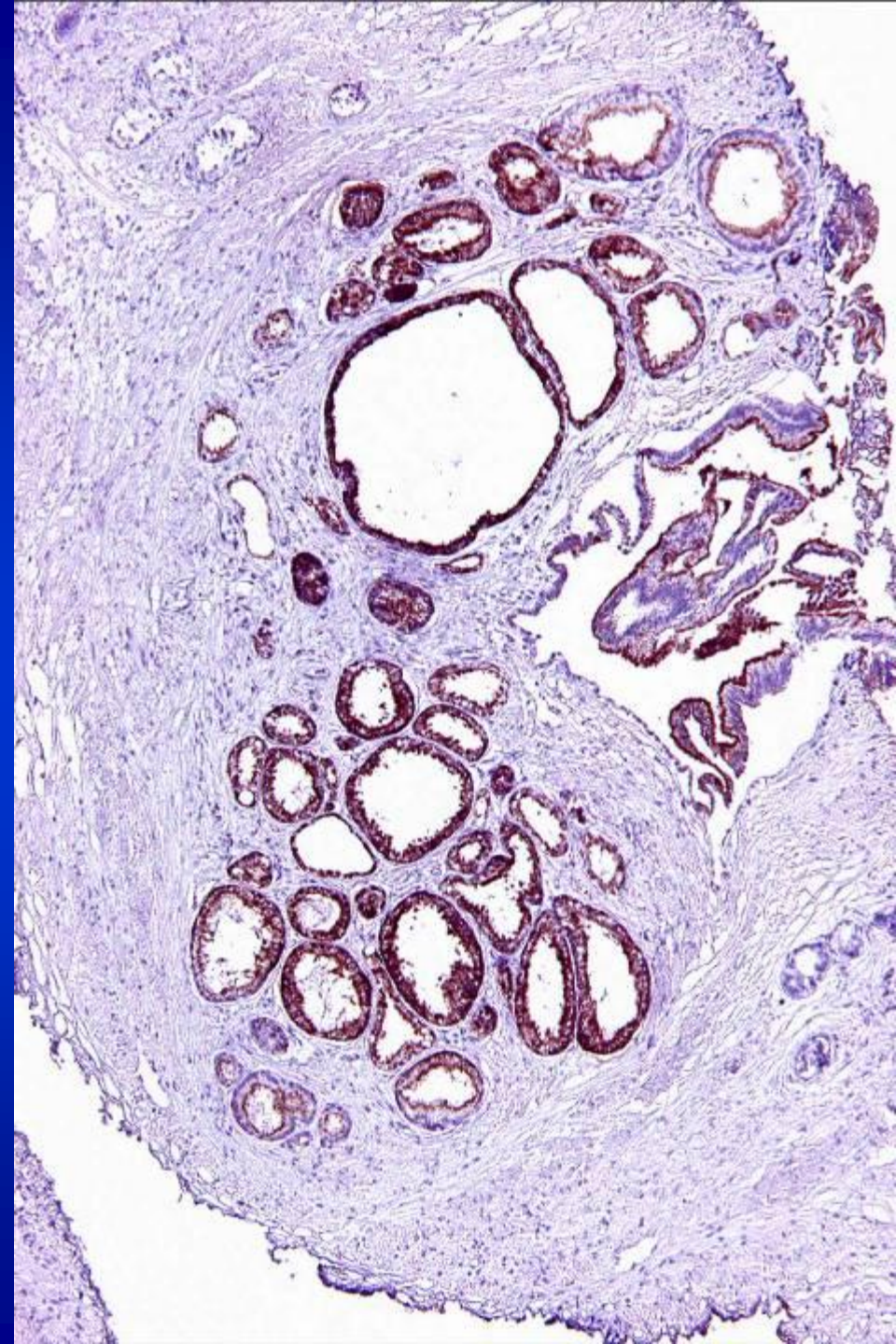
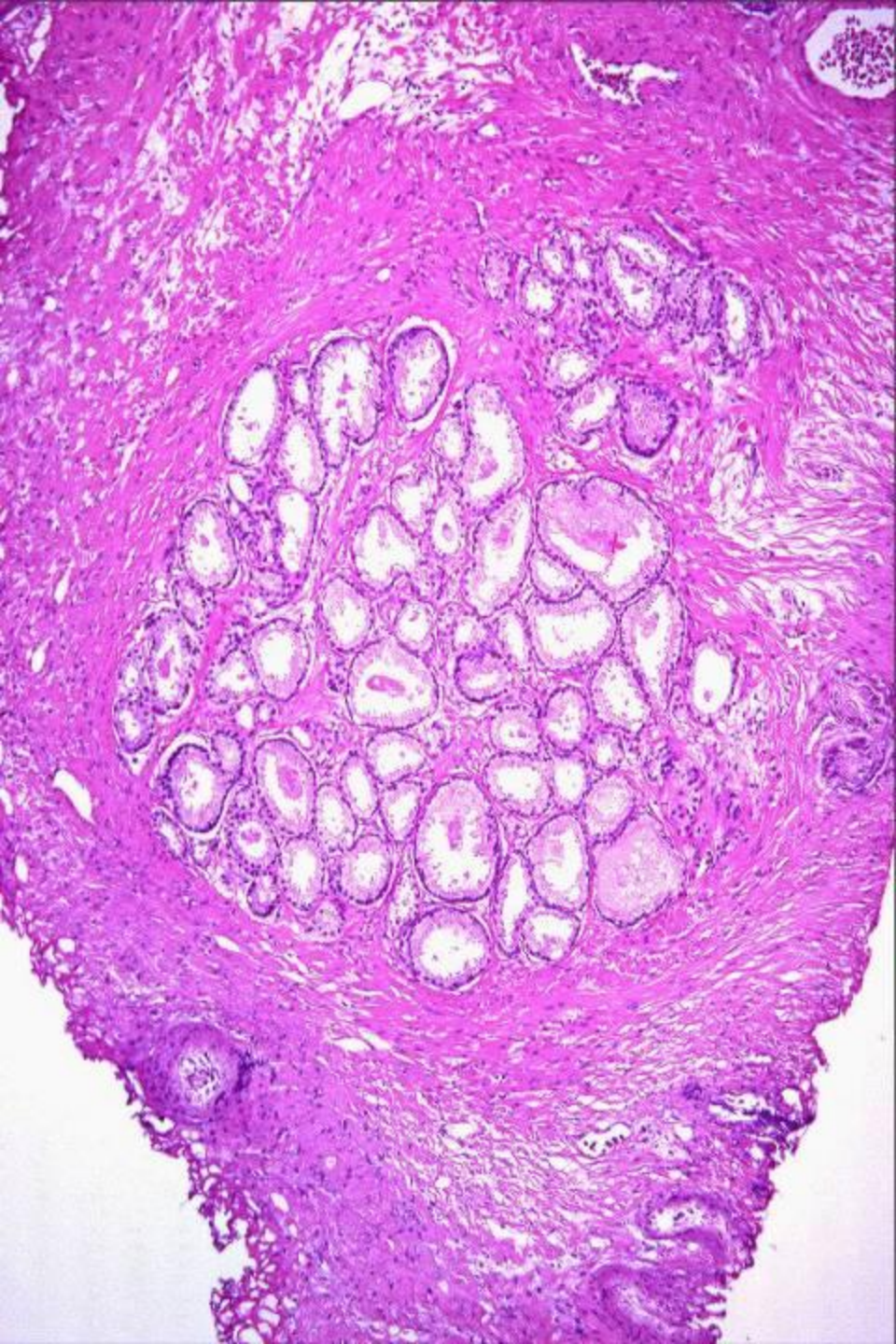
**Table 1.** The spectrum of morphology in non-neoplastic prostate including cancers mimicked

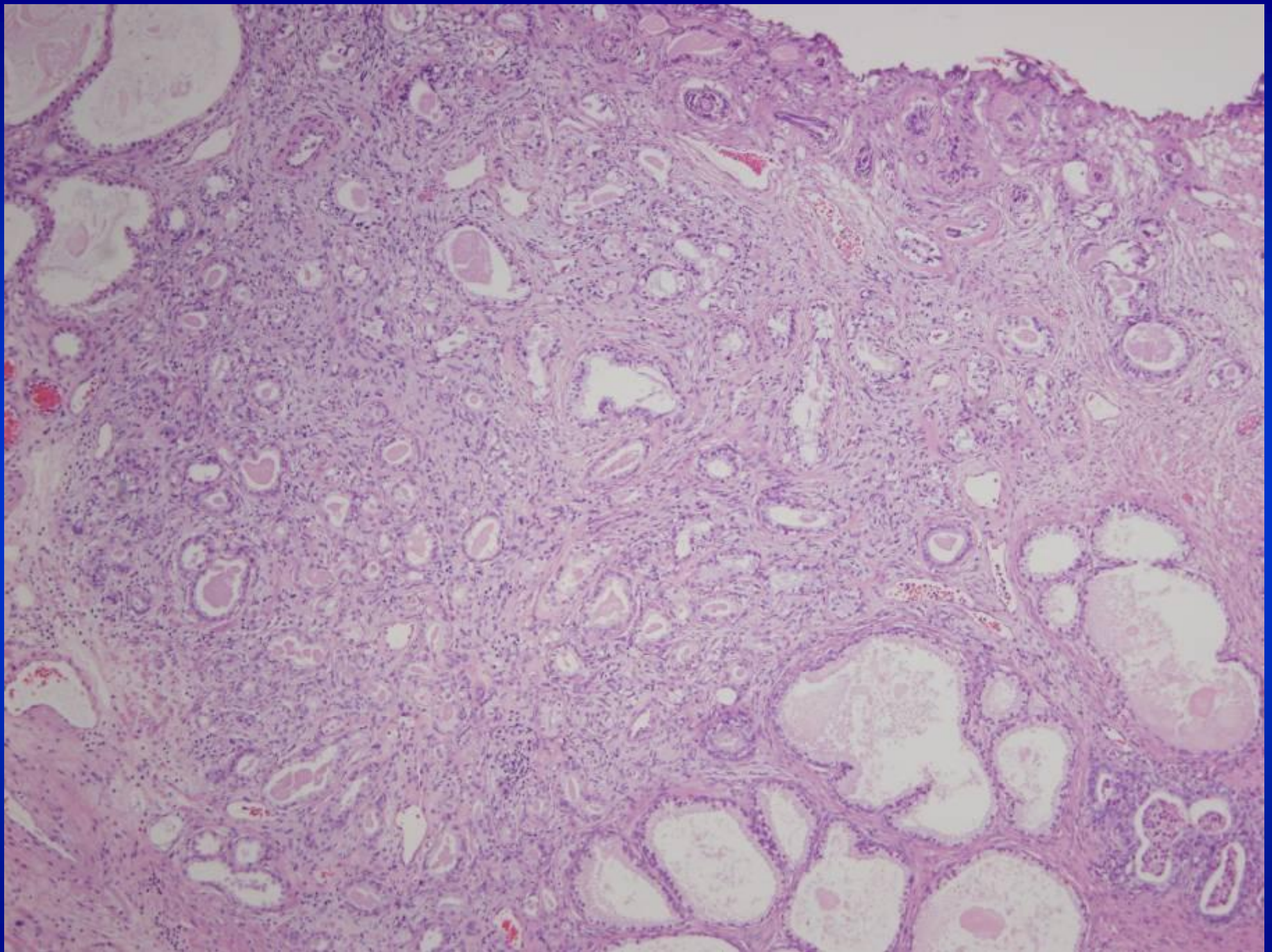
Architectural pattern	Non-neoplastic prostate lesions	Types of prostate carcinoma mimicked
Small gland pattern	Lesions of prostatic epithelial origin Atrophy, including partial atrophy Atypical adenomatous hyperplasia (adenosis) Crowded, benign glands Sclerosing adenosis Radiation atypia in benign glands Verumontanum mucosal gland hyperplasia Basal cell hyperplasia Lesions of non-prostatic epithelial origin Ejaculatory duct epithelium and seminal vesicle Mesonephric remnants Nephrogenic adenoma Mucinous metaplasia Cowper (bulbourethral) glands Colonic glands	Gleason pattern $\leq 3$ Atrophic PCa
Large and cribriform gland patterns	Basal cell hyperplasia Clear cell cribriform hyperplasia Medium- to large-sized hyperplastic glands Reactive epithelial atypia	Cribriform Gleason patterns 3, 4 and 5 Ductal adenocarcinoma Pseudohyperplastic
Solid and non-glandular patterns	Non-specific granulomatous prostatitis, dense inflammation and malakoplakia Signet ring-like change in non-epithelial cells Prostatic xanthoma Paraganglia	Gleason patterns 4 and 5 Foamy gland PCa Post-treatment carcinoma

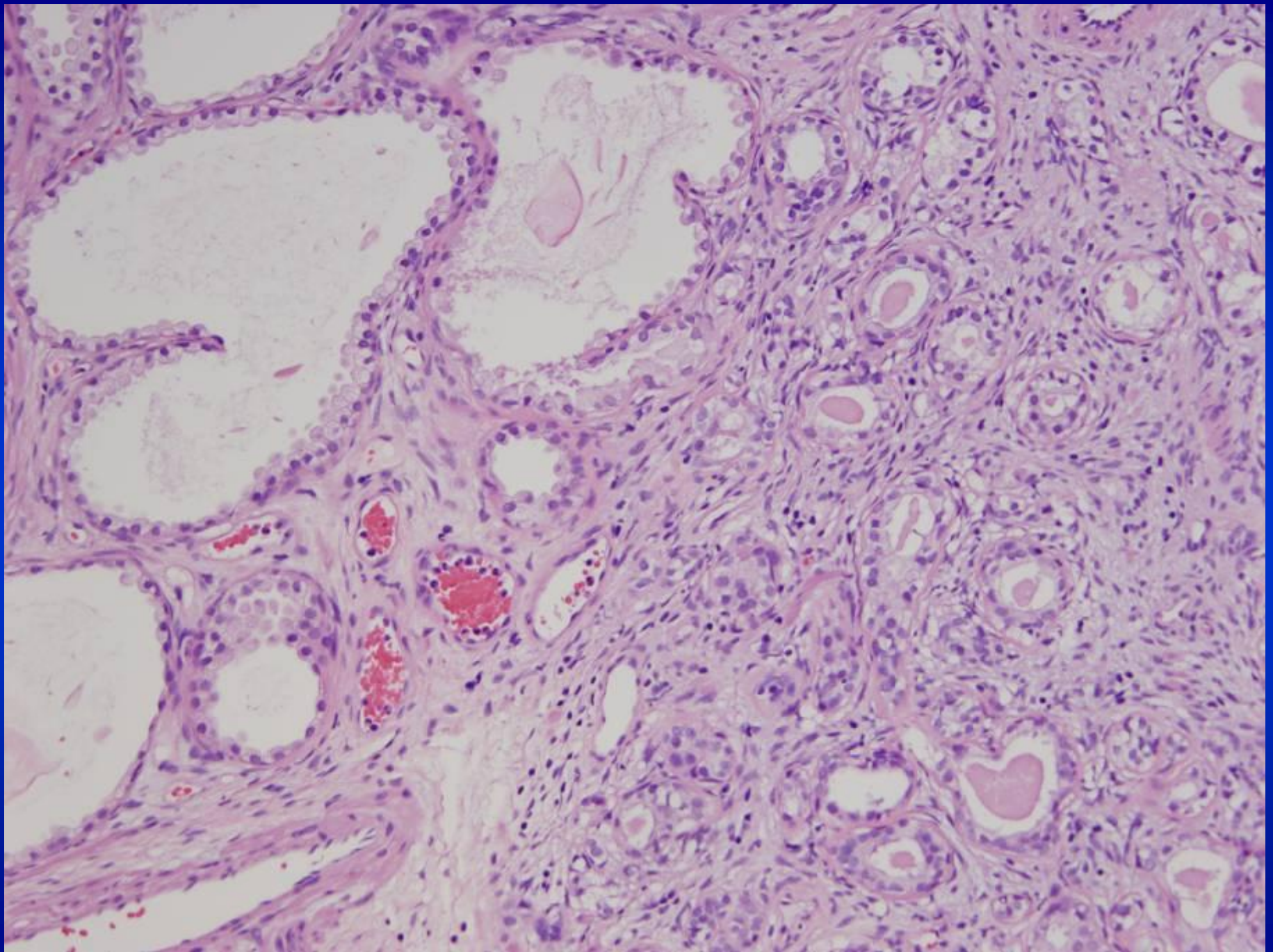


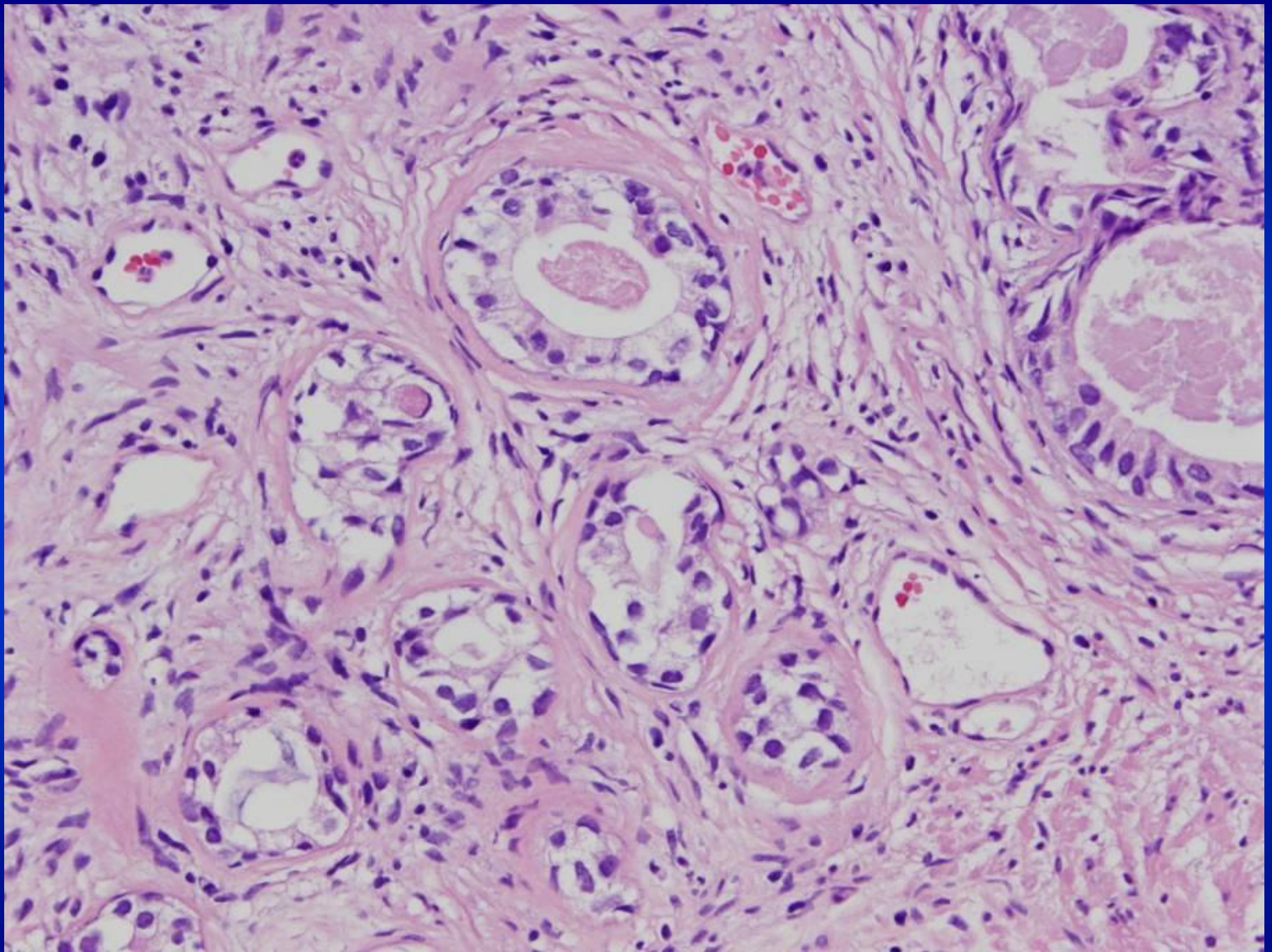


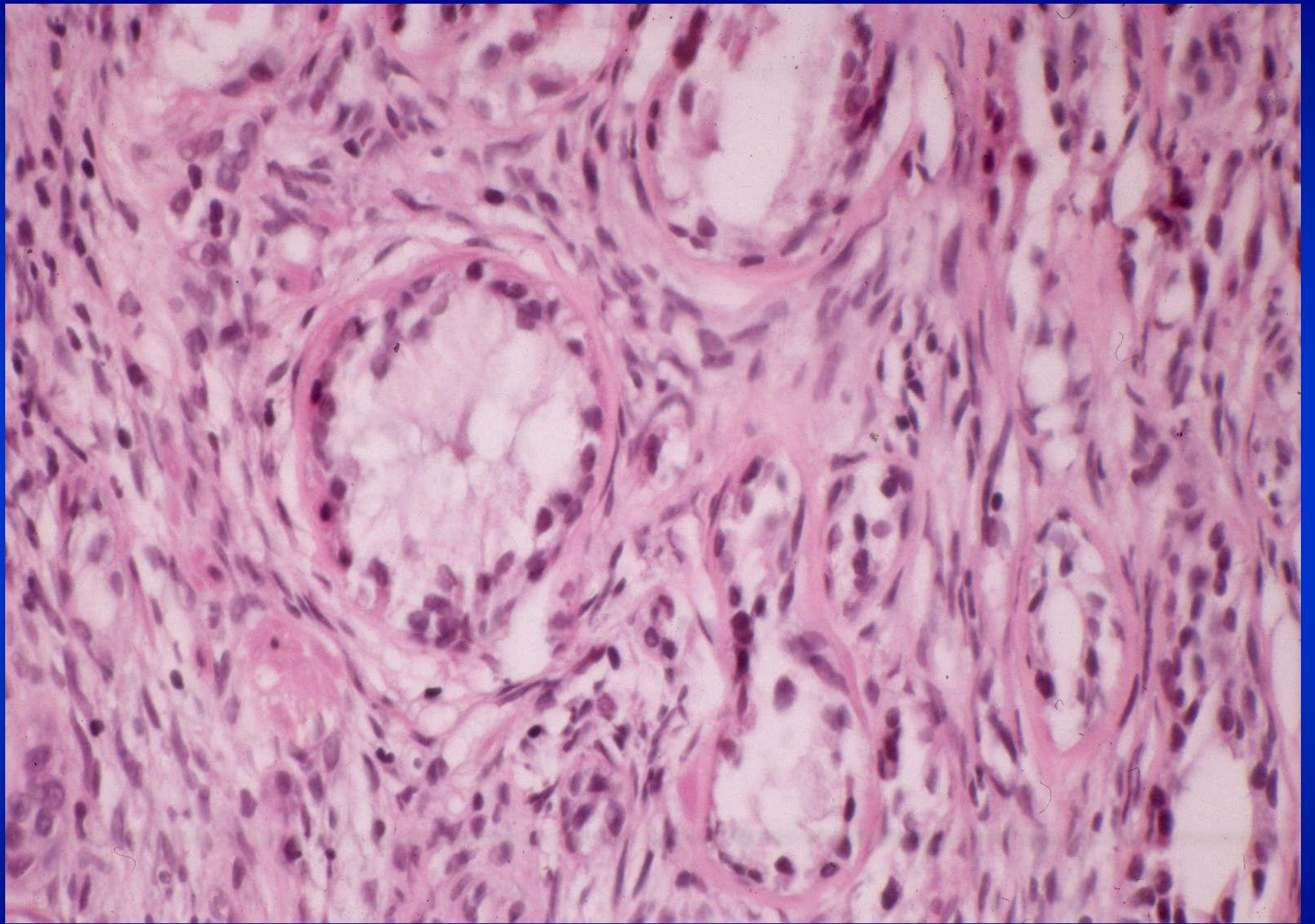


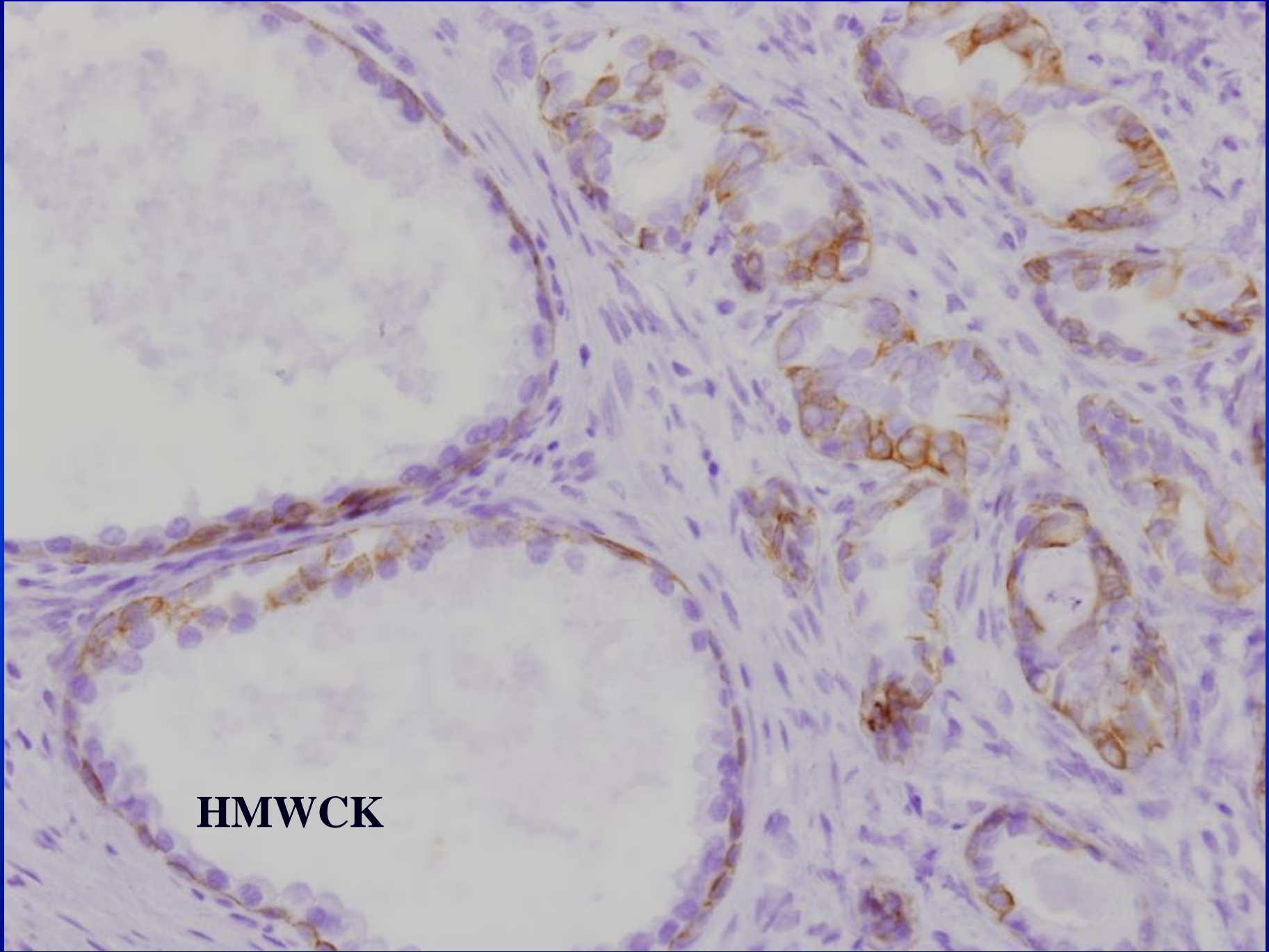




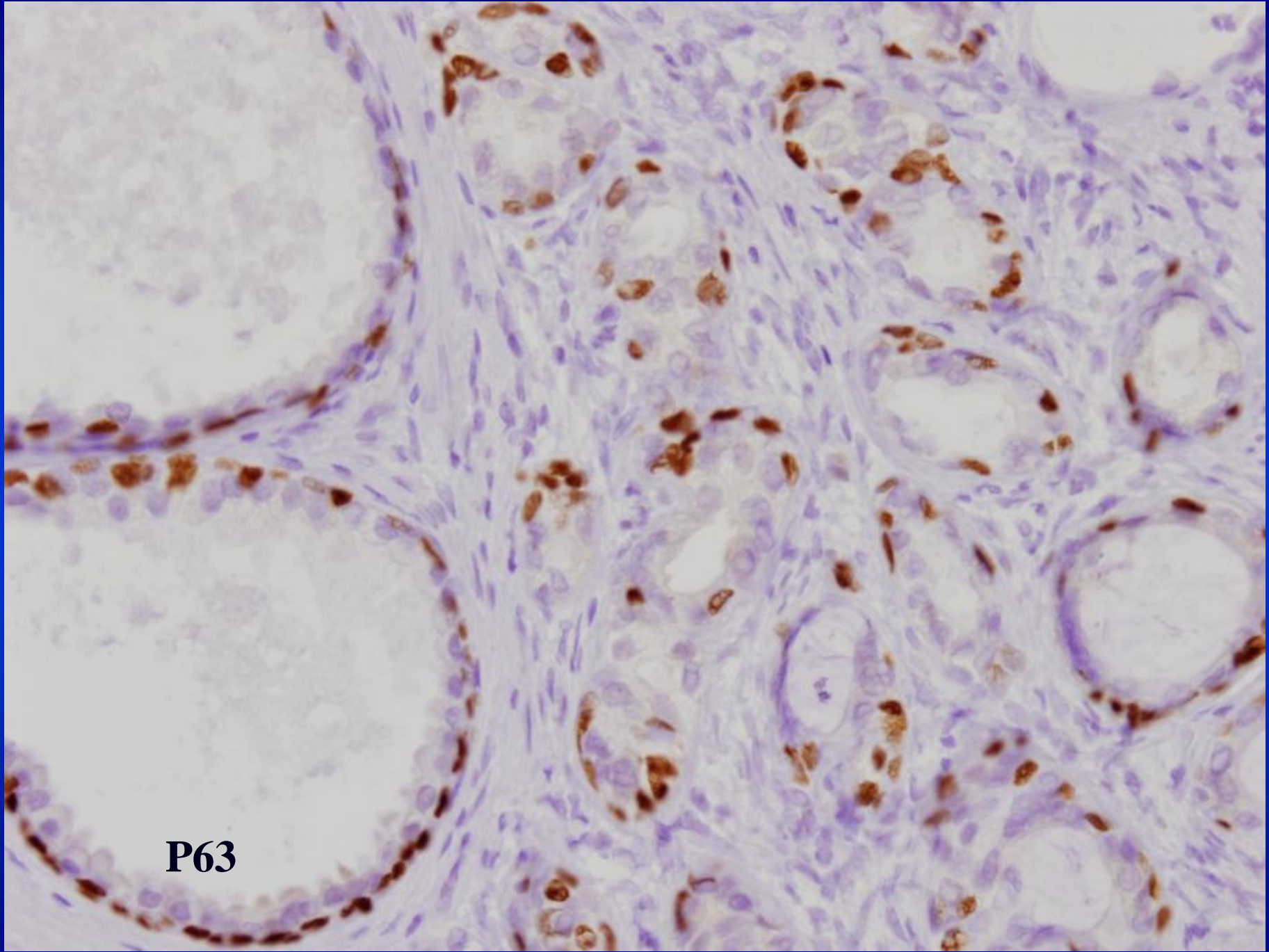




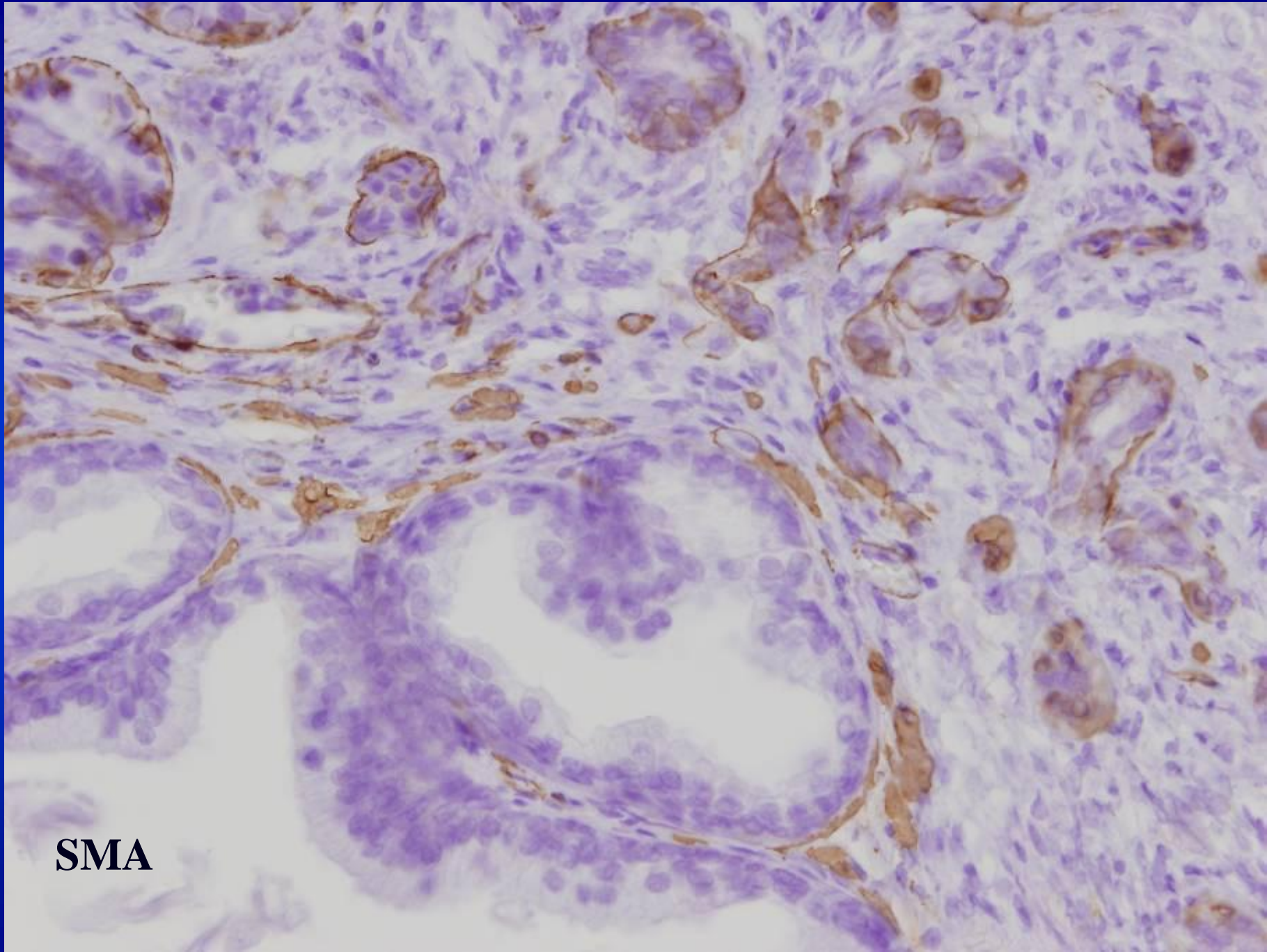




**HMWCK**



**P63**



**SMA**

# SA vs. carcinoma

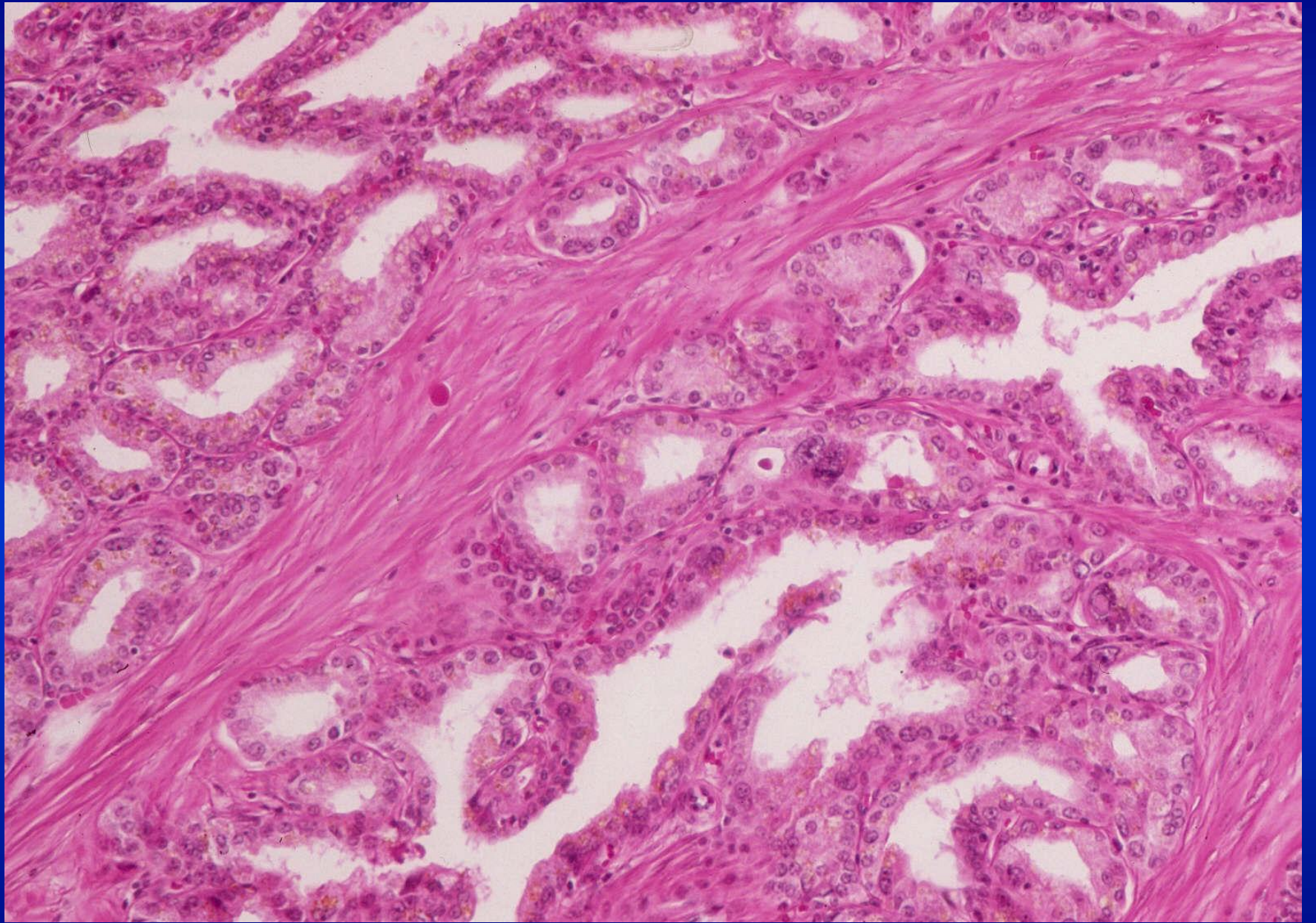
---

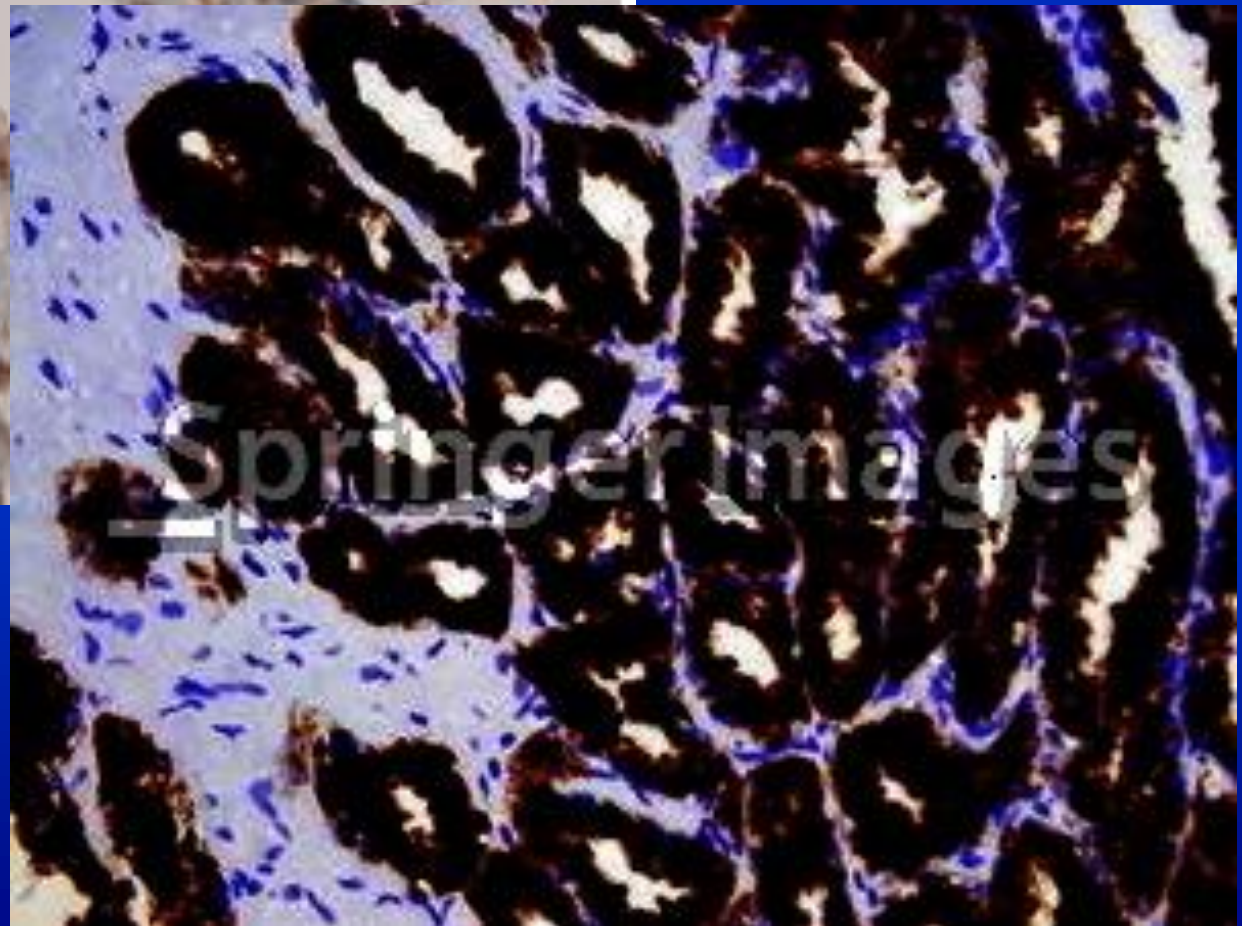
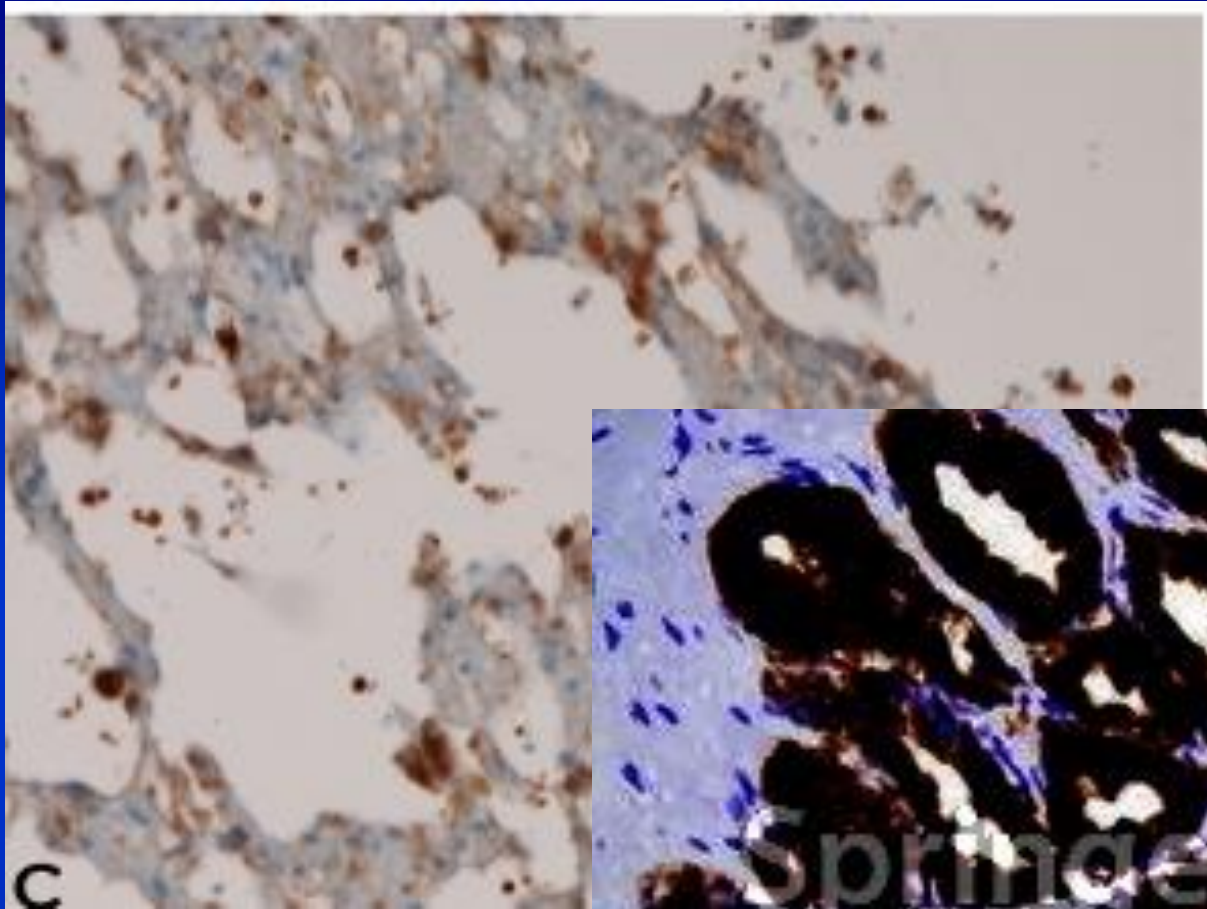
	SA	Carcinoma
<b>Stroma</b>	<b>Cellular Spindle</b>	<b>No stromal reaction Desmoplasia</b>
<b>Basal cells</b>	+	-
<b>Thick BM</b>	+	-
<b>P. nucleoli</b>	-/+	+
<b>Cryst/mucin</b>	+/-	+
<b>Borders</b>	<b>Circum</b>	<b>Infiltrative</b>
<b>Location</b>	<b>TZ</b>	<b>PZ</b>

---

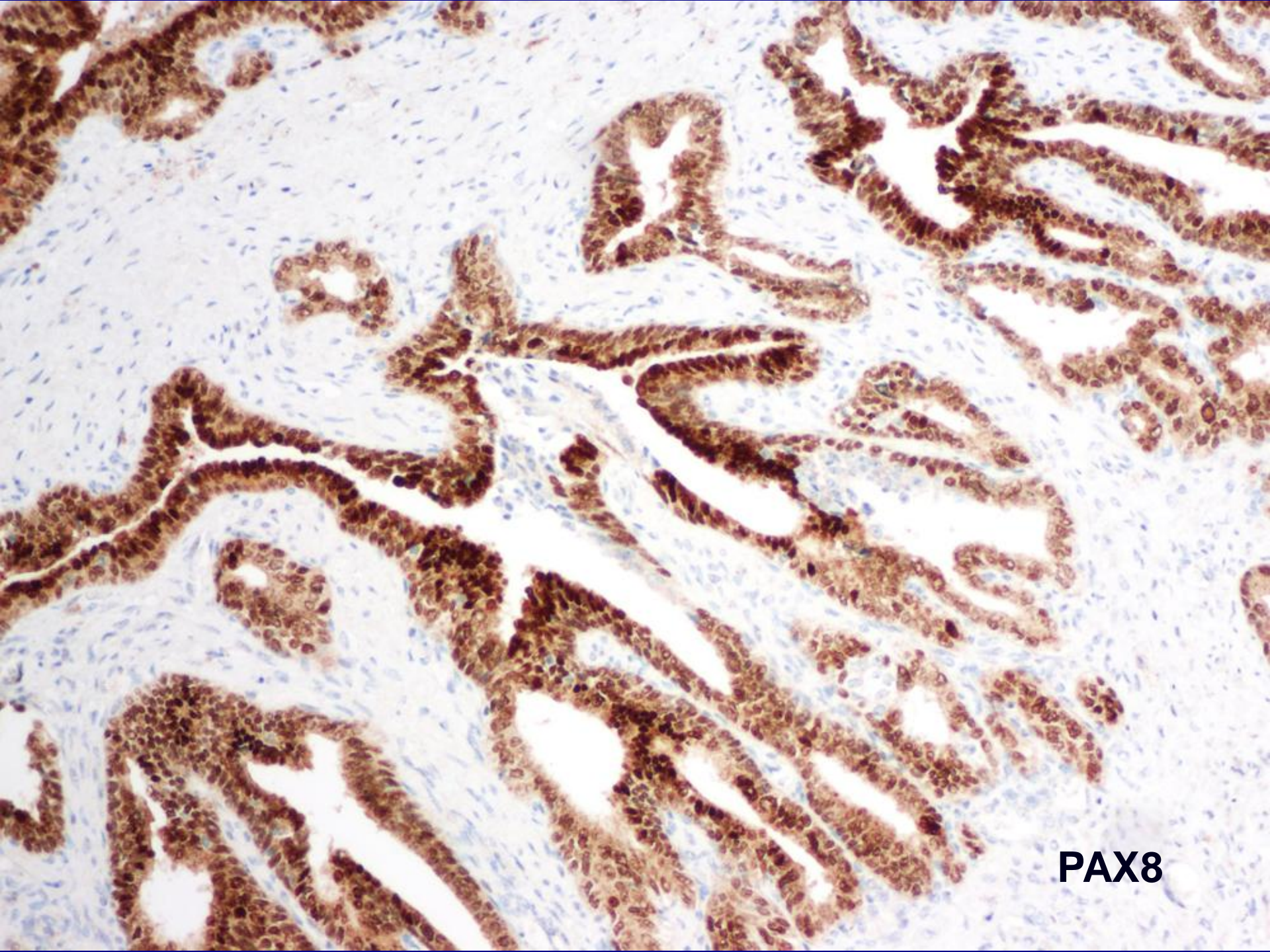
# Other small glands

- **Normal structures and metaplasia**
  - **Seminal vesicles/ejaculatory ducts, Cowper's glands,**
- **Atrophy**
- **Basal cell hyperplasia**
- **Clear cell cribriform hyperplasia**
- **Nephrogenic adenoma**
- **Mesonephric hyperplasia**
- **Verumontanum mucosal gland hyperplasia**

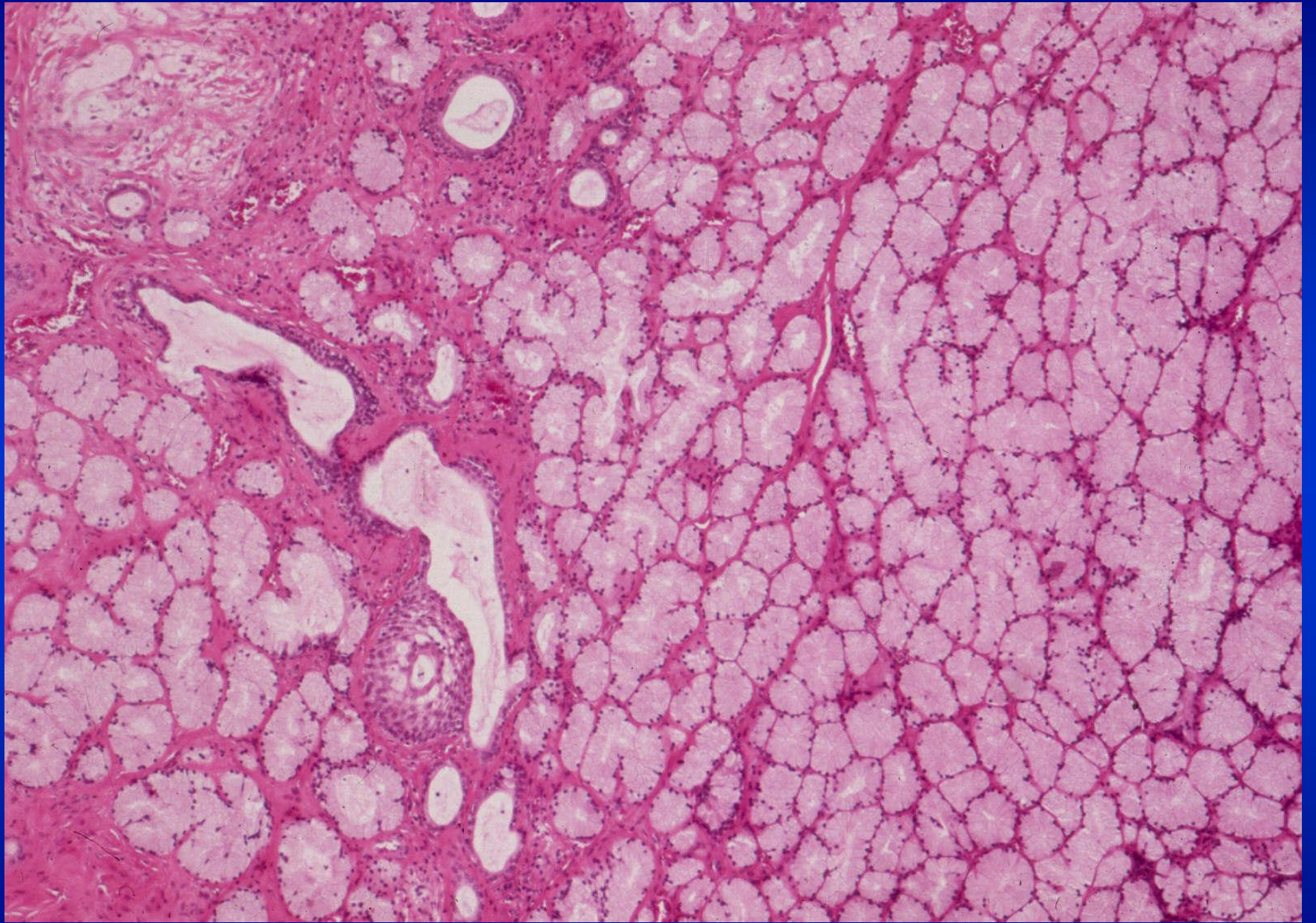


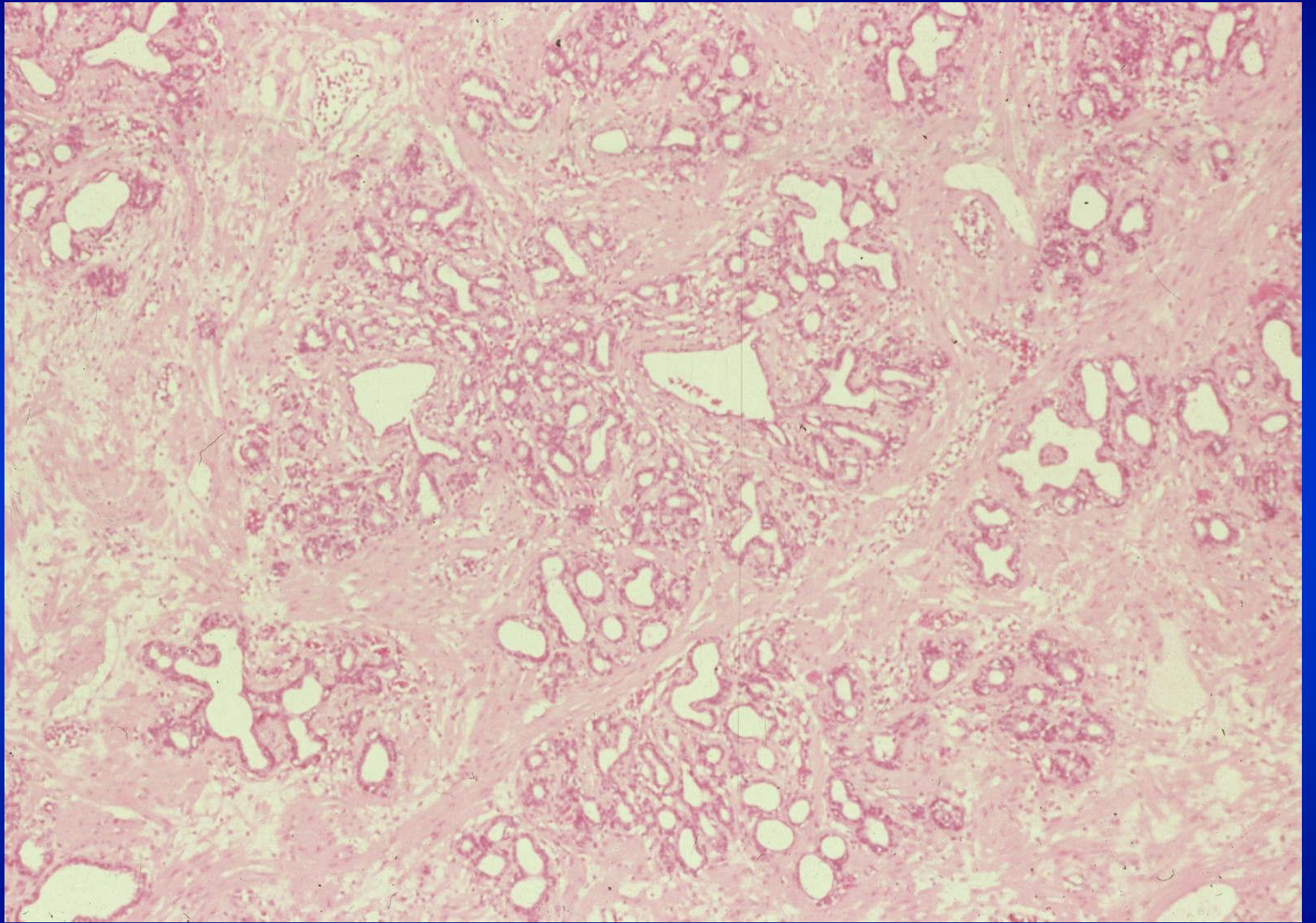


**MUC6**

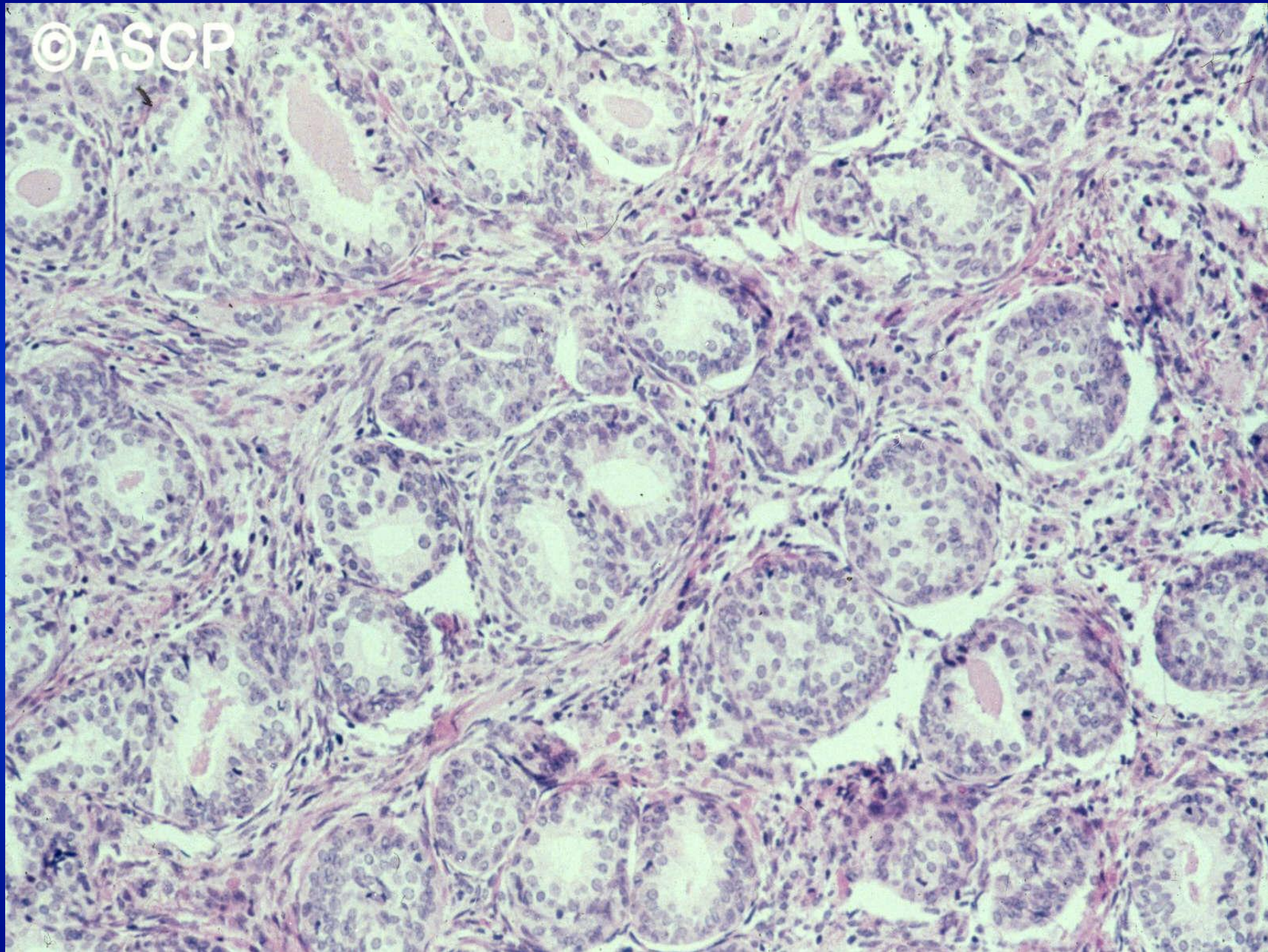


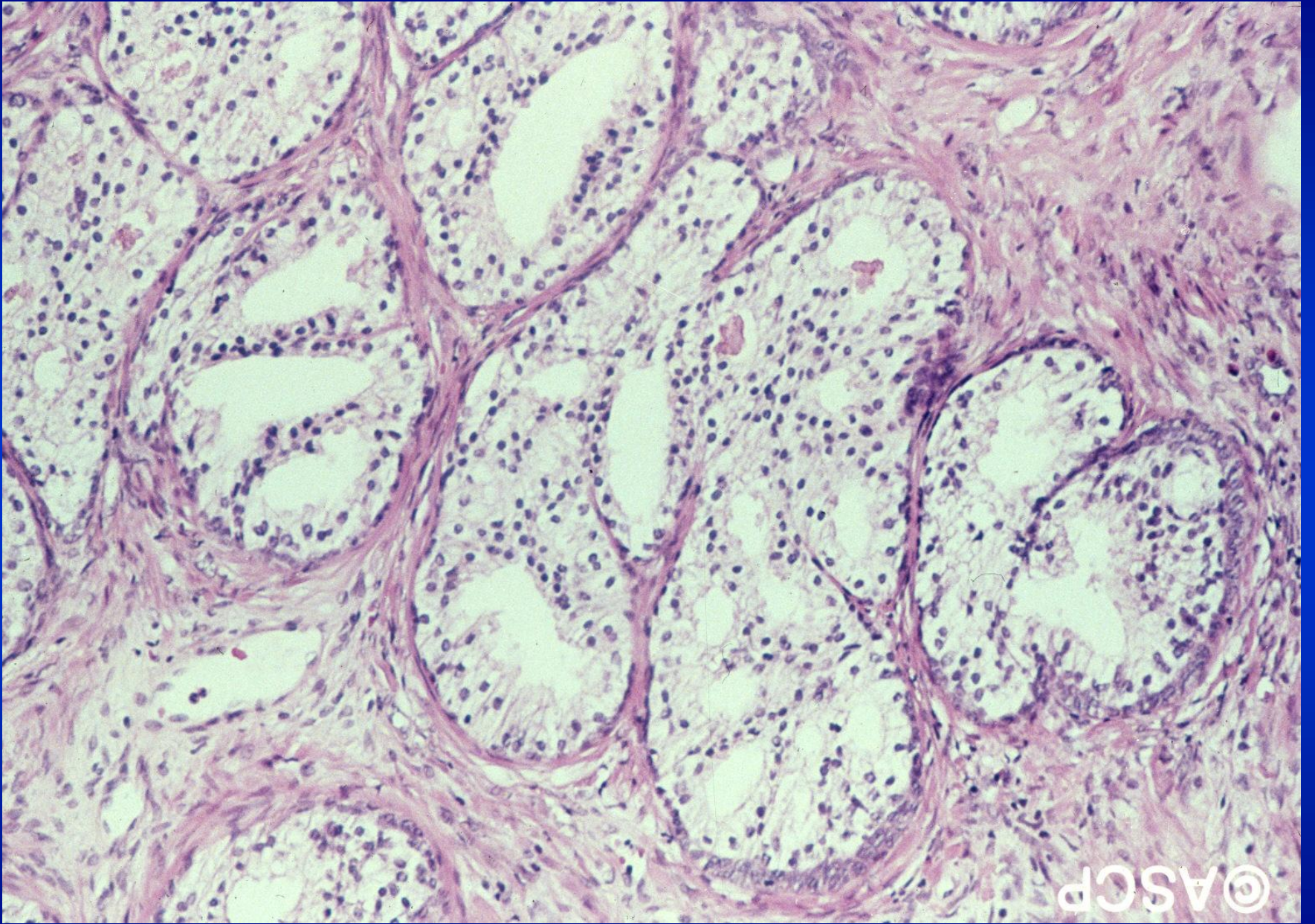
**PAX8**

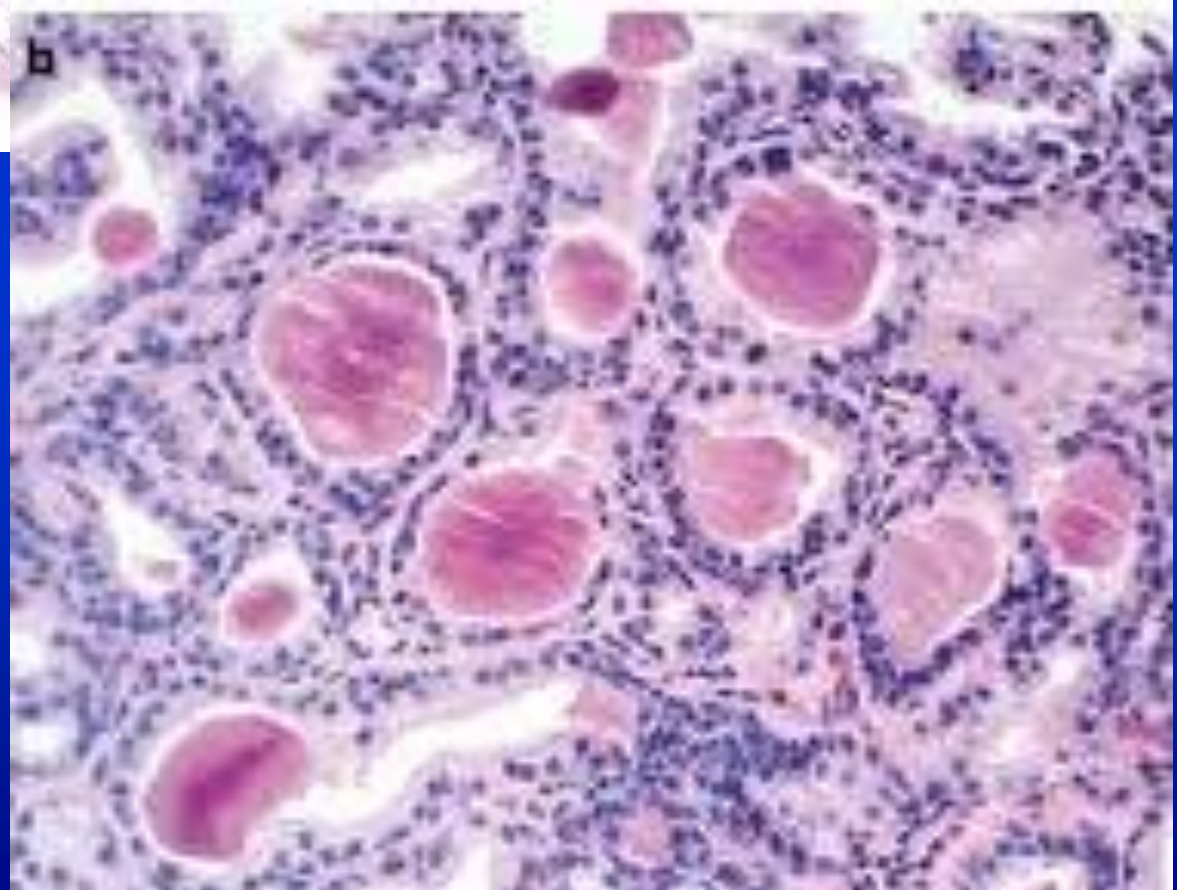
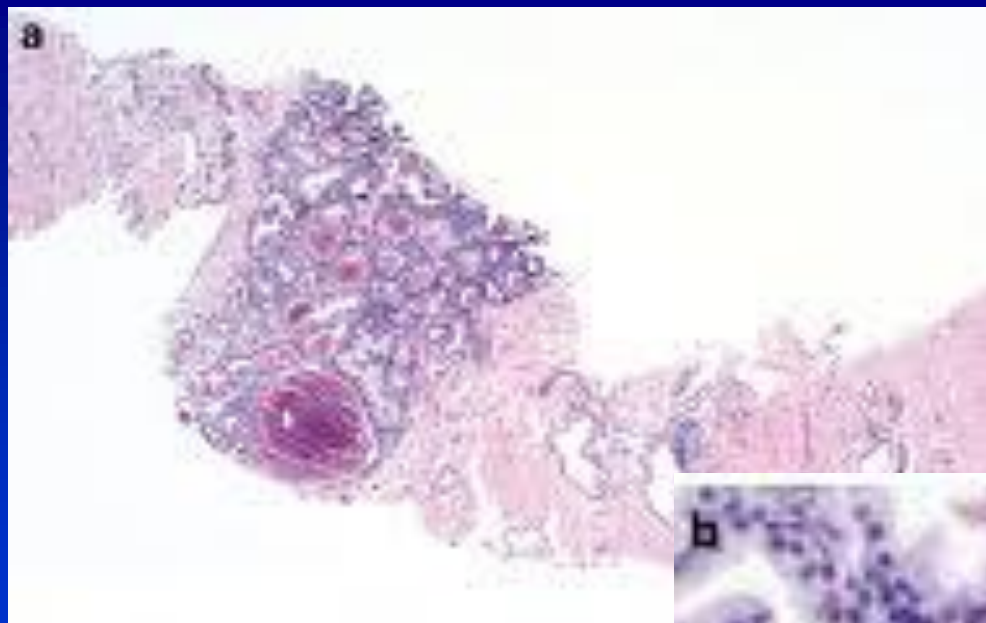


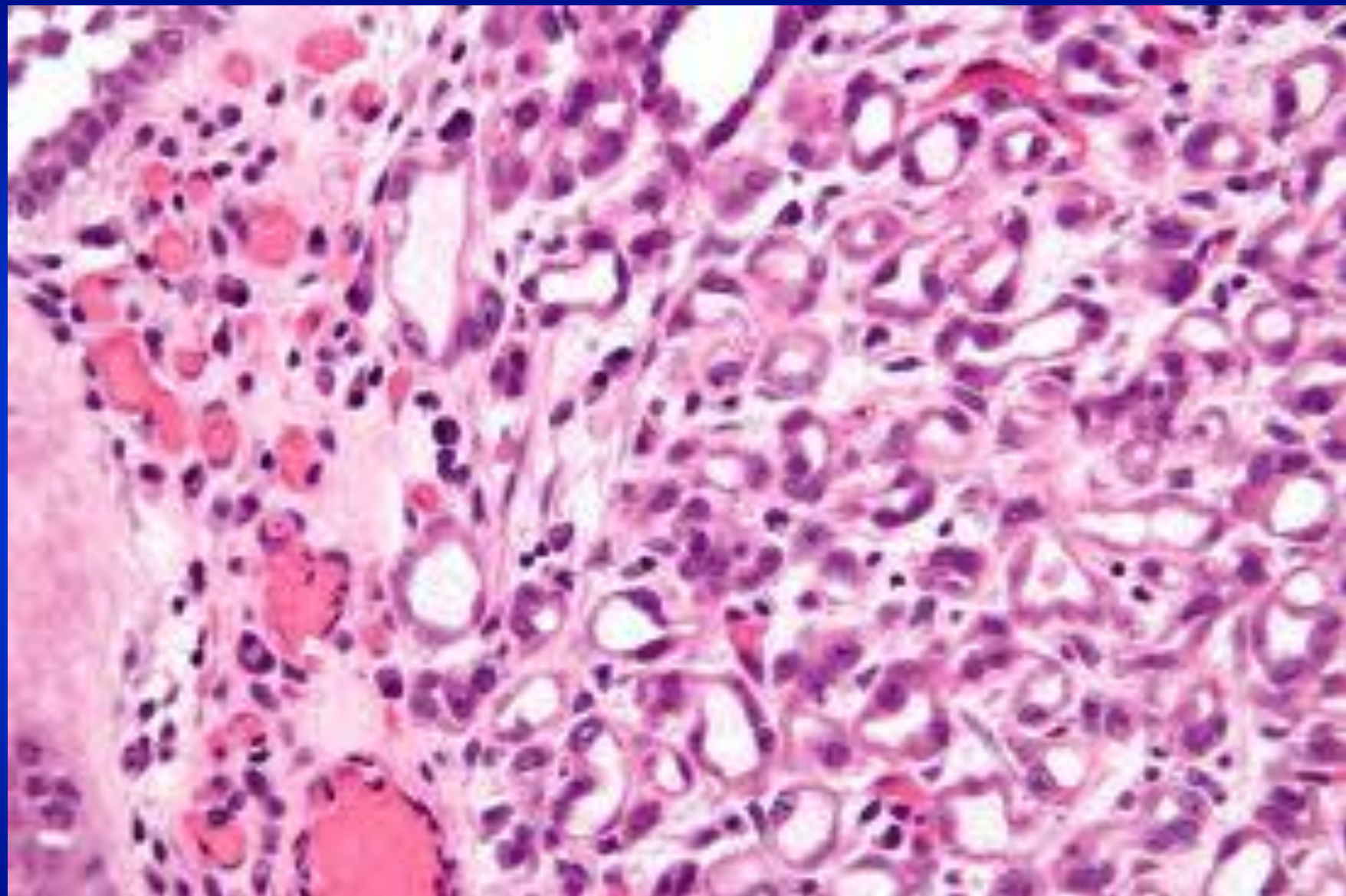


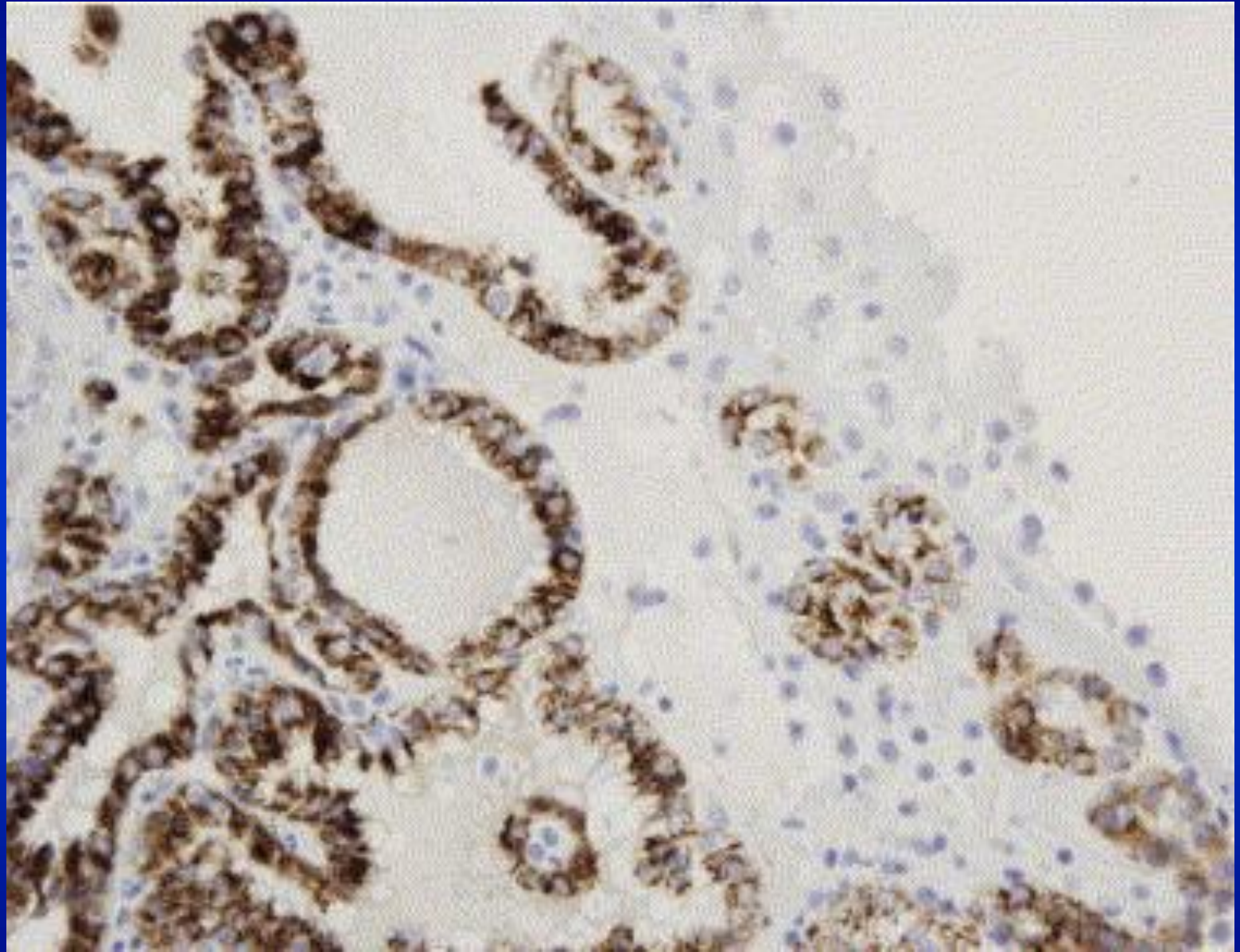
©ASCP

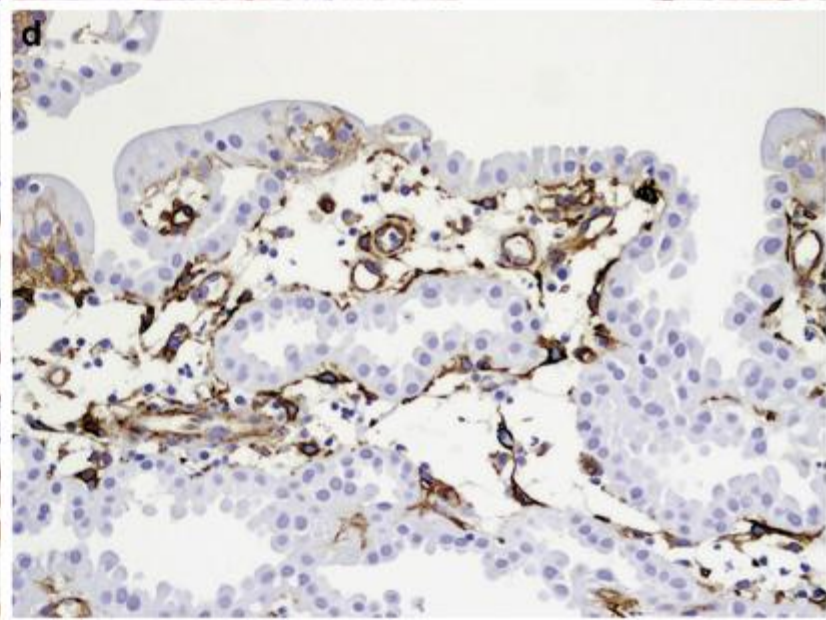
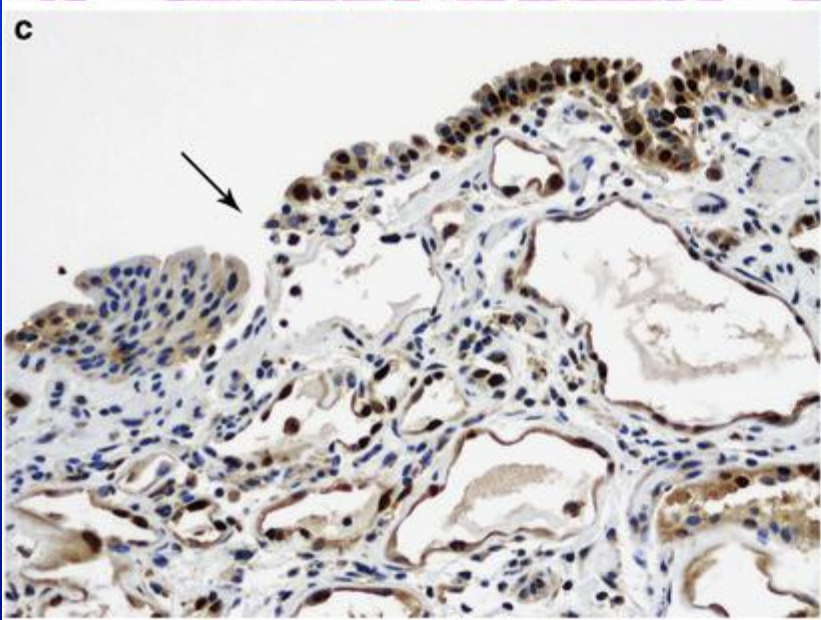
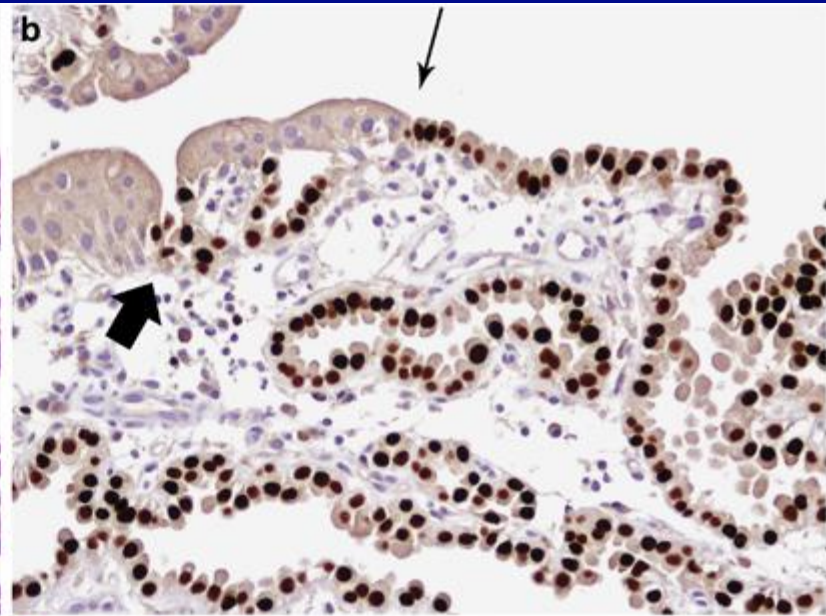
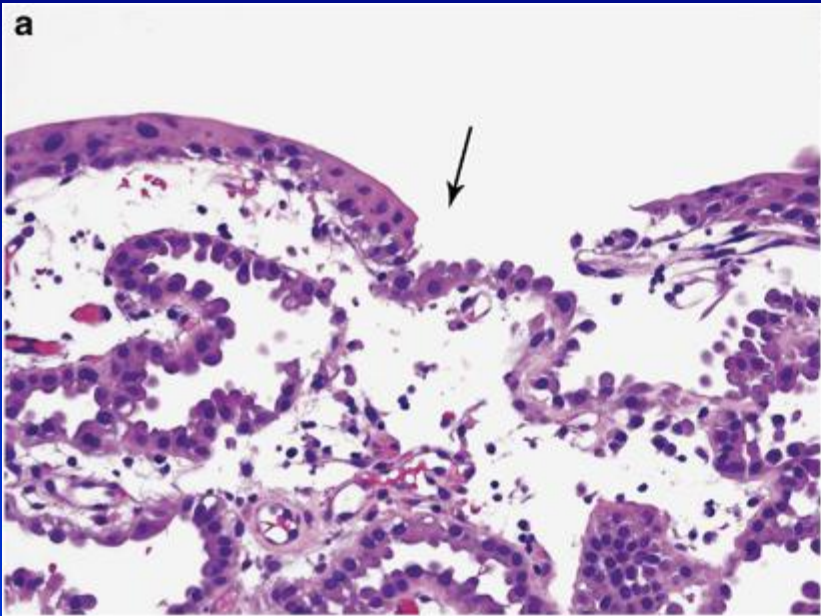


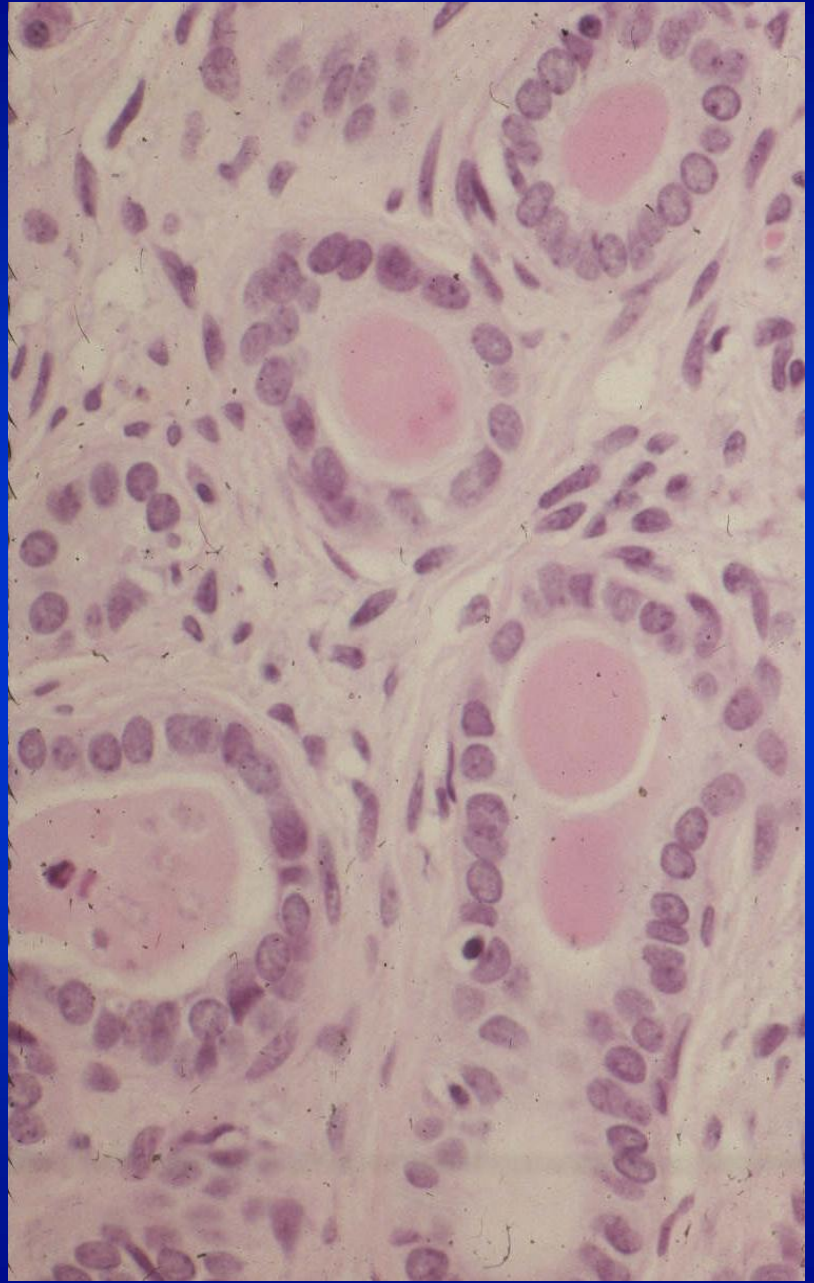
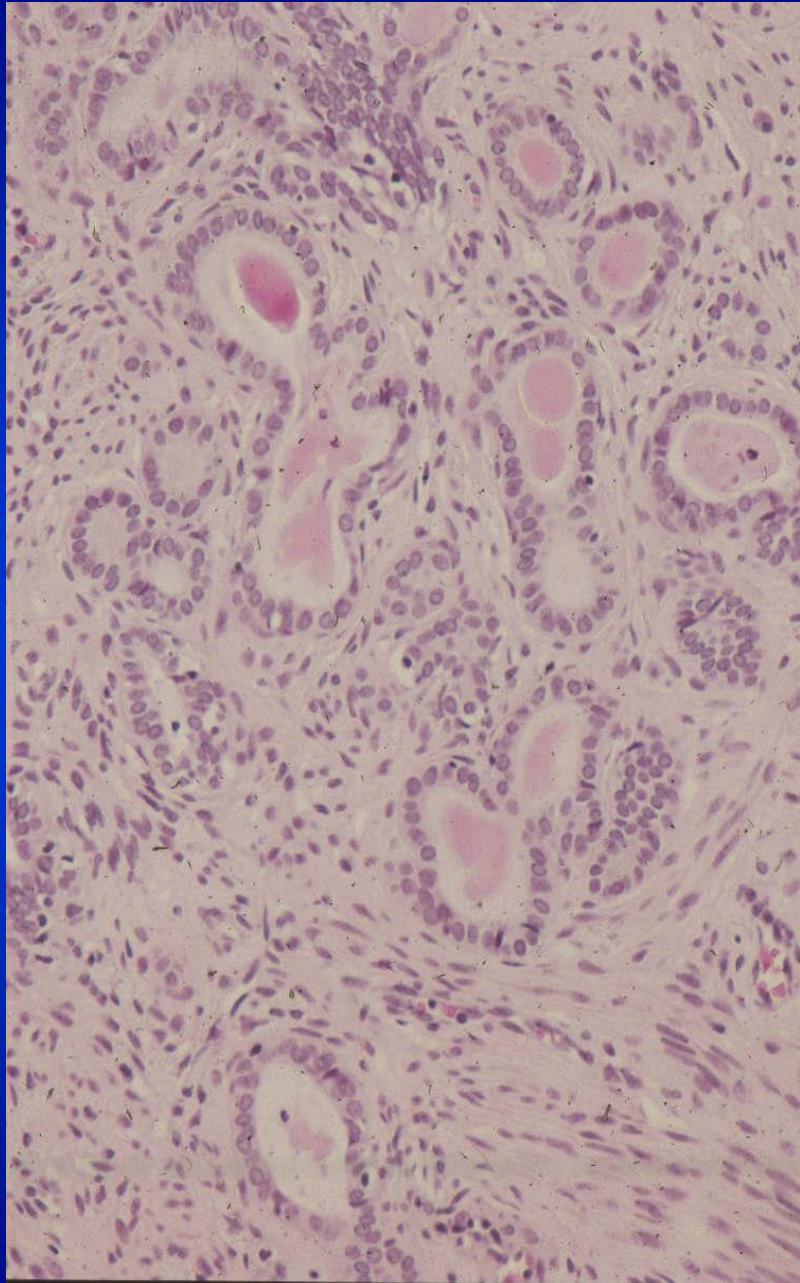


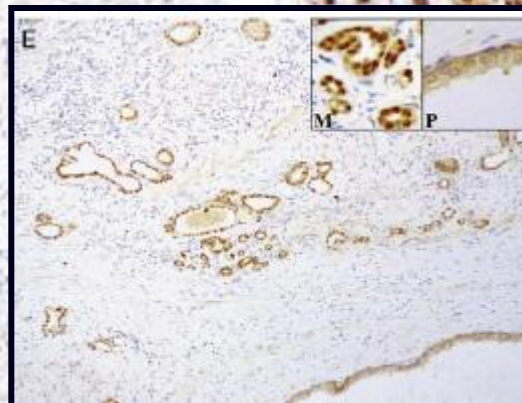
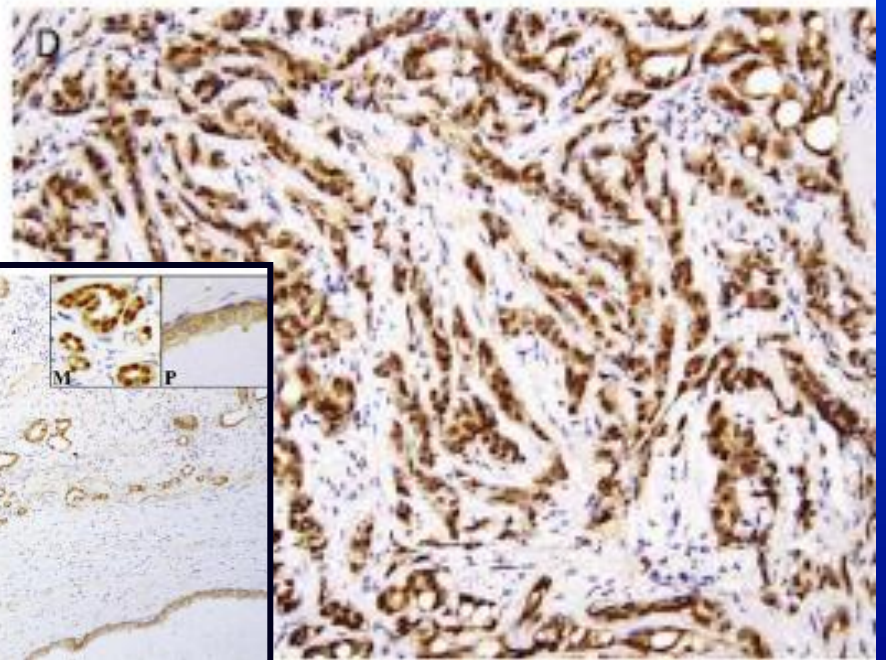
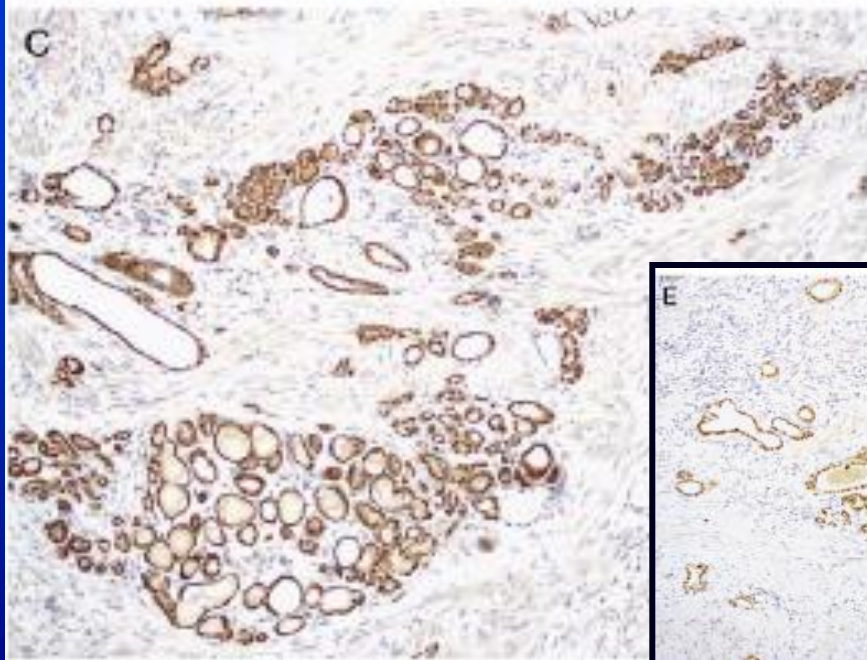
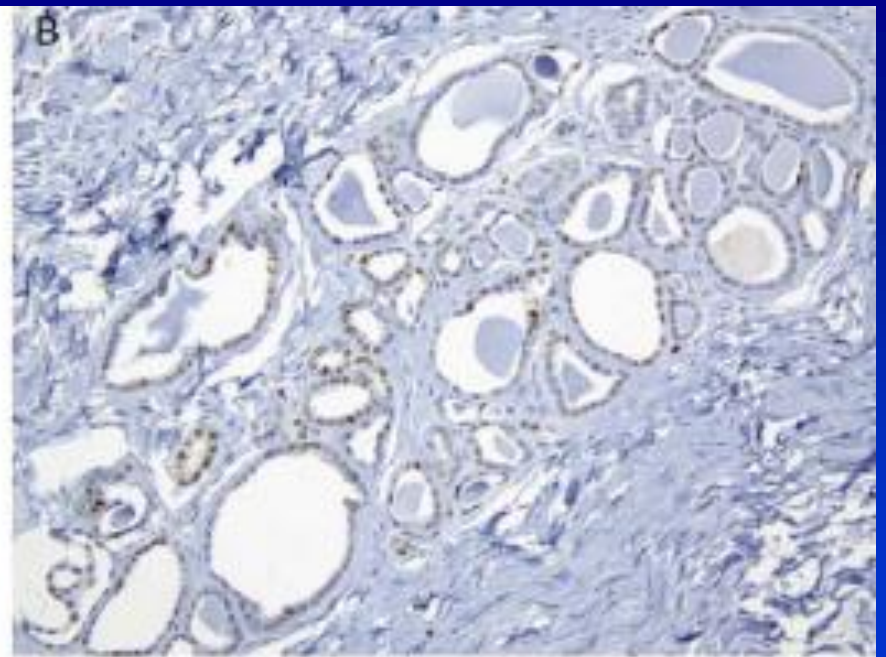
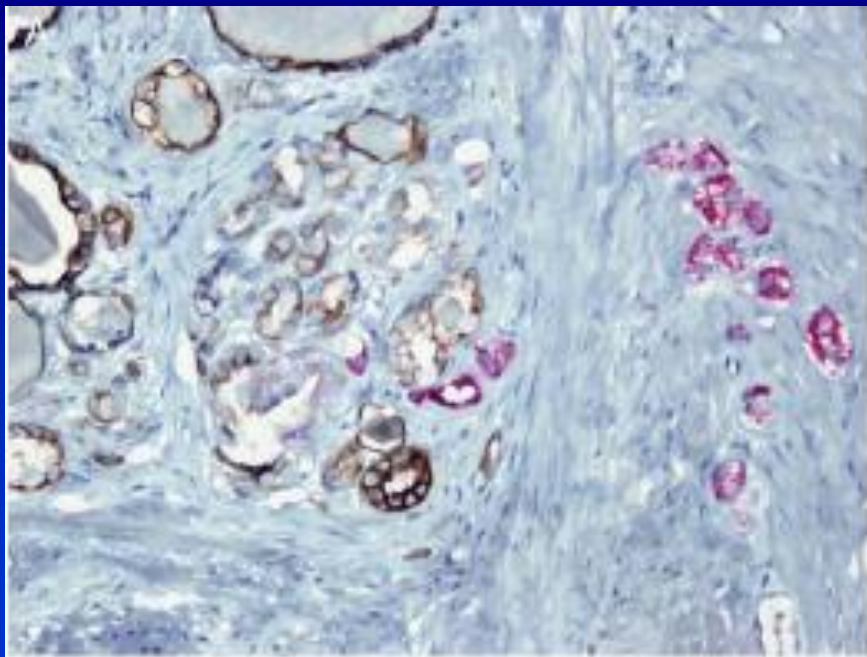






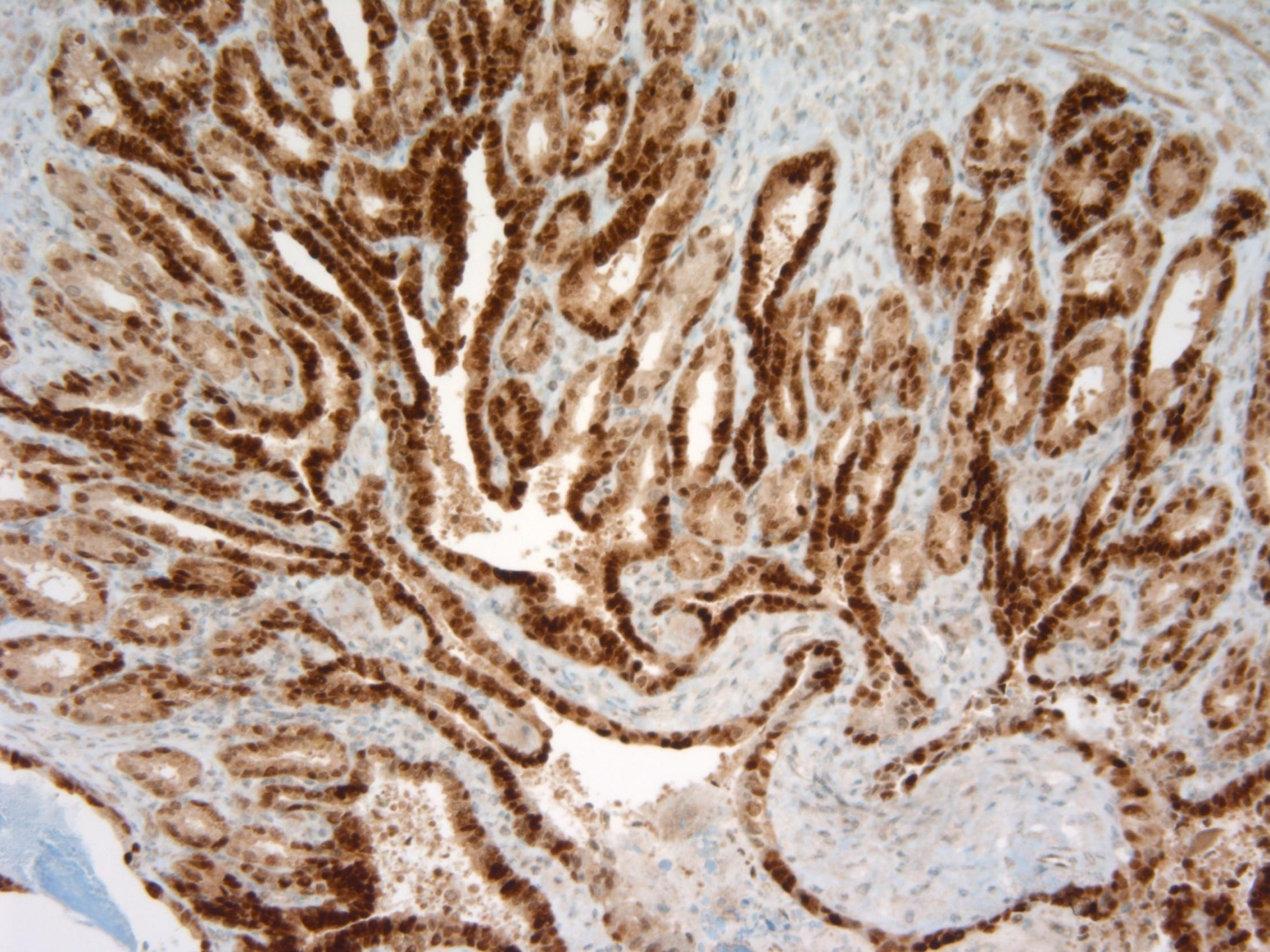


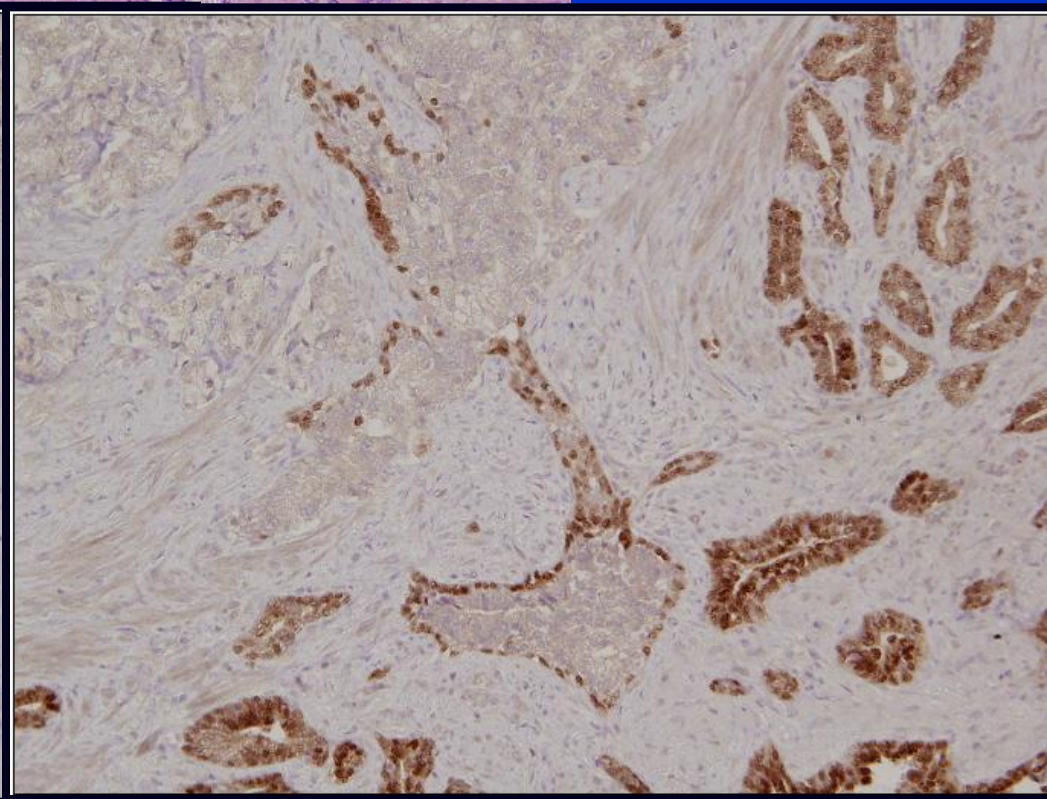
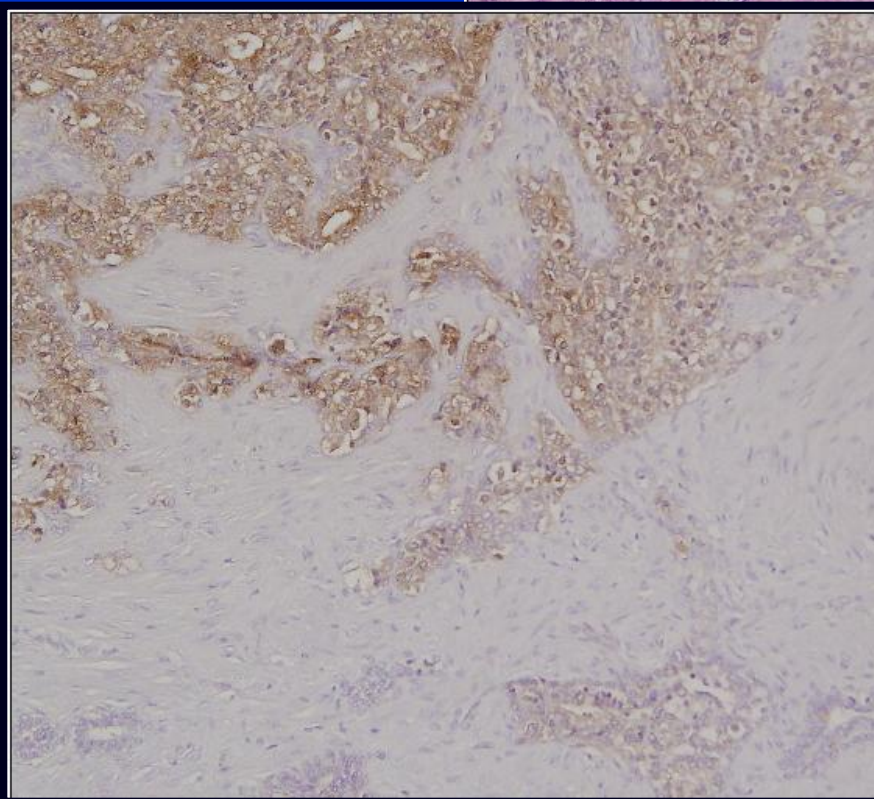
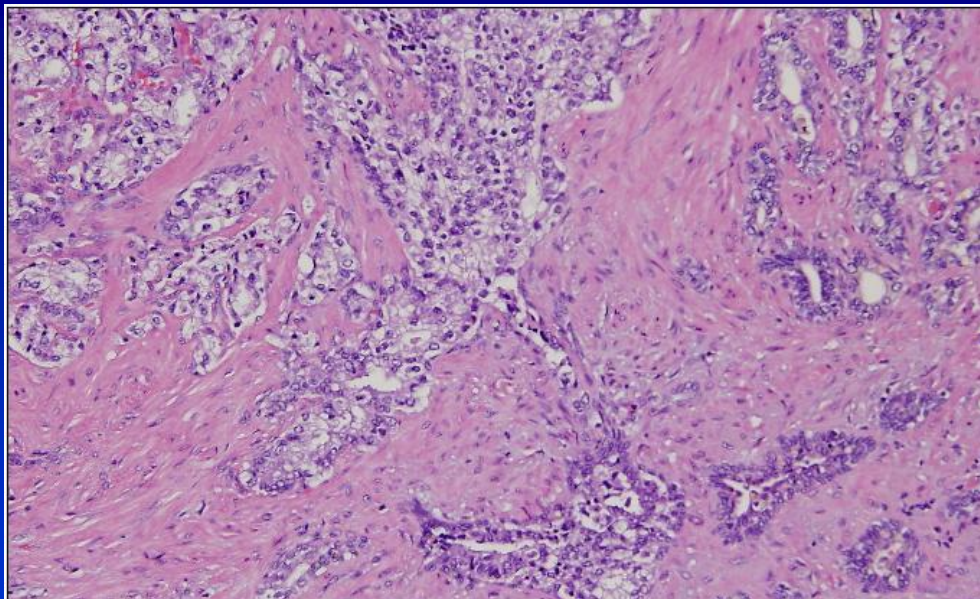




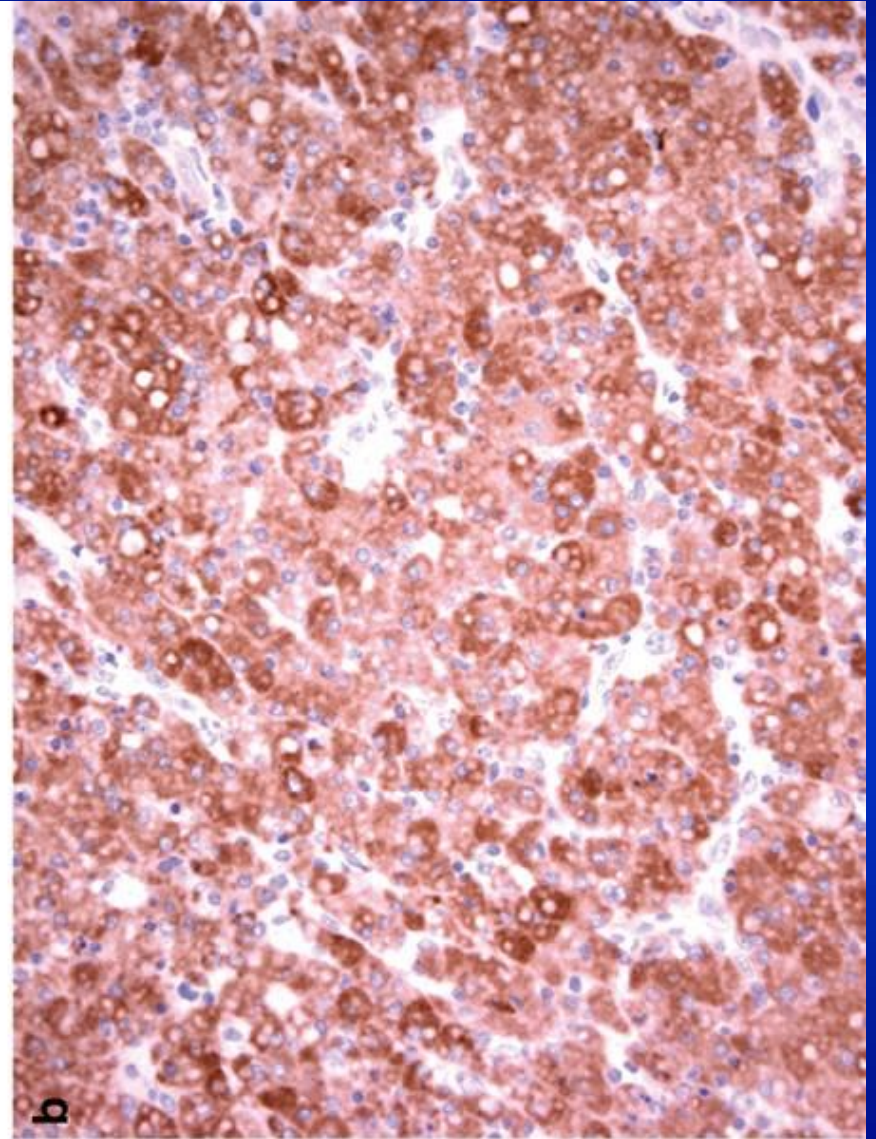
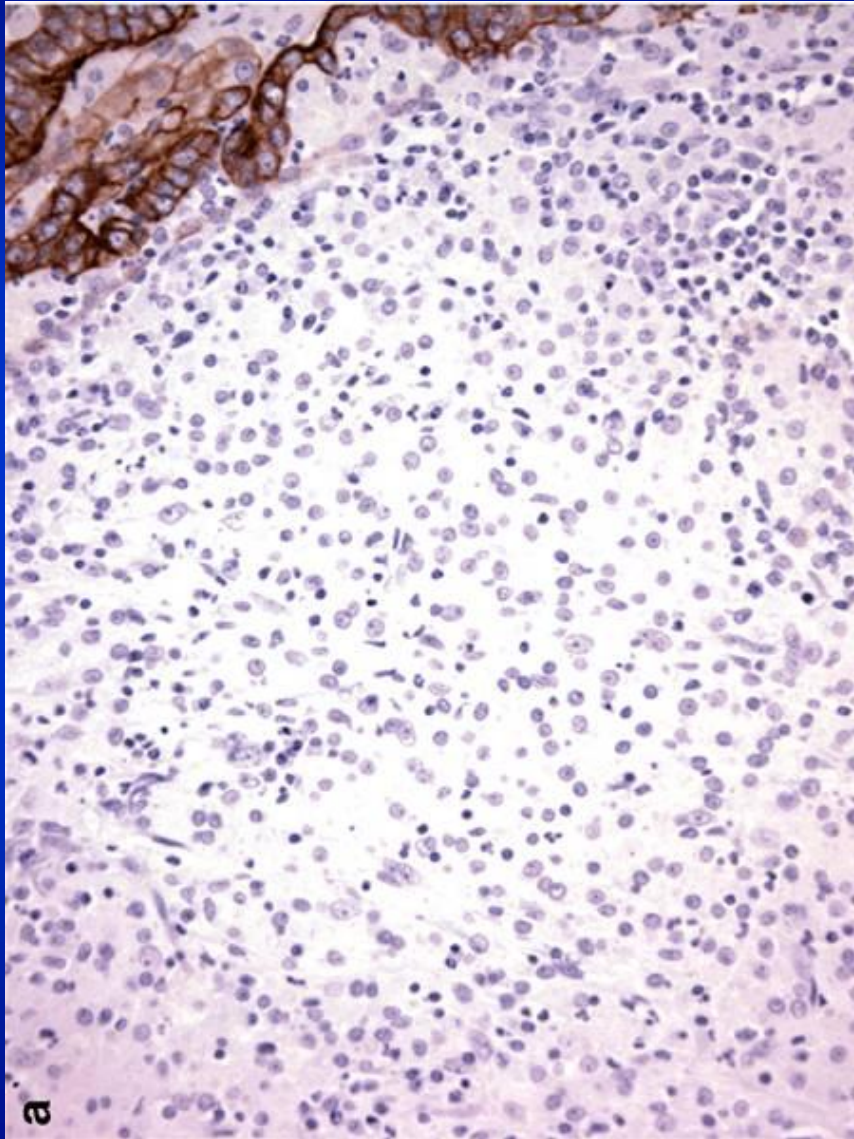
# Prostate Ca and Mimickers

	Pca	SV	NA	Others
PSA, PAP, PSMA	+	-	-/+	-/+
CD57	+	-	-	-
AR	+	+	-	-
ER, PR	-/+	-	-	-
AMACR	+	-	+	-
Erg	+	-	-	-
HMCK, CK5/6, p63	-	+	-/+	+
PAX2, PAX8	-	+	+	-



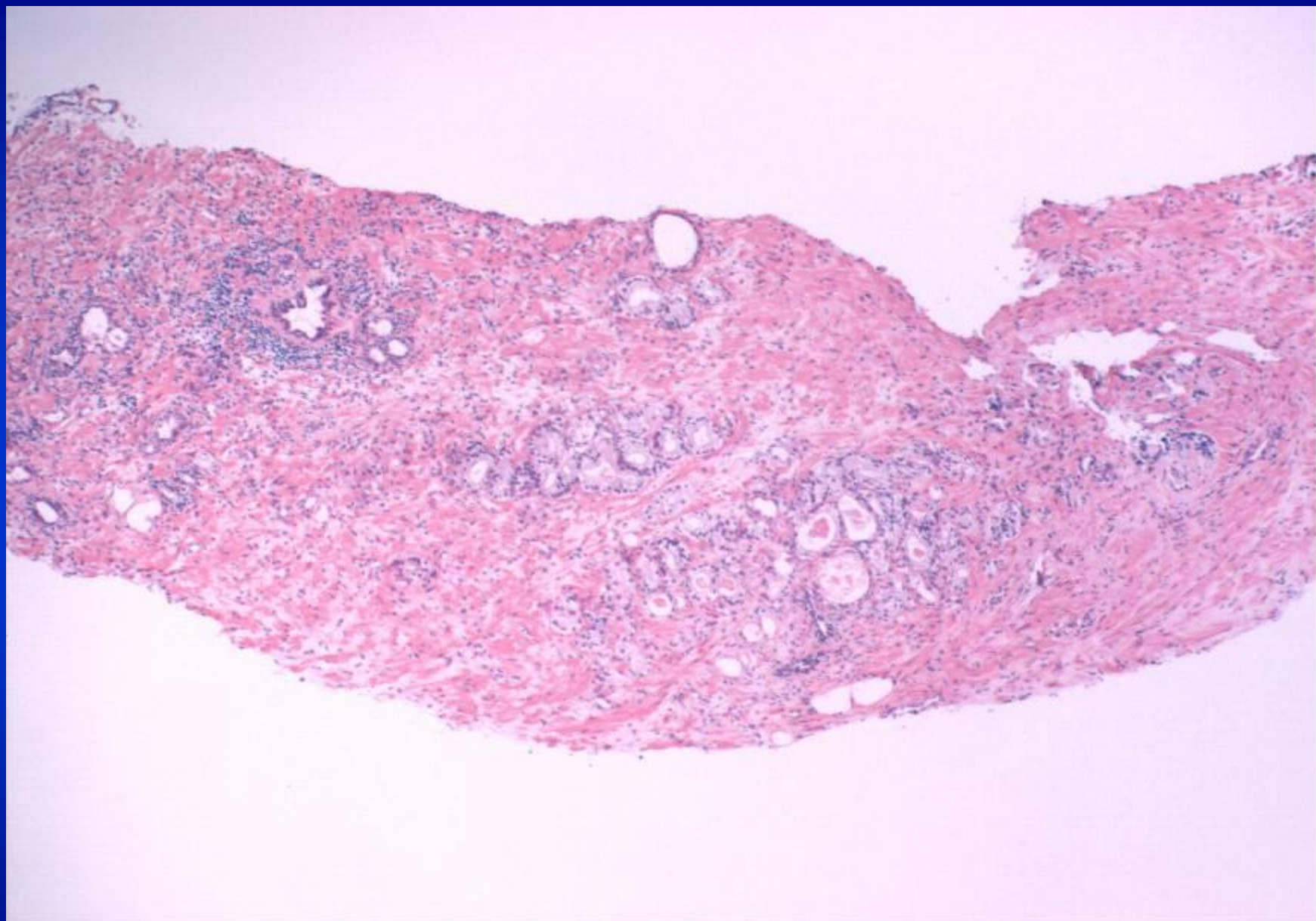


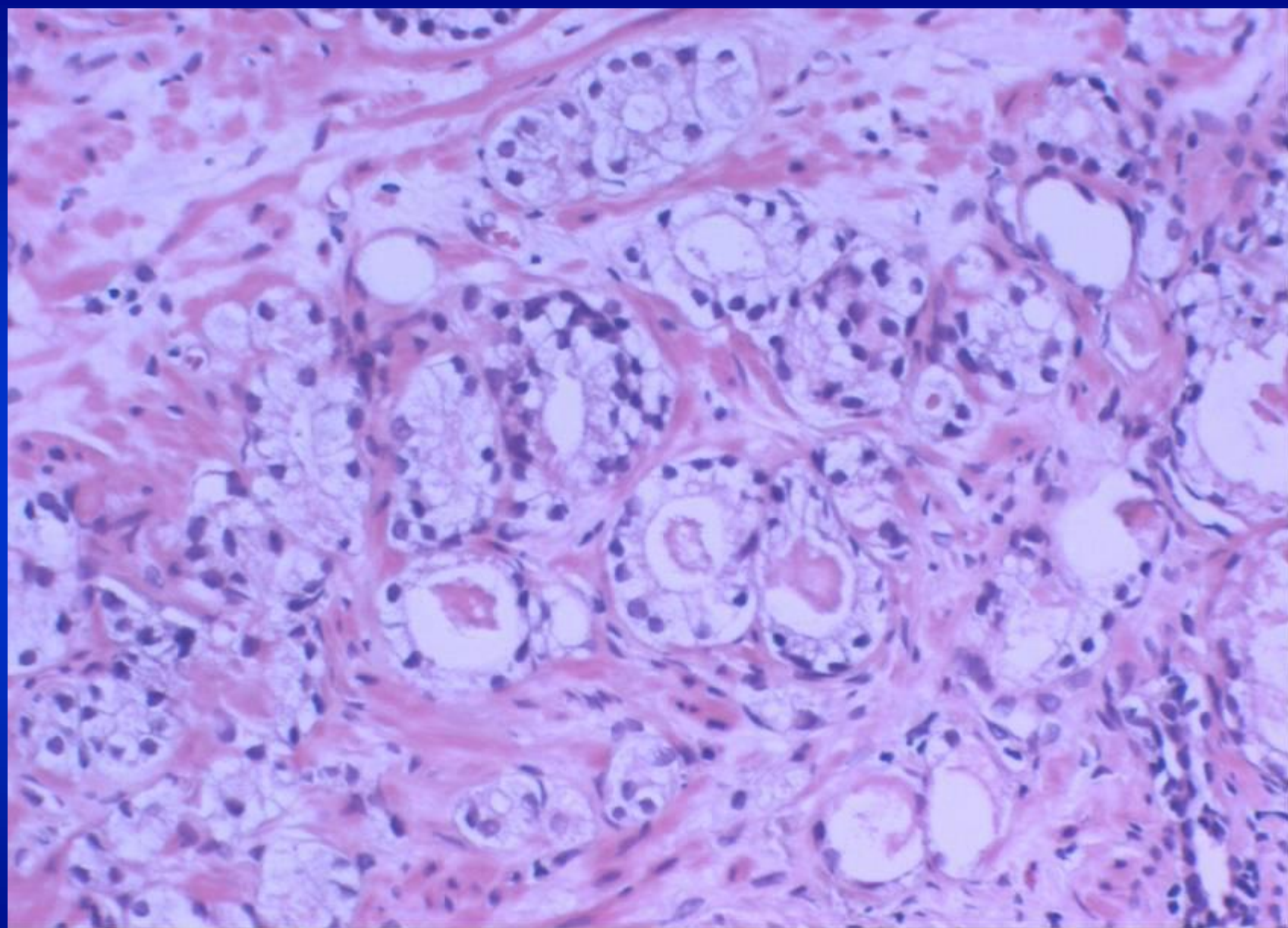
# Idiopathic granulomatous prostatitis

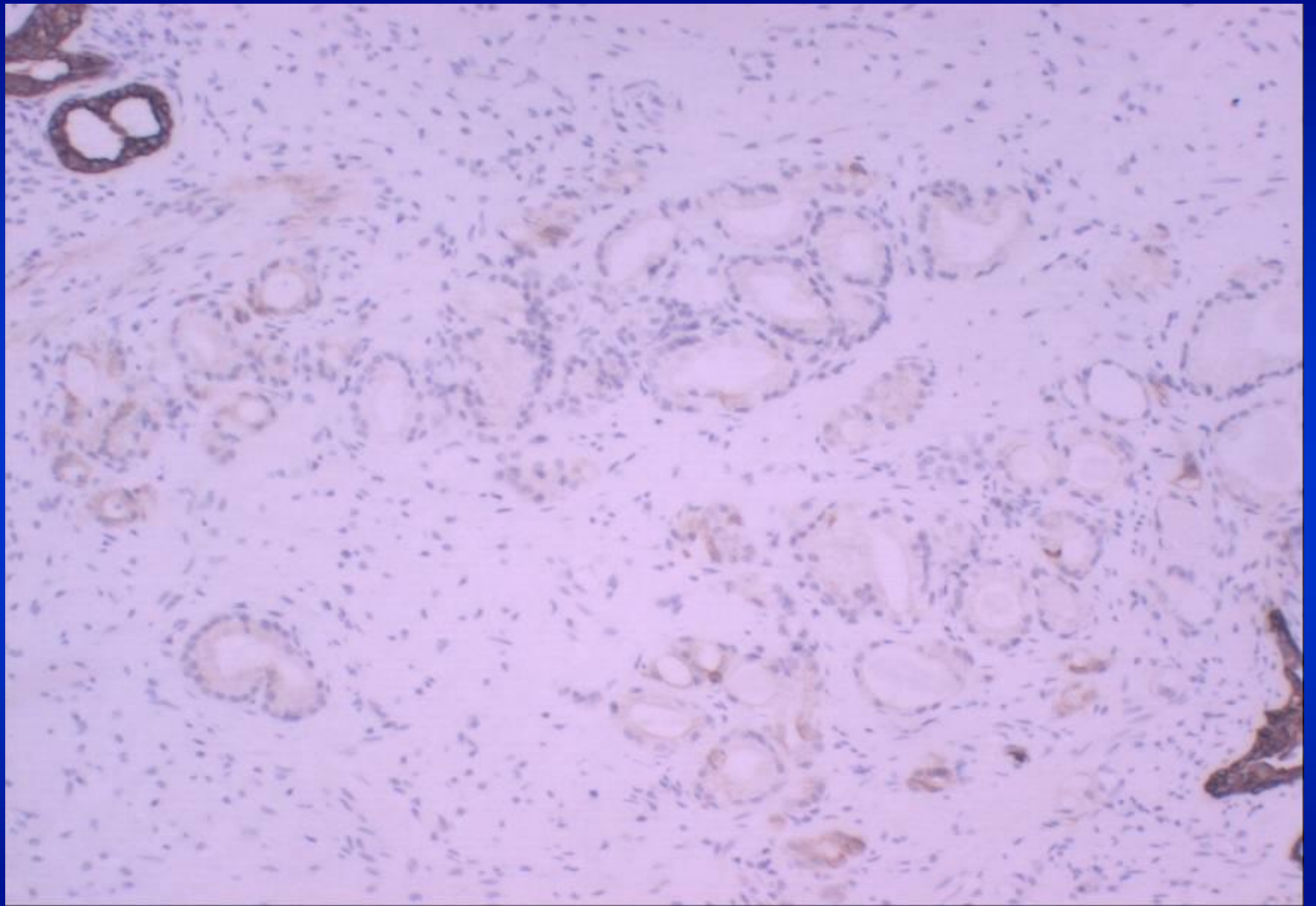


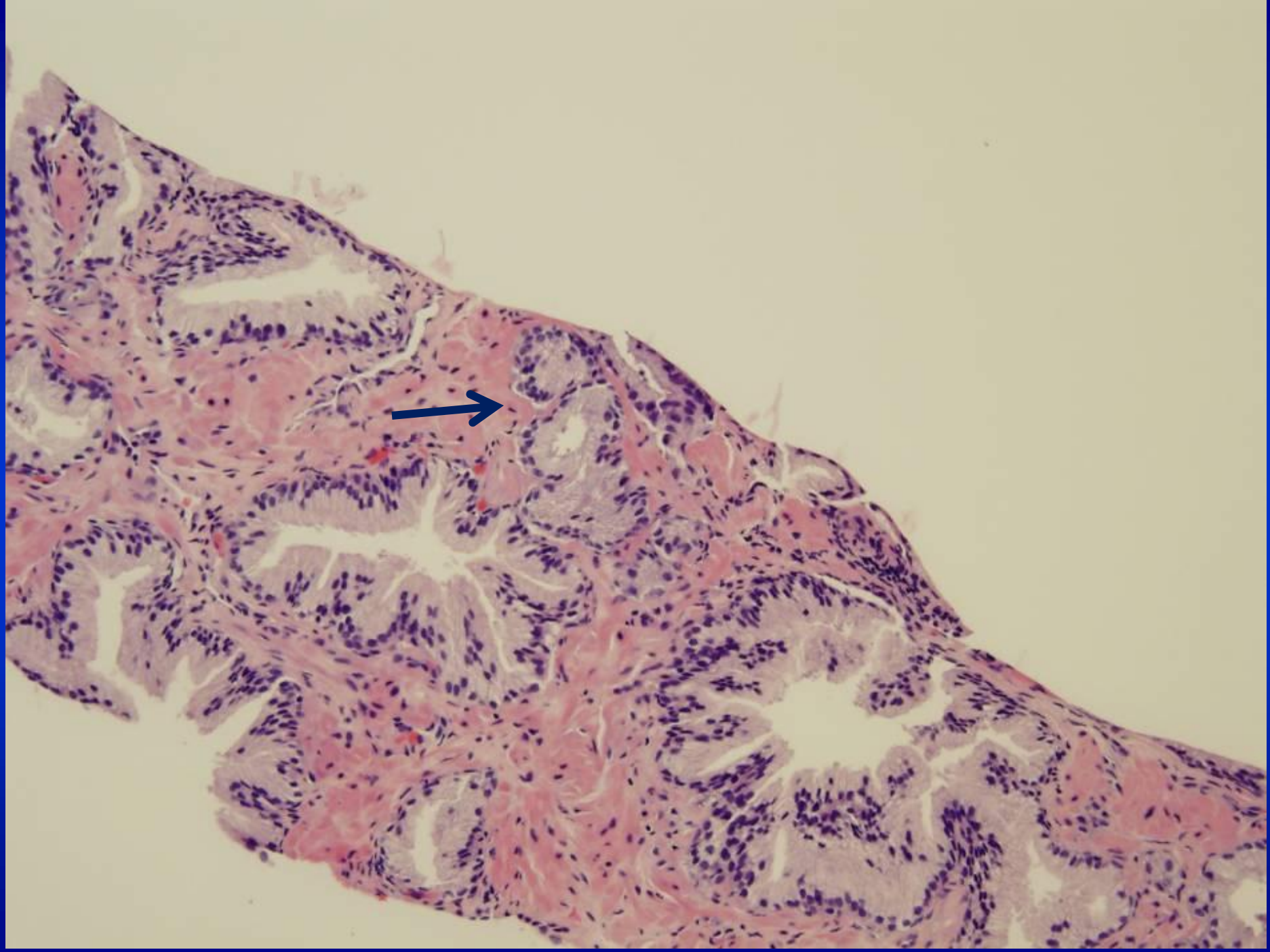
# Atypical small acinar proliferation (ASAP)

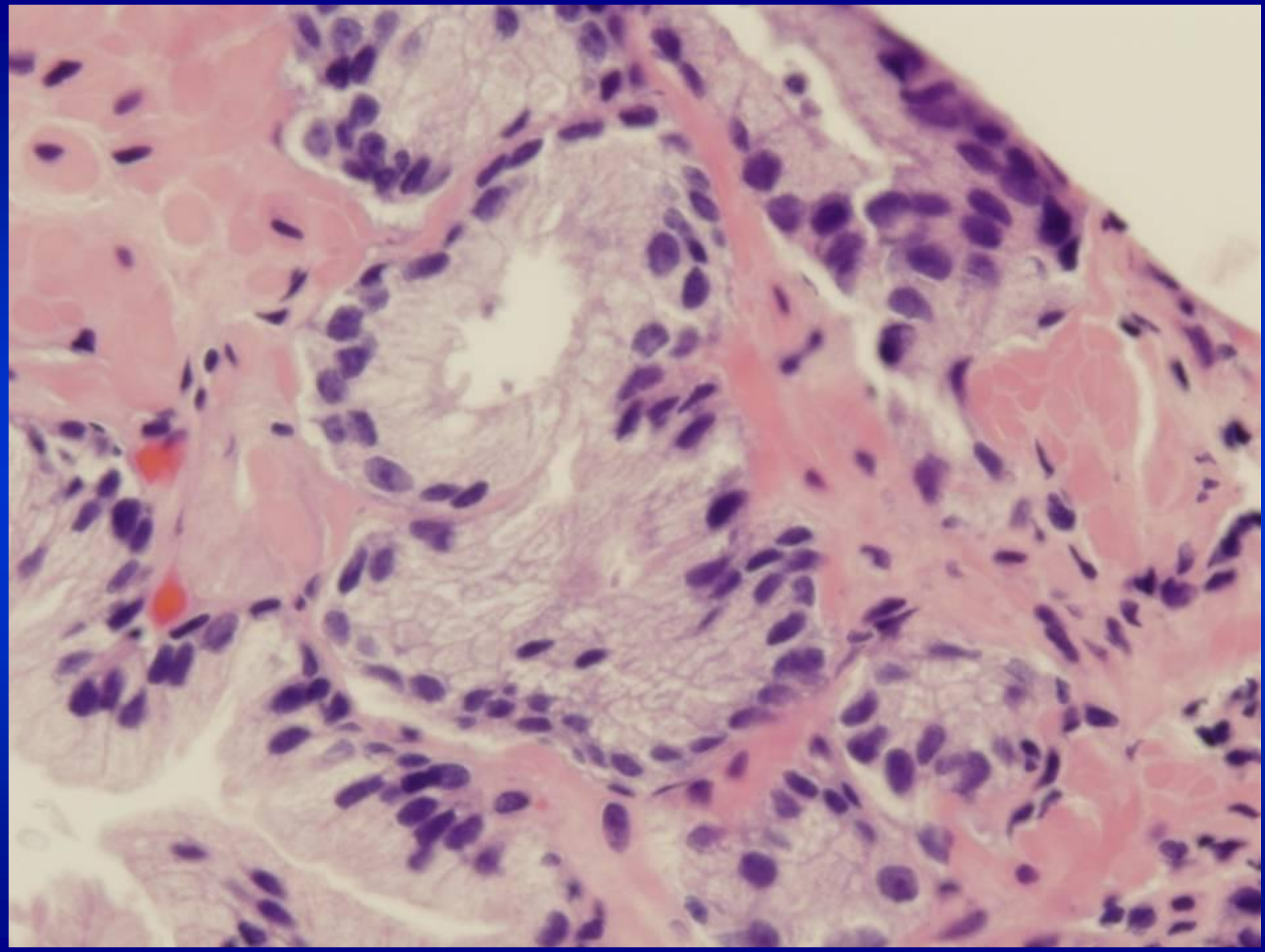
- **Size:**
  - 1) small number of acini in focus of concern
  - 2) small focus size, average 0.4 mm in greatest dimension
  - 3) lesion breakage at core tip
- **Histology:**
  - 1) lack of clear histologic detail
  - 2) distortion of acini
  - 3) lack of convincing malignant features
  - 4) clustered growth pattern mimicking benign process such as AAH or atrophy
  - 5) loss of the focus of concern in deeper
  - 6) focal positive HMWCK or negative racemase
  - 7) presence of PIN raising the possibility of tangential cutting
- **Inflammation:**
  - 1) overdiagnosis of reactive changes or atrophy
  - 2) reactive atypia with nuclear and nucleolar enlargement

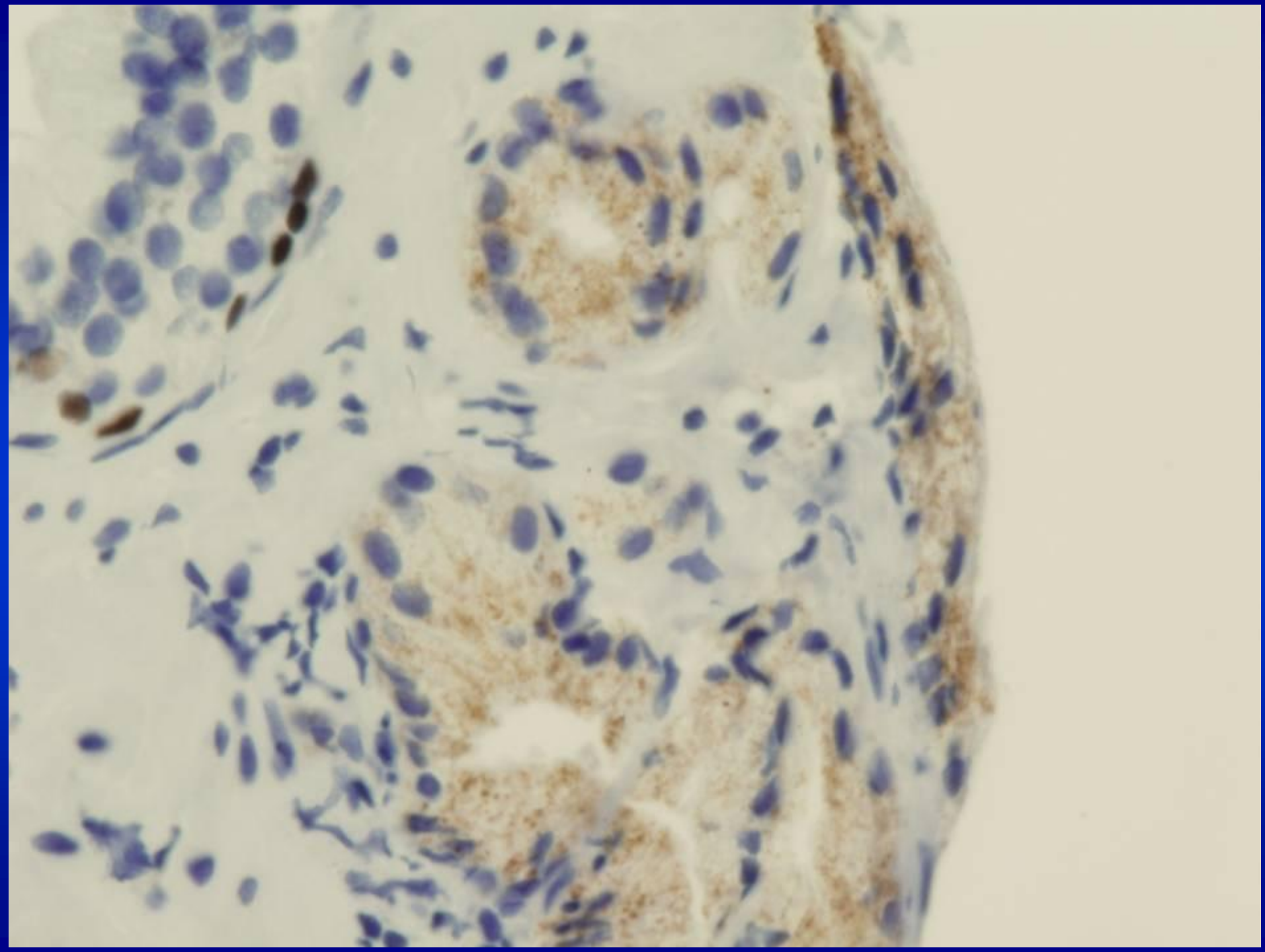


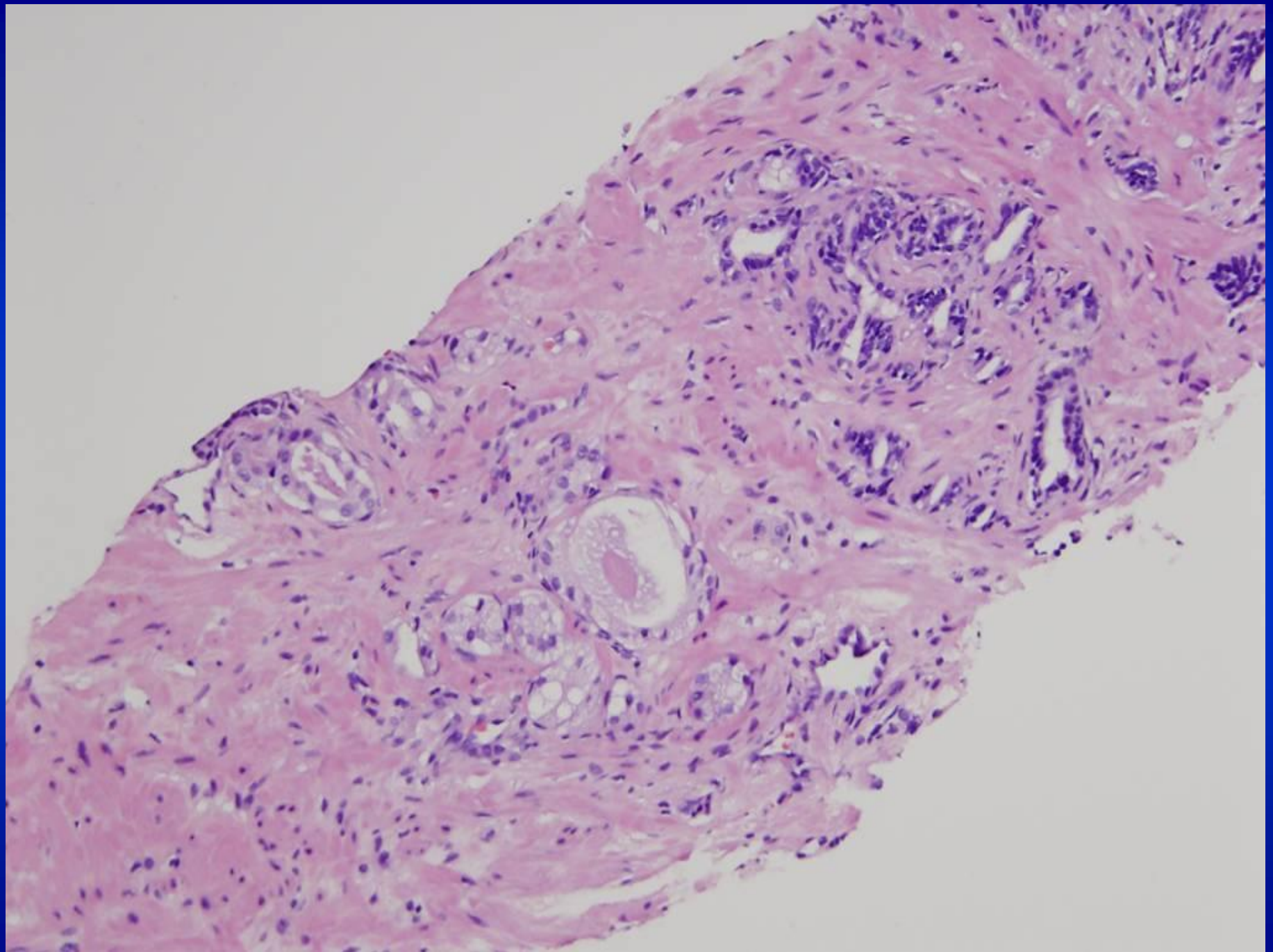


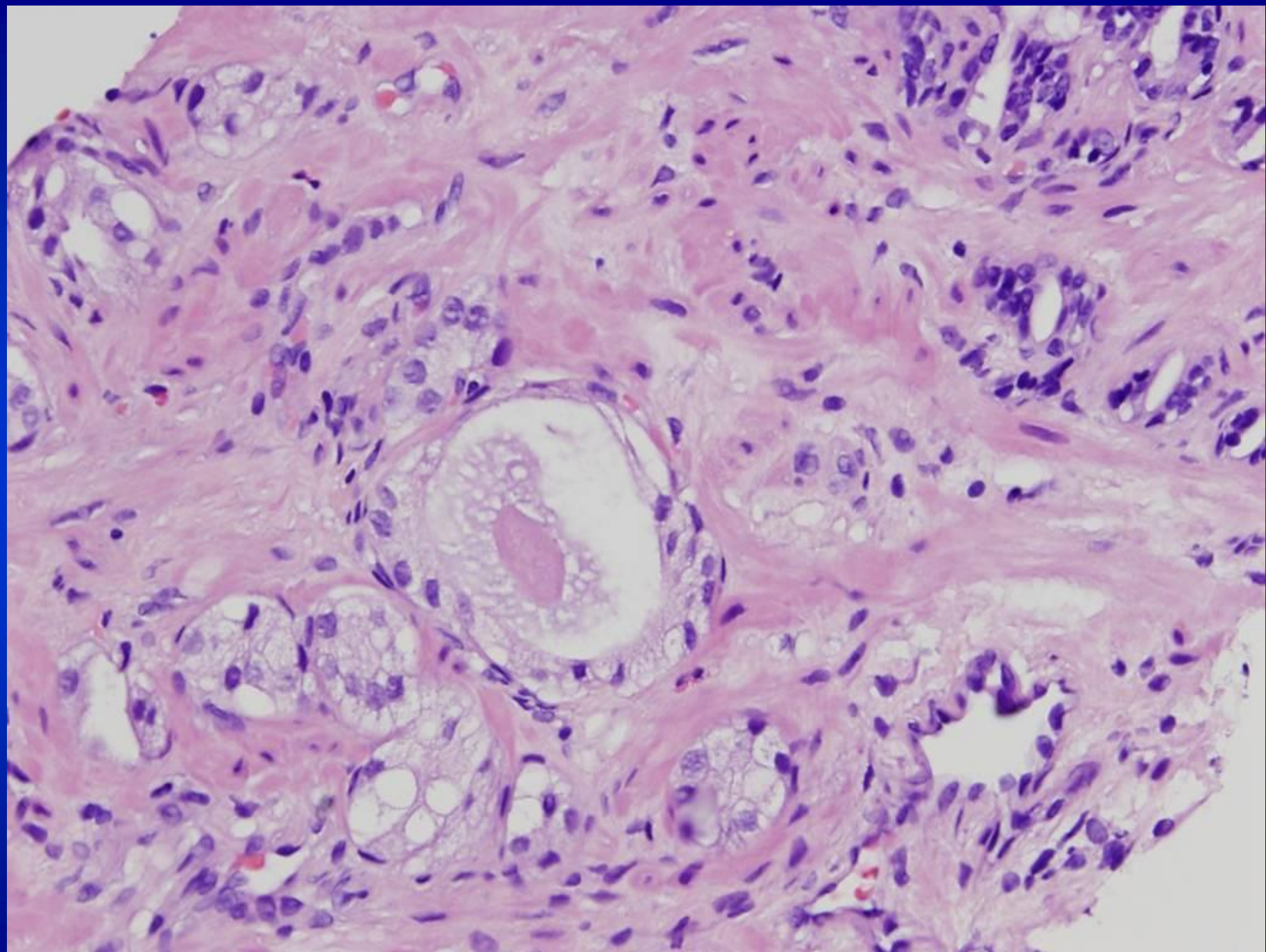


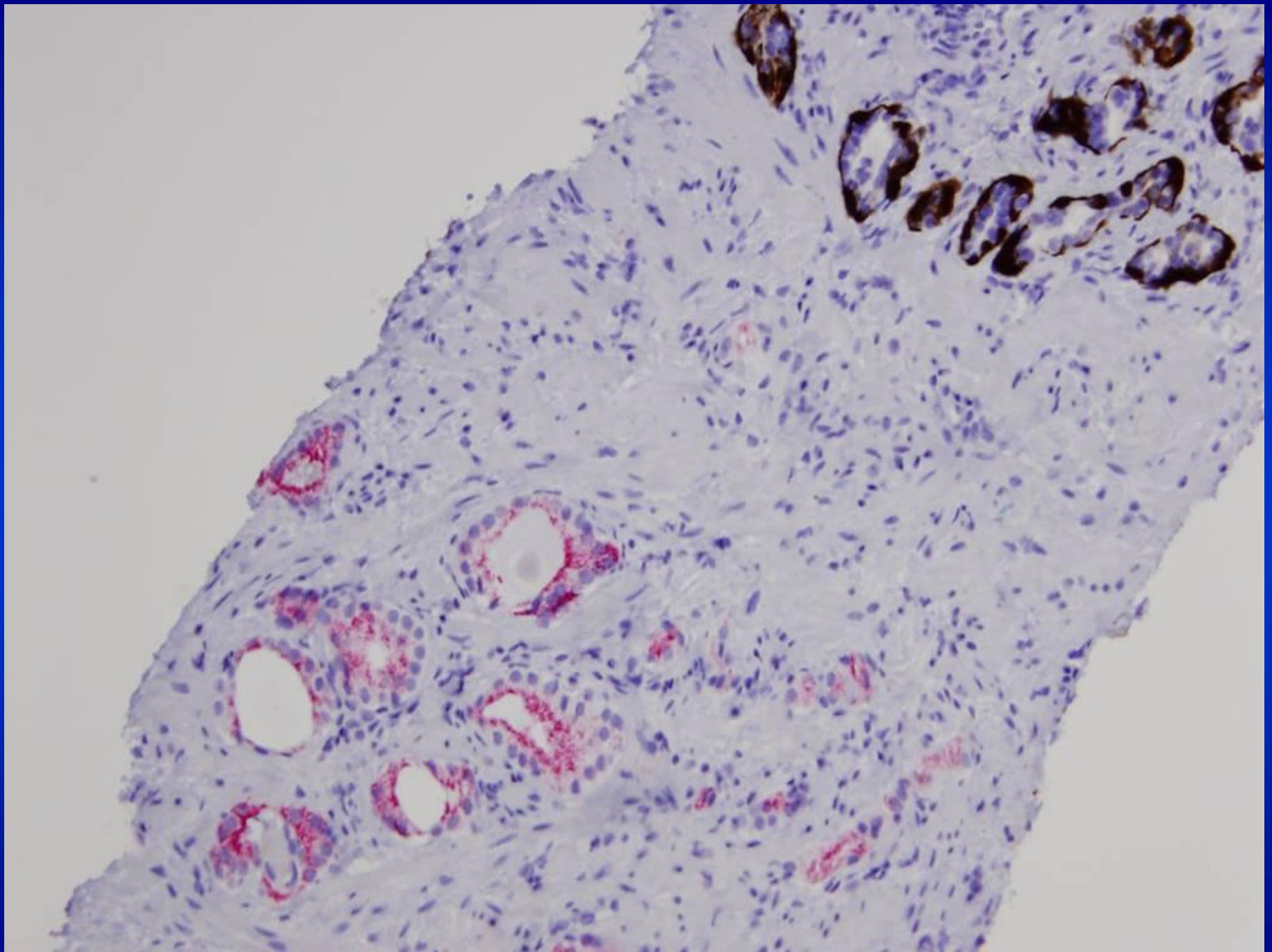


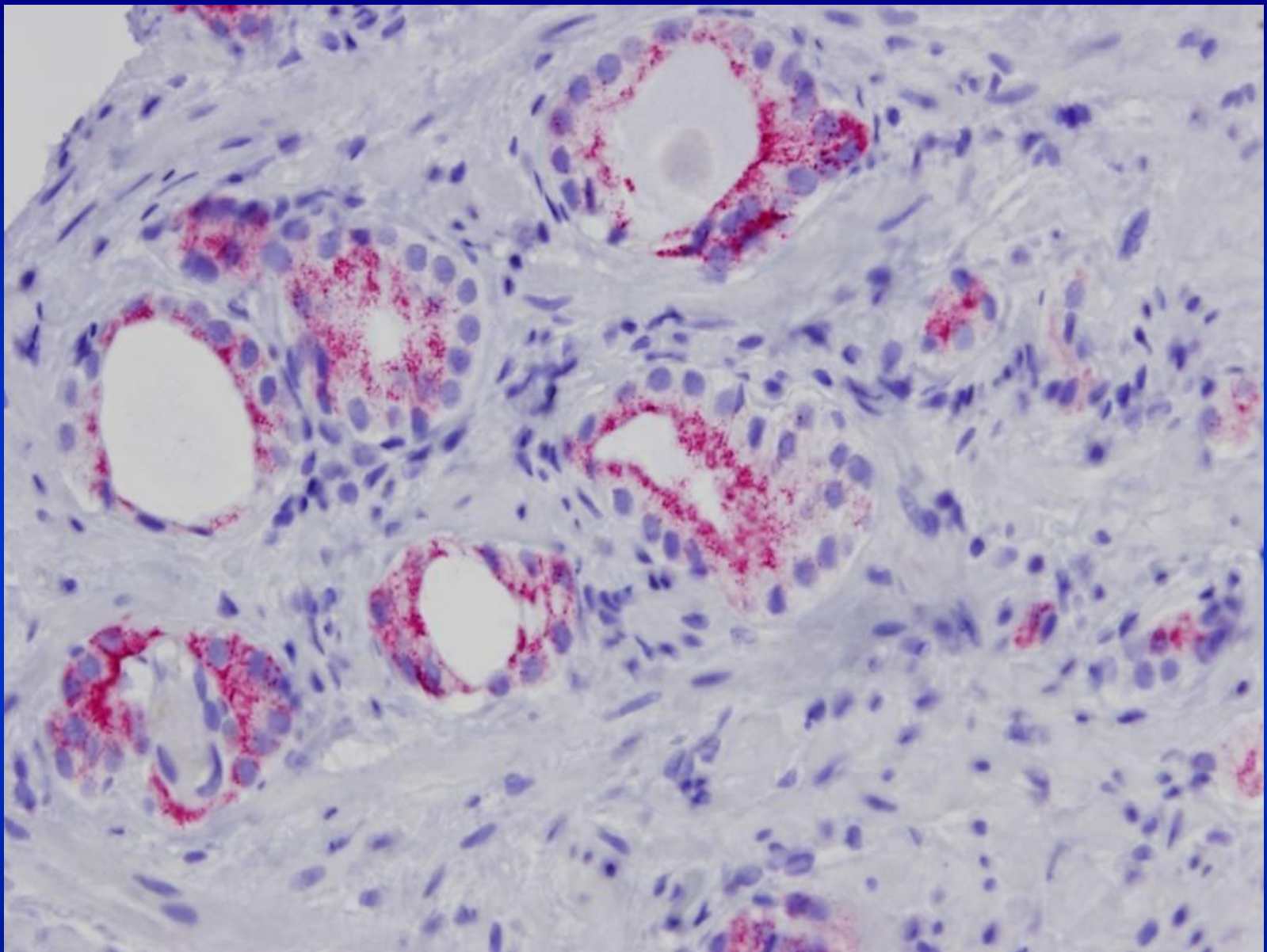




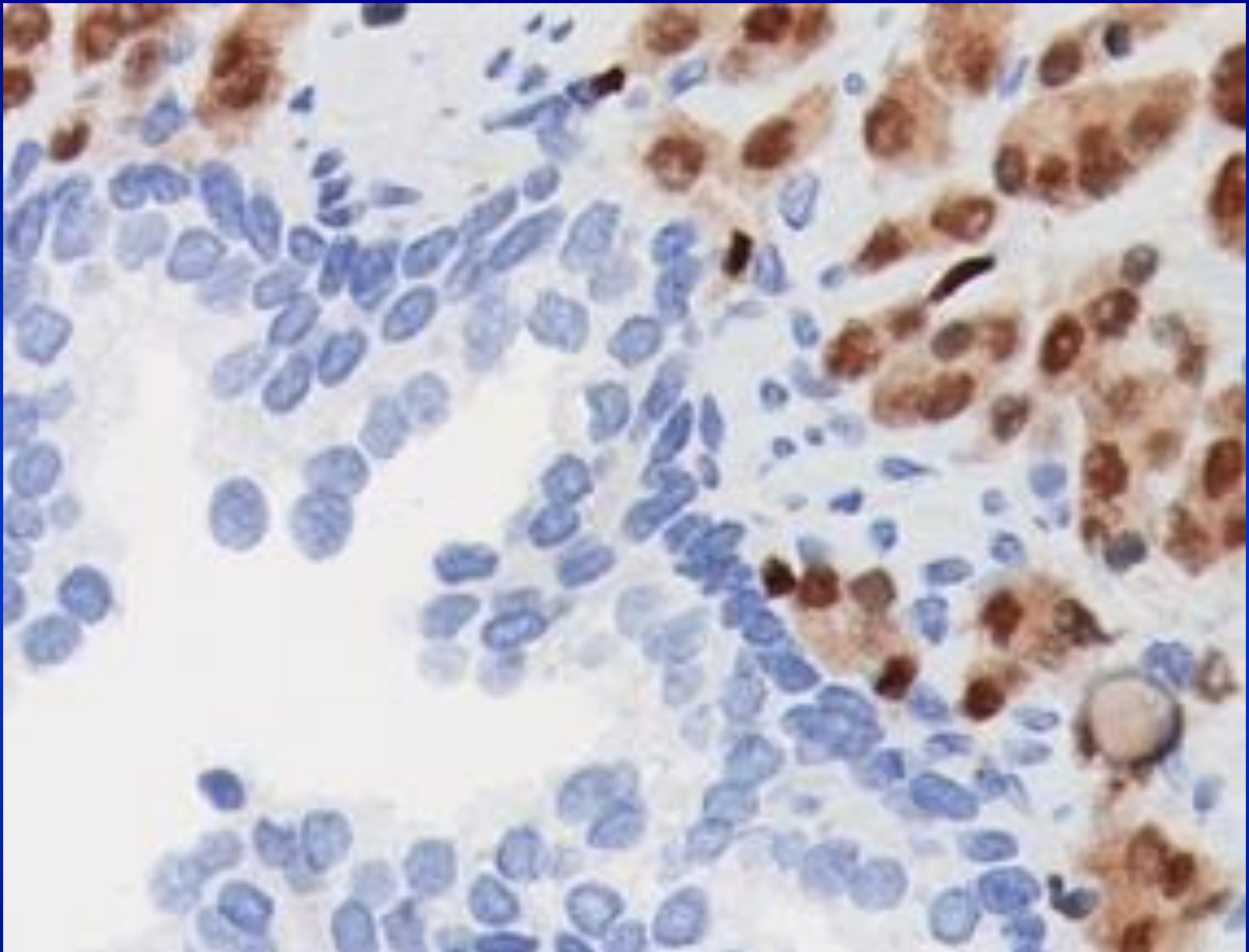








**AMACR expression in ASAP c > s cancer;  
USCAP abstract 2011, #982**



***TMPRSS2:ERG* fusion (erg immunostain) in ASAP  
USCAP abstract 2011, #826**

# ASAP

- **ASAP is a valid diagnostic category**
- **Clinical significance: predictive value for cancer on repeat biopsy**
- **ASAP predicts cancer : 34% to 60%**
- **Repeat biopsy and close clinical follow up**



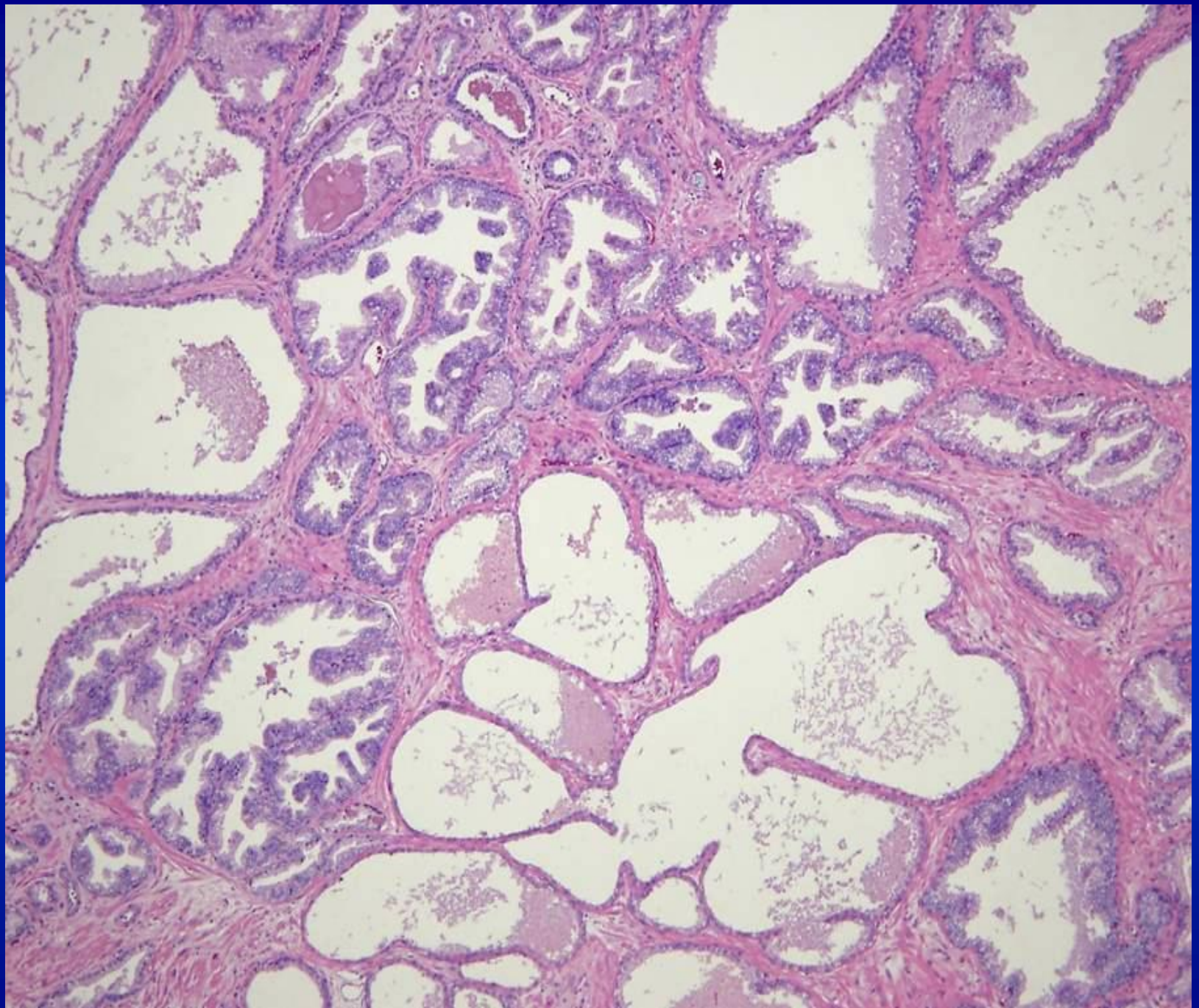
# Precancerous Lesions

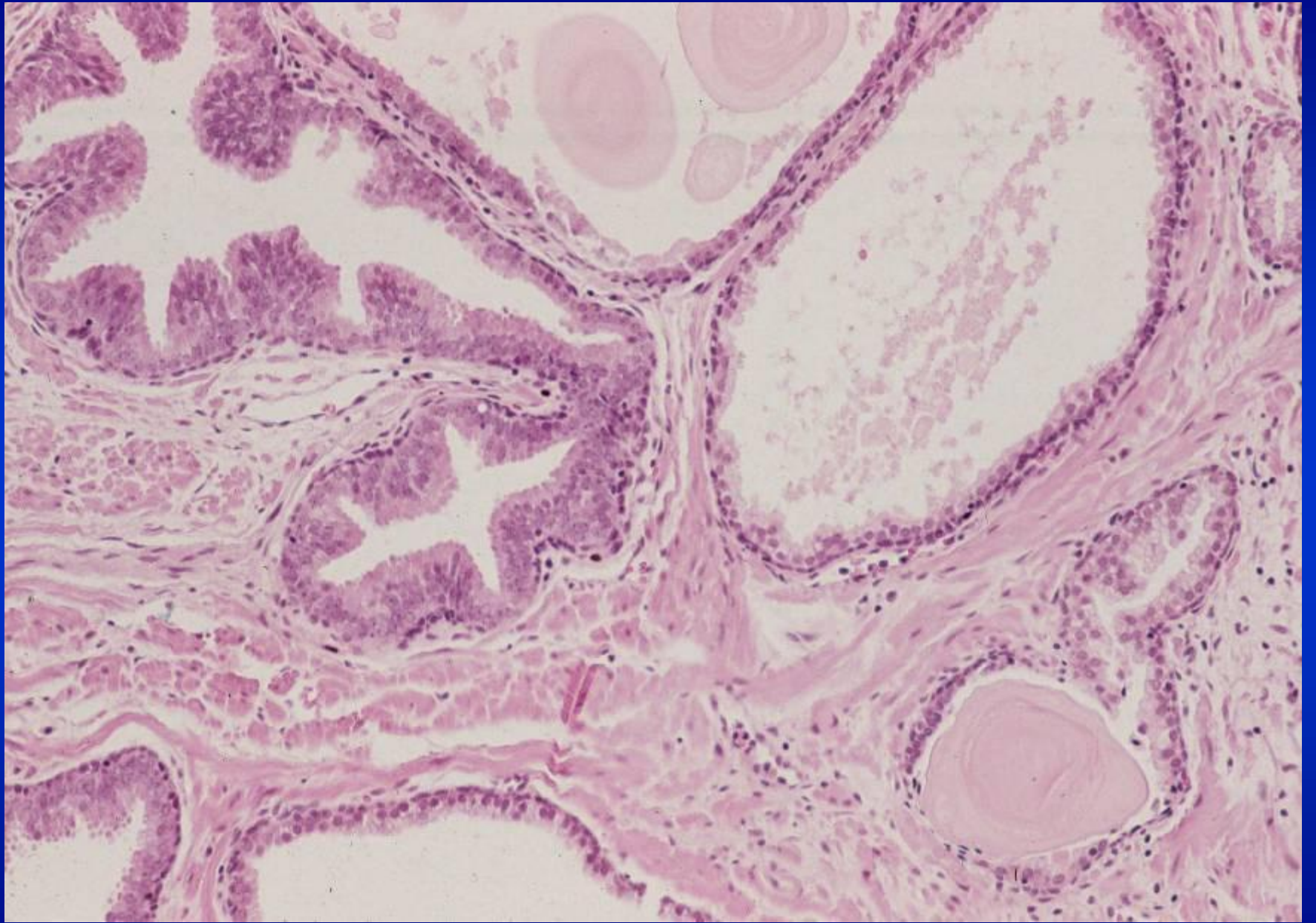
- **PIN:**

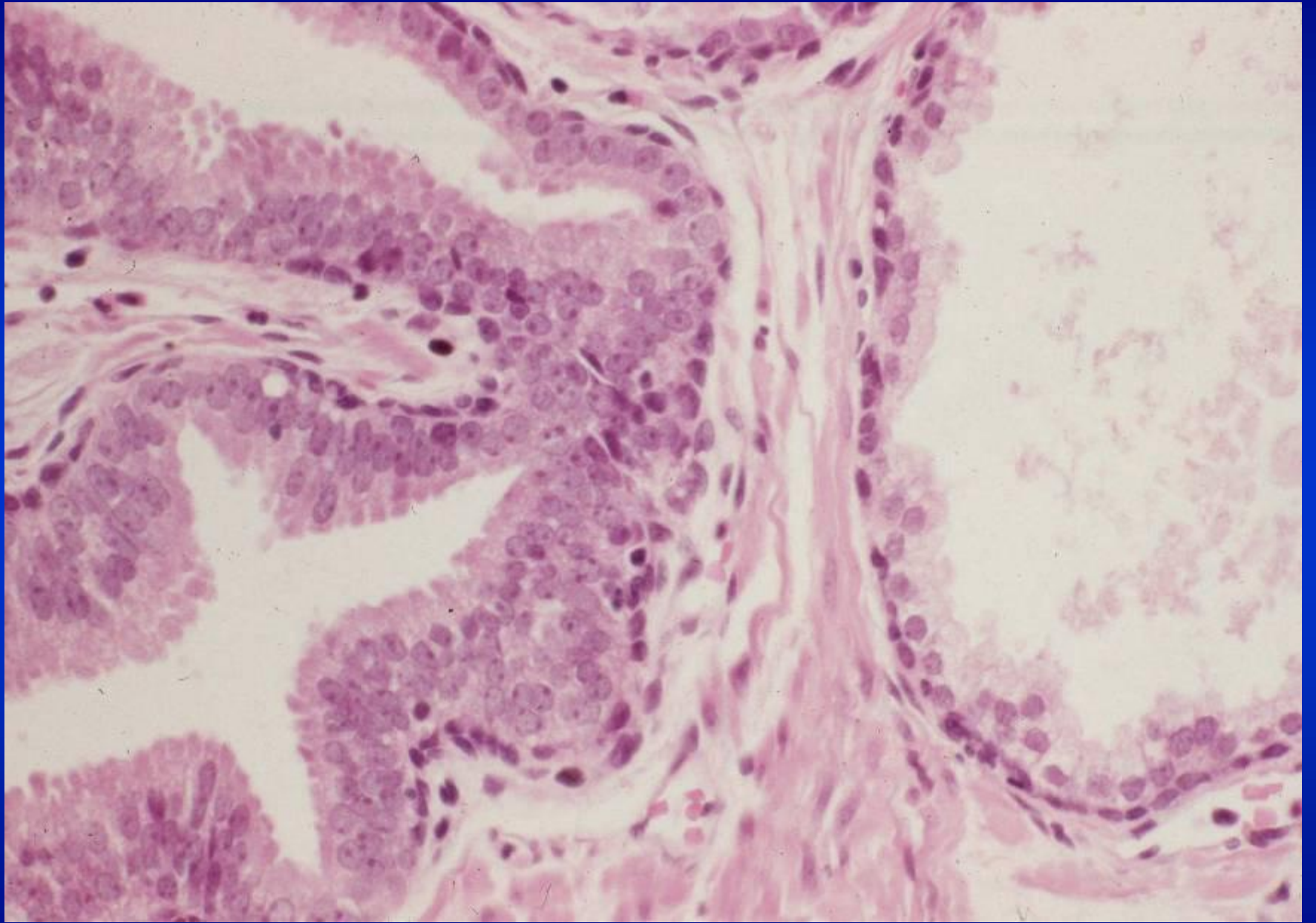
**Architecturally normal, but cytologically abnormal**

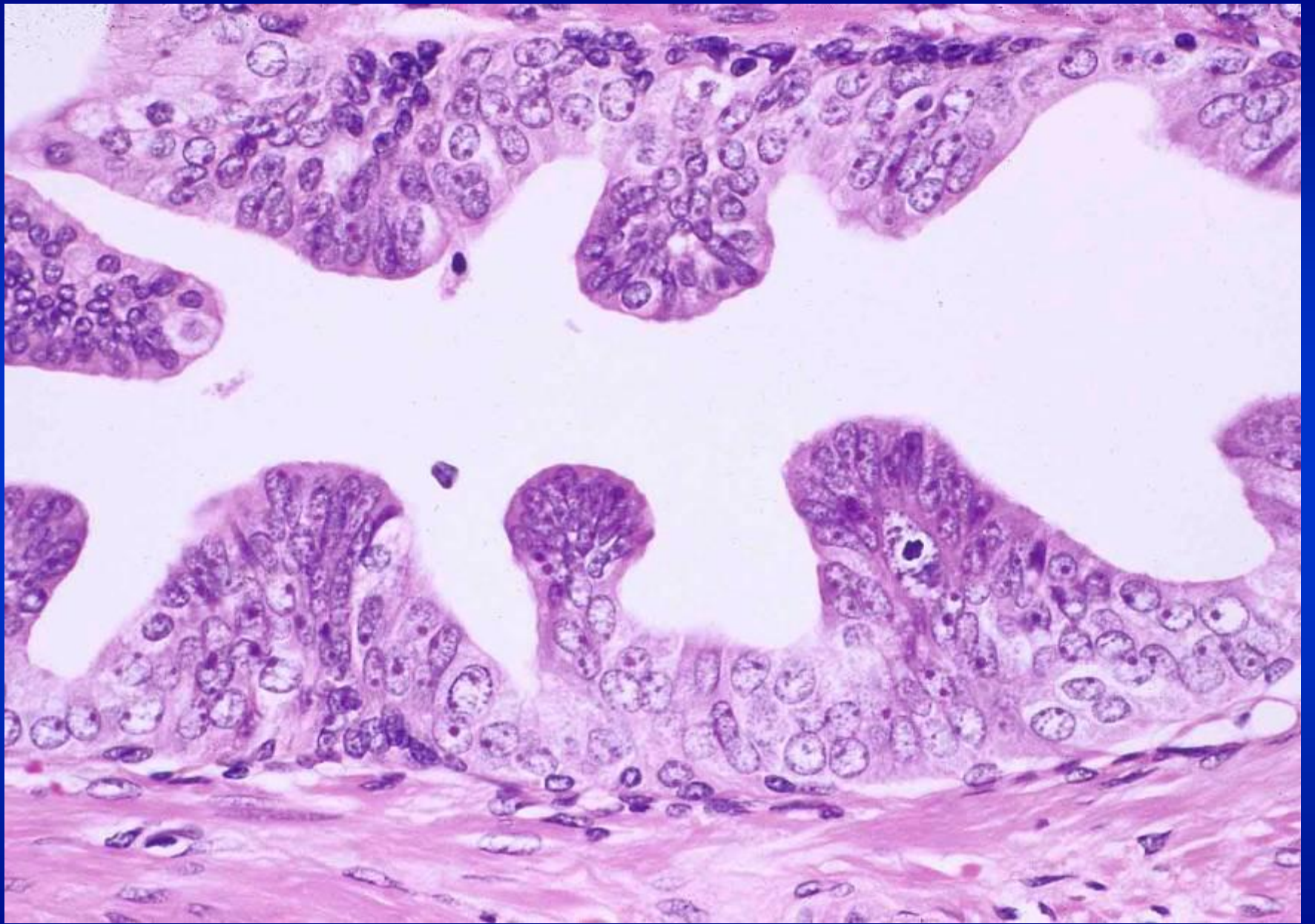
- **AAH:**

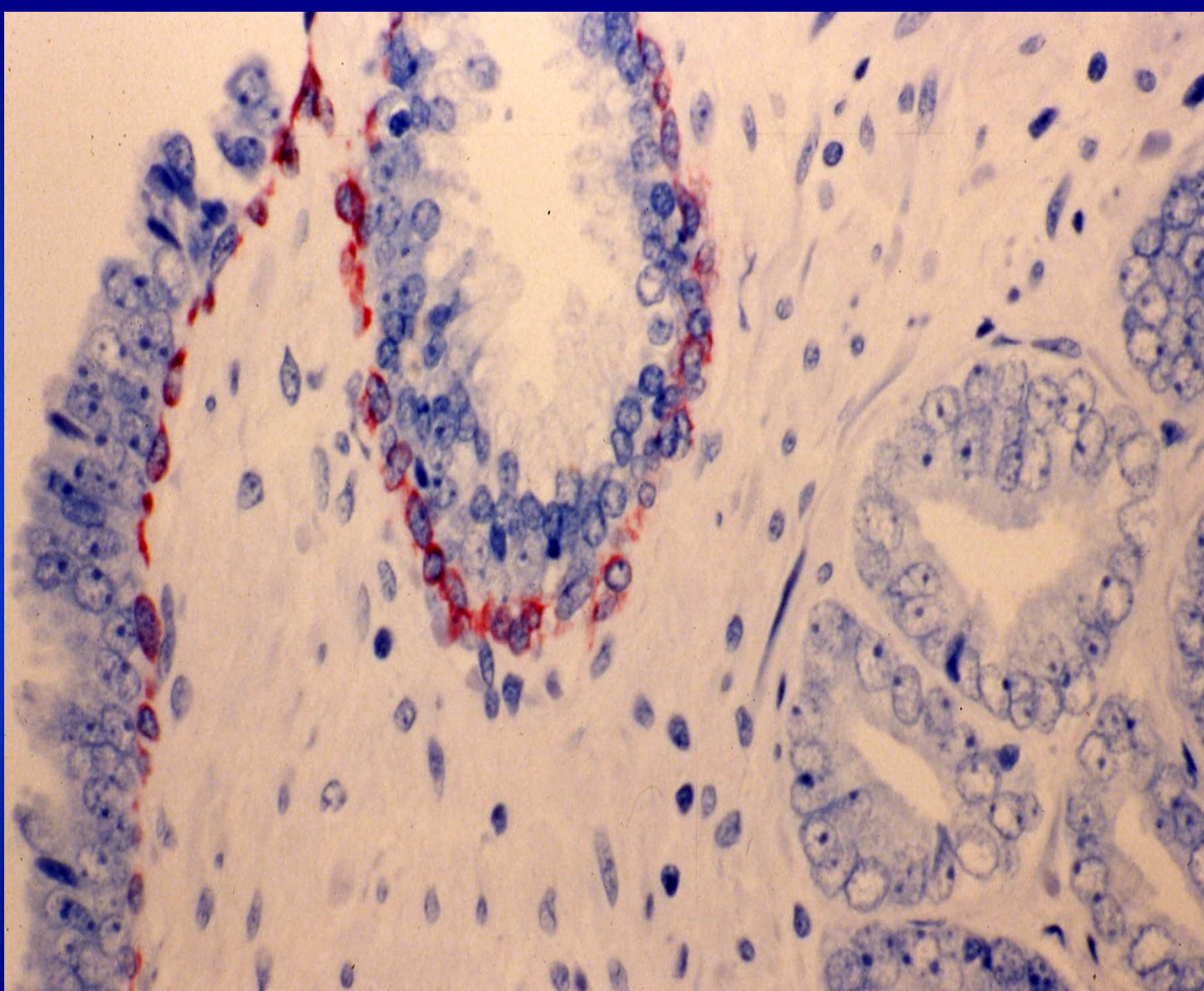
**Architecturally abnormal, but cytologically normal**





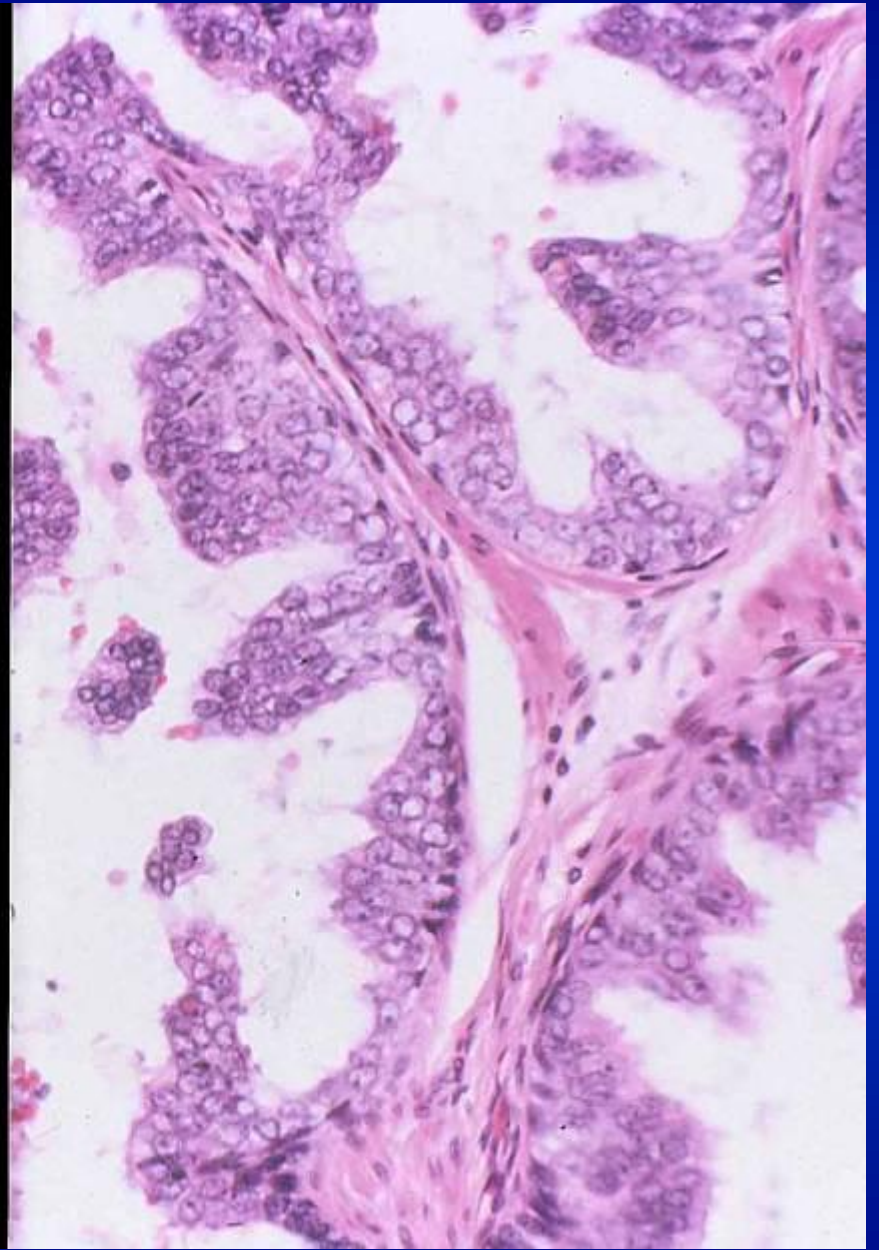
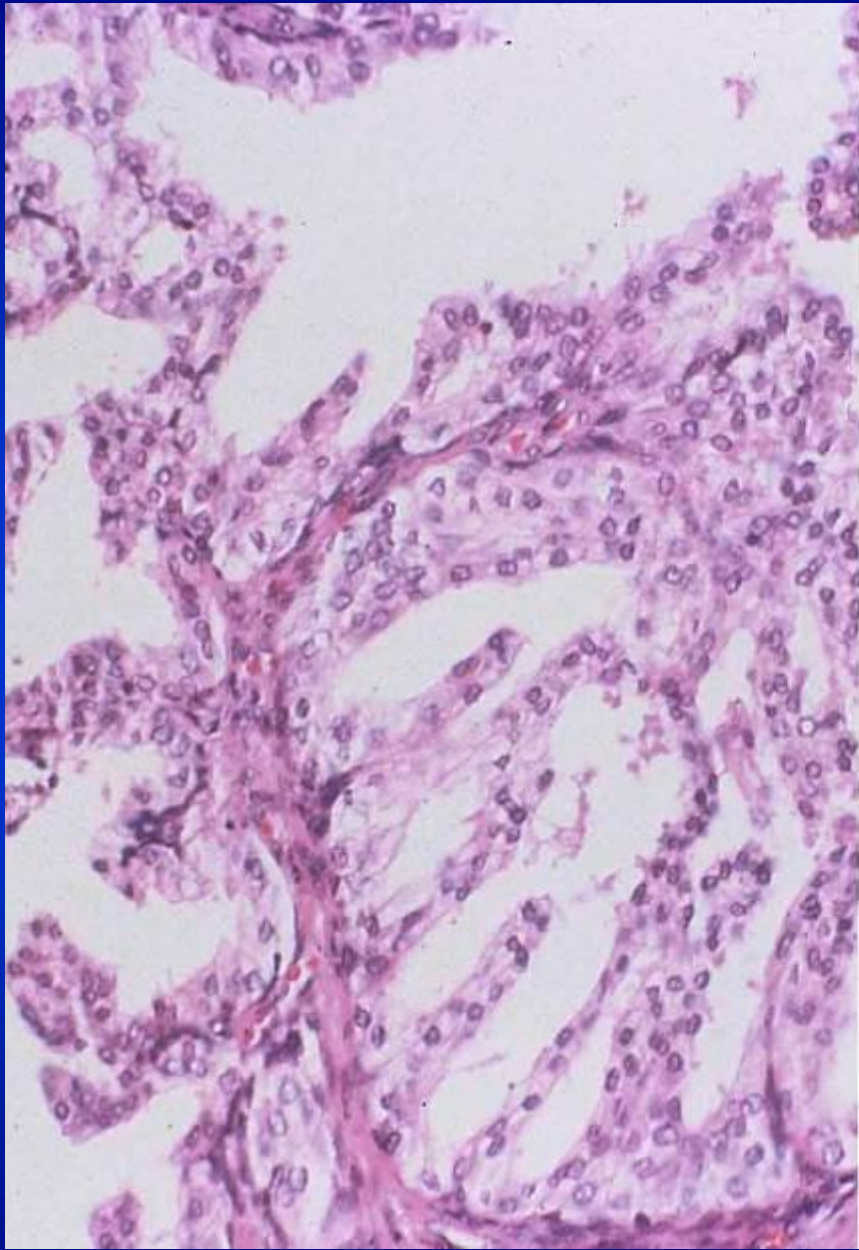






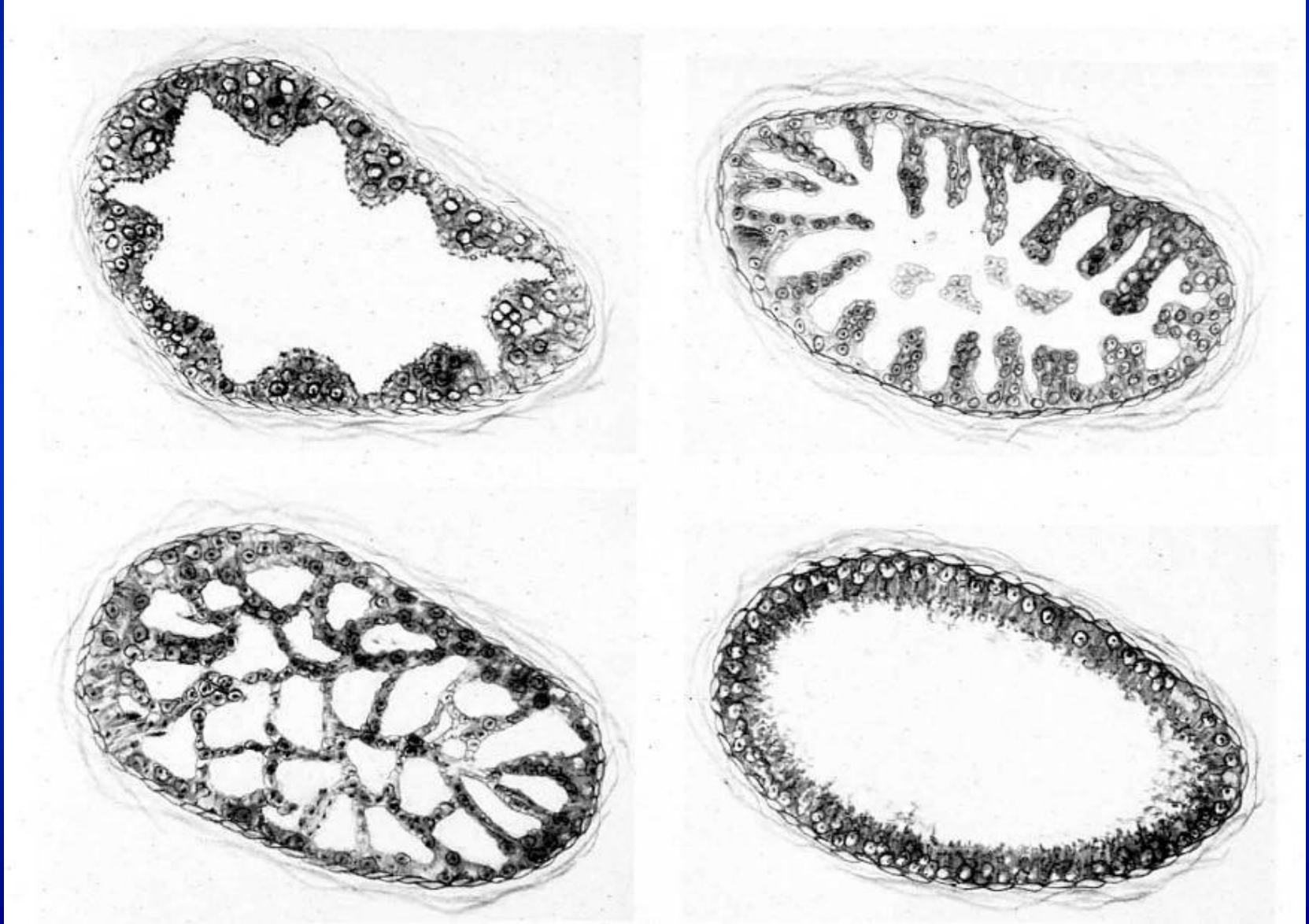
# Diagnostic Criteria of PIN

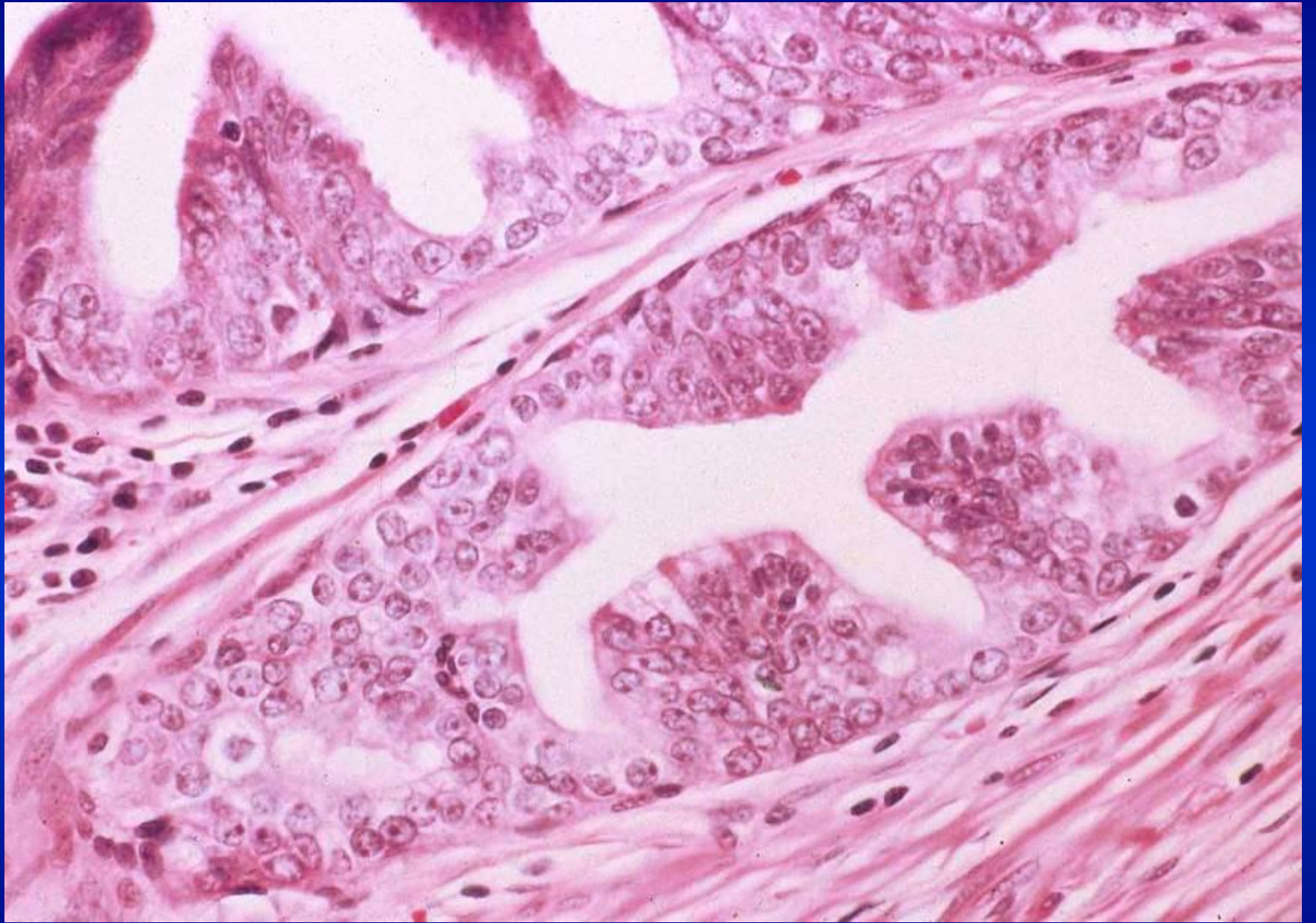
	<b>Low-grade PIN (PIN 1)</b>	<b>High-Grade (PIN 2 &amp; 3)</b>
<b>Patterns</b>	<b>Crowding, stratification, irregular spacing</b>	<b>More Changes, 4 patterns T, MP, crib, flat</b>
<b>Nuclei</b>	<b>Sl. enlarged, size variation</b>	<b>Enlarged, less size variation</b>
<b>Chromatin</b>	<b>Normal</b>	<b>Increased</b>
<b>Nucleoli</b>	<b>Rarely prominent</b>	<b>Occ. to freq. prominent</b>

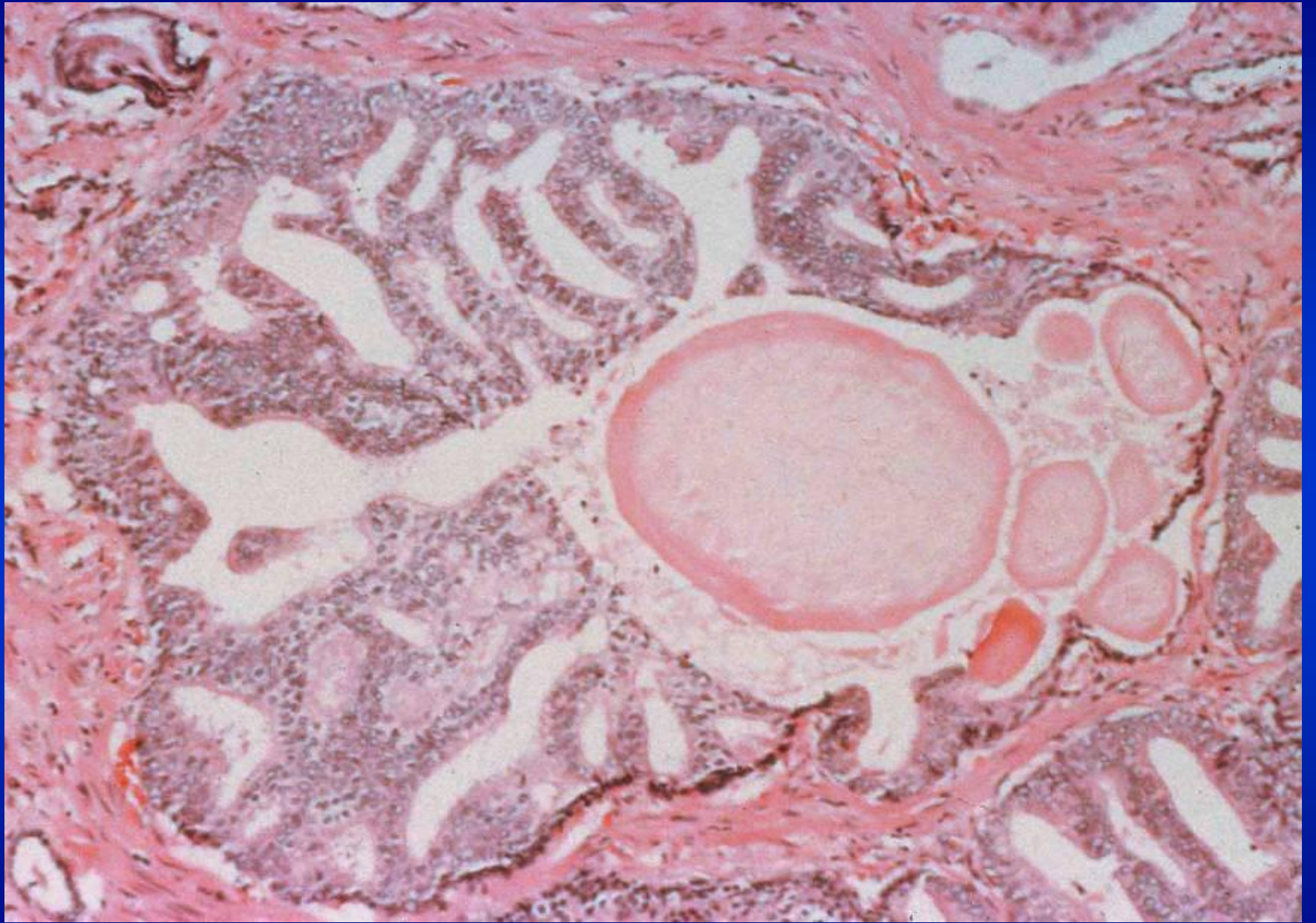


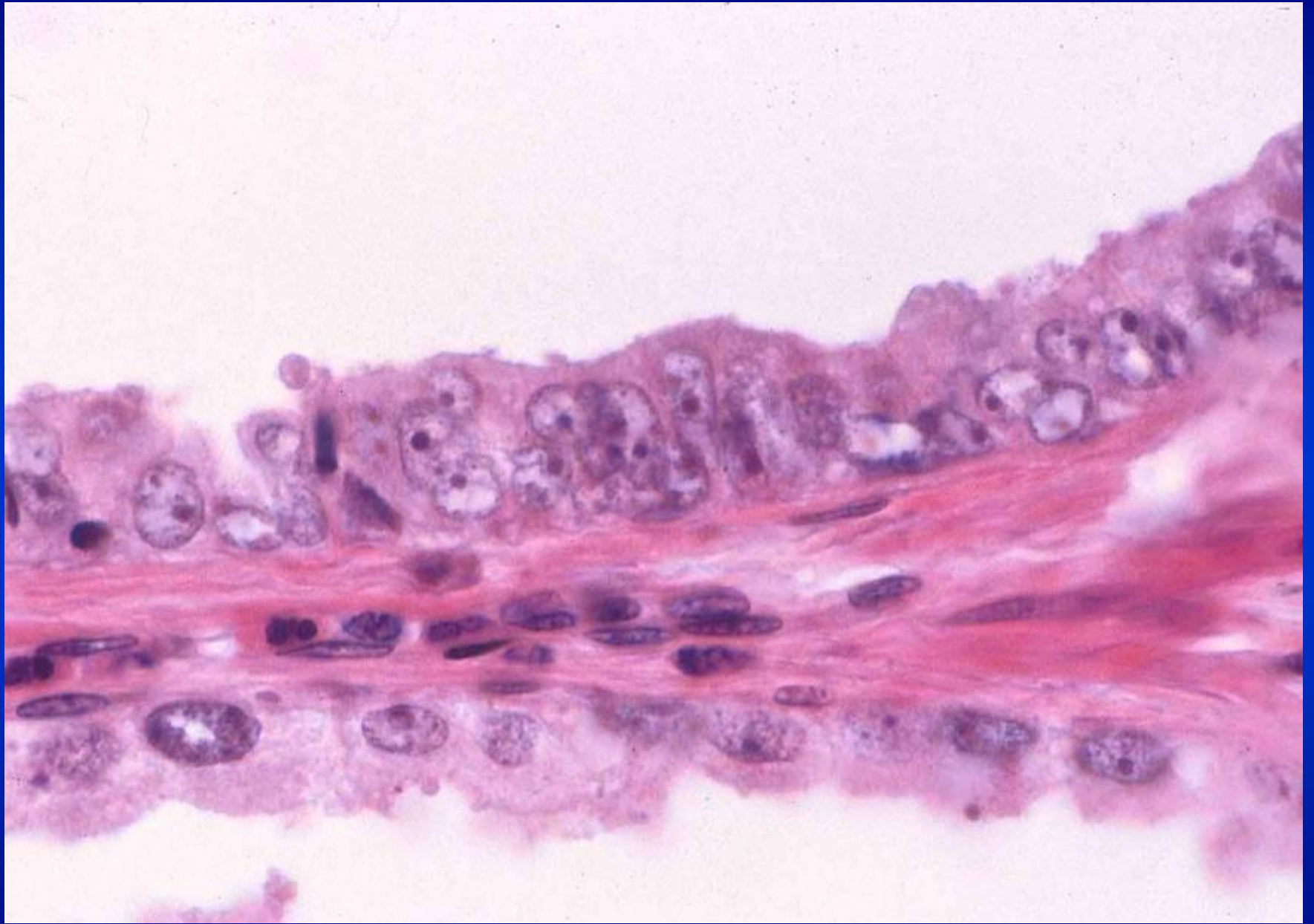
# Architectural patterns of PIN:

Bostwick and Amin Hum Pathol 24:298, 1993

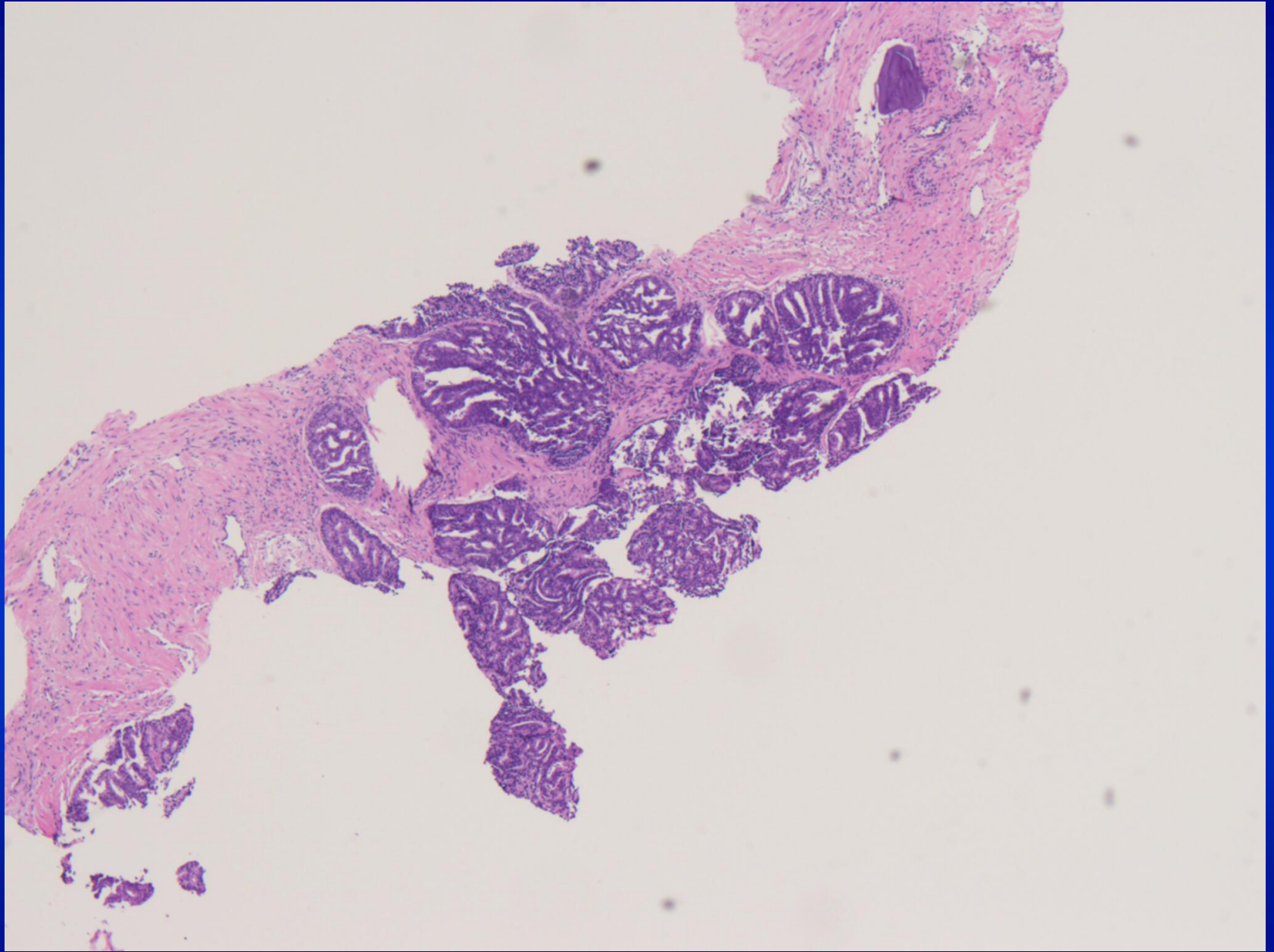


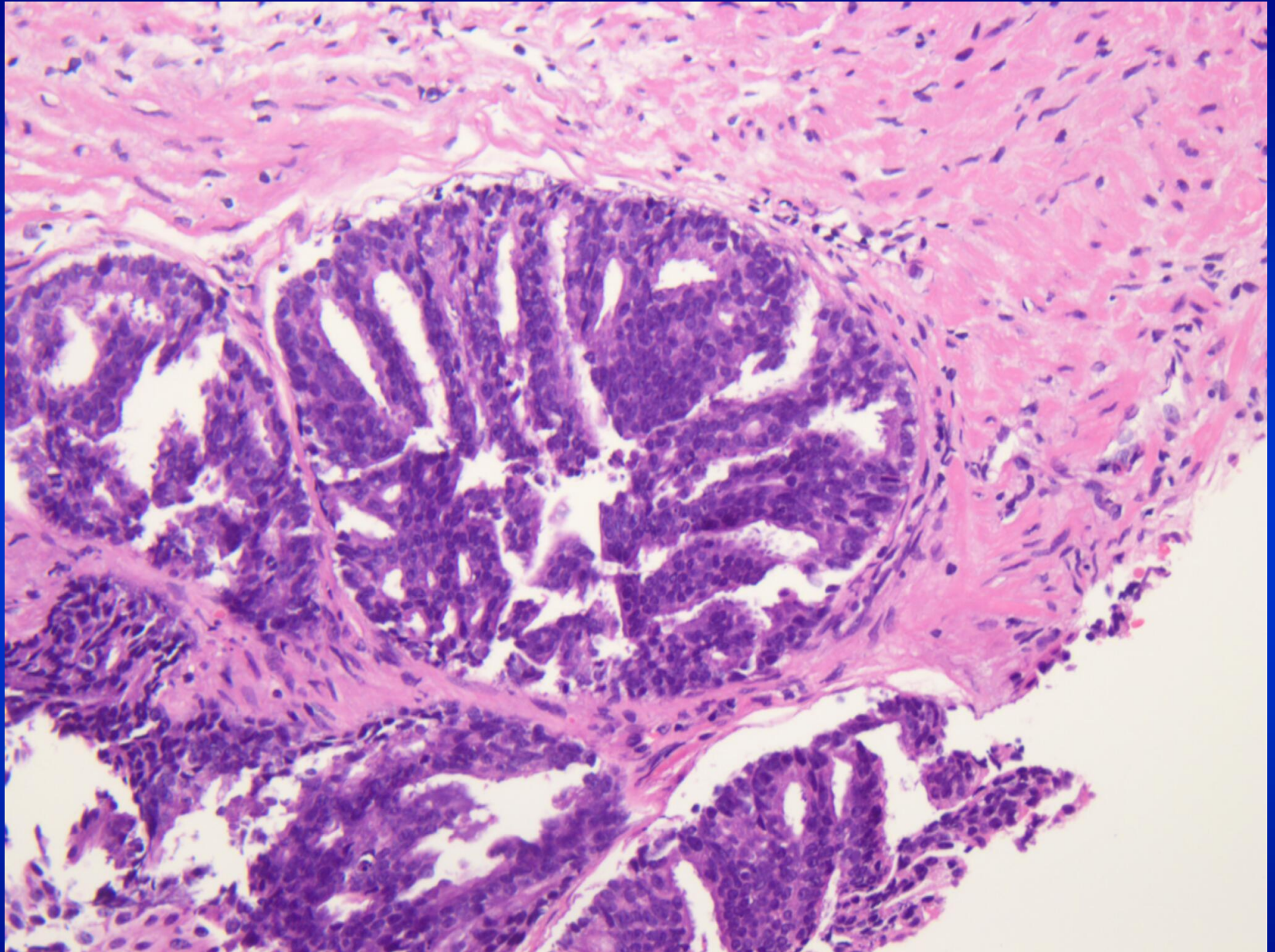


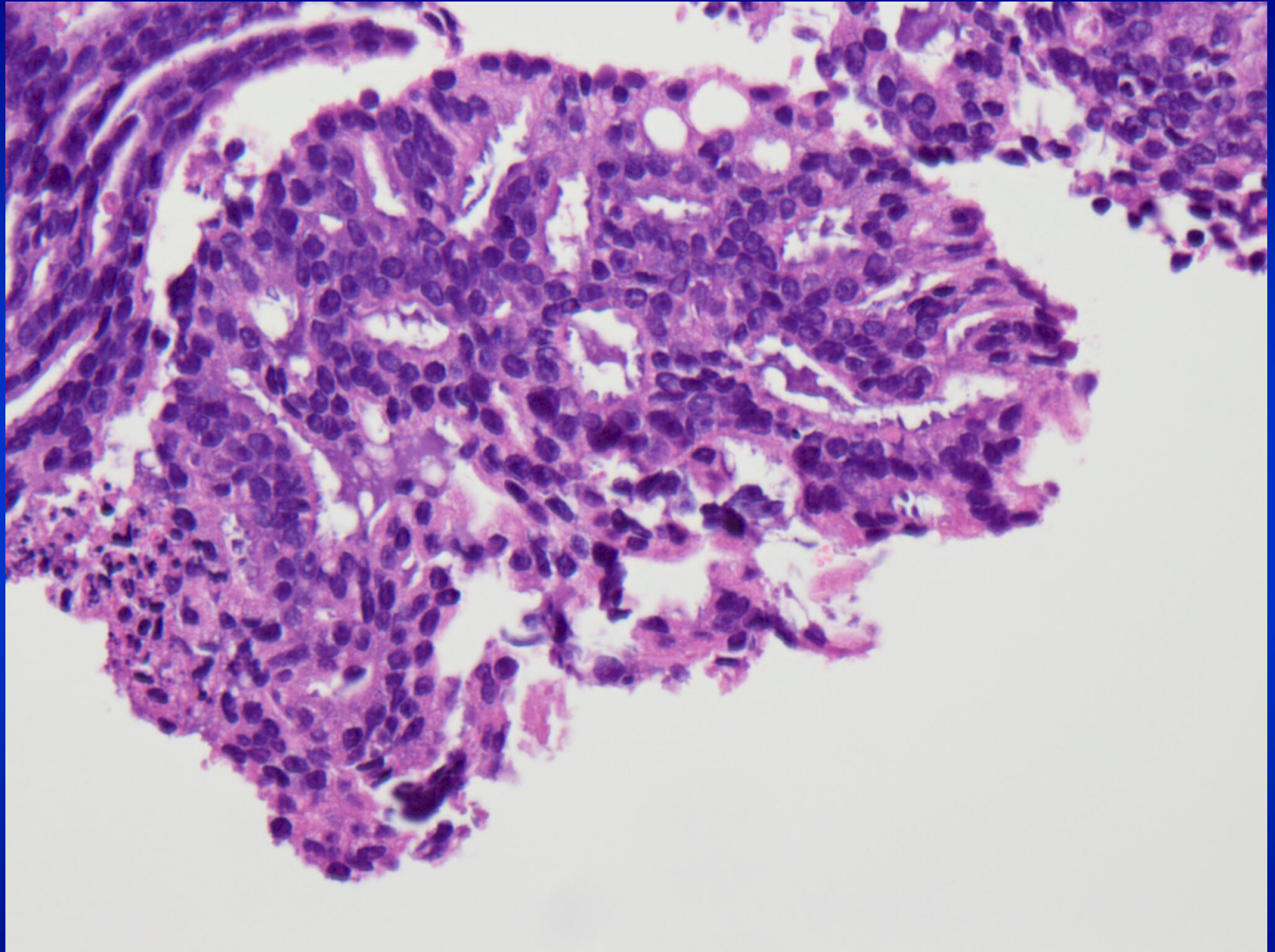


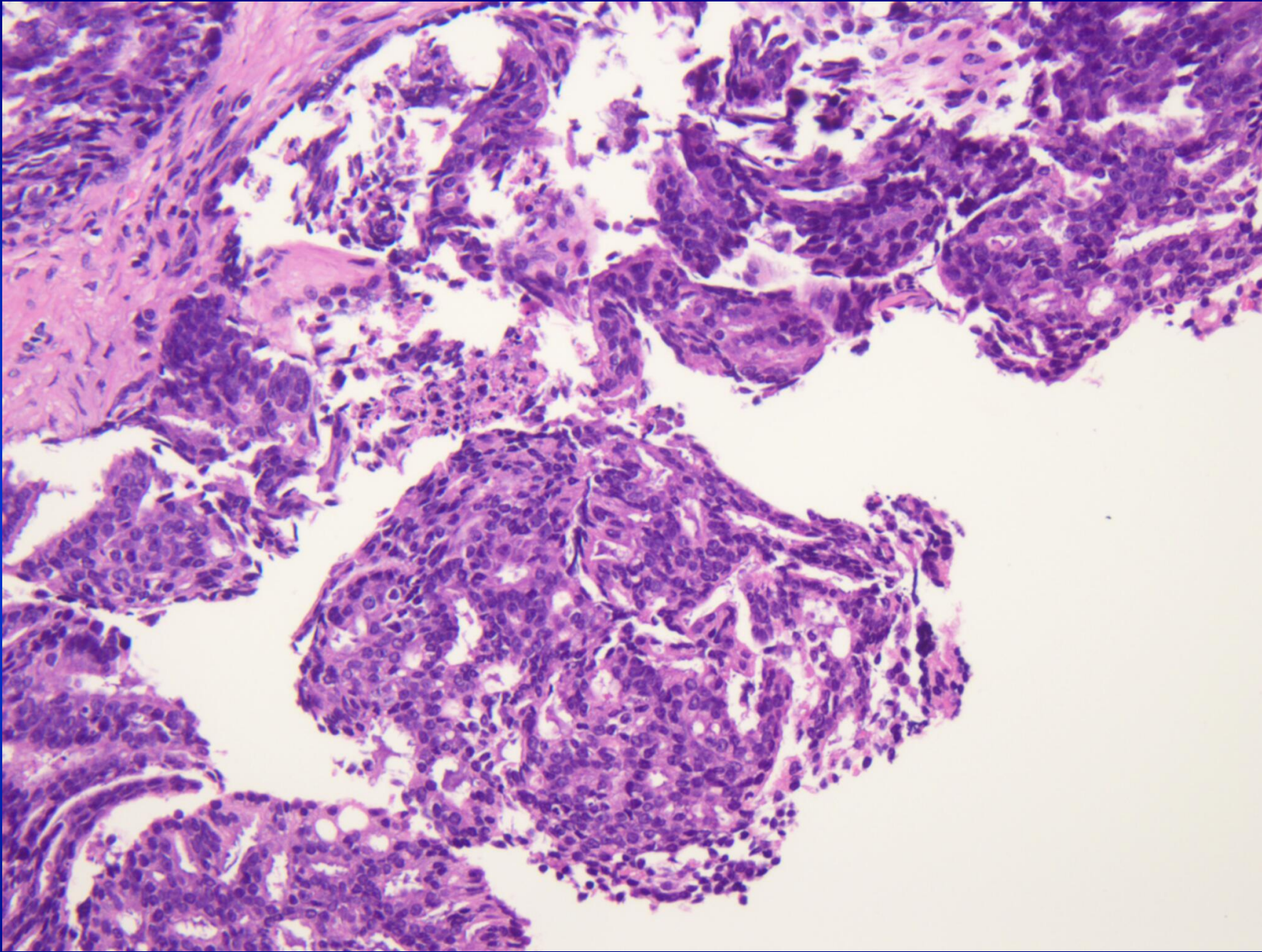


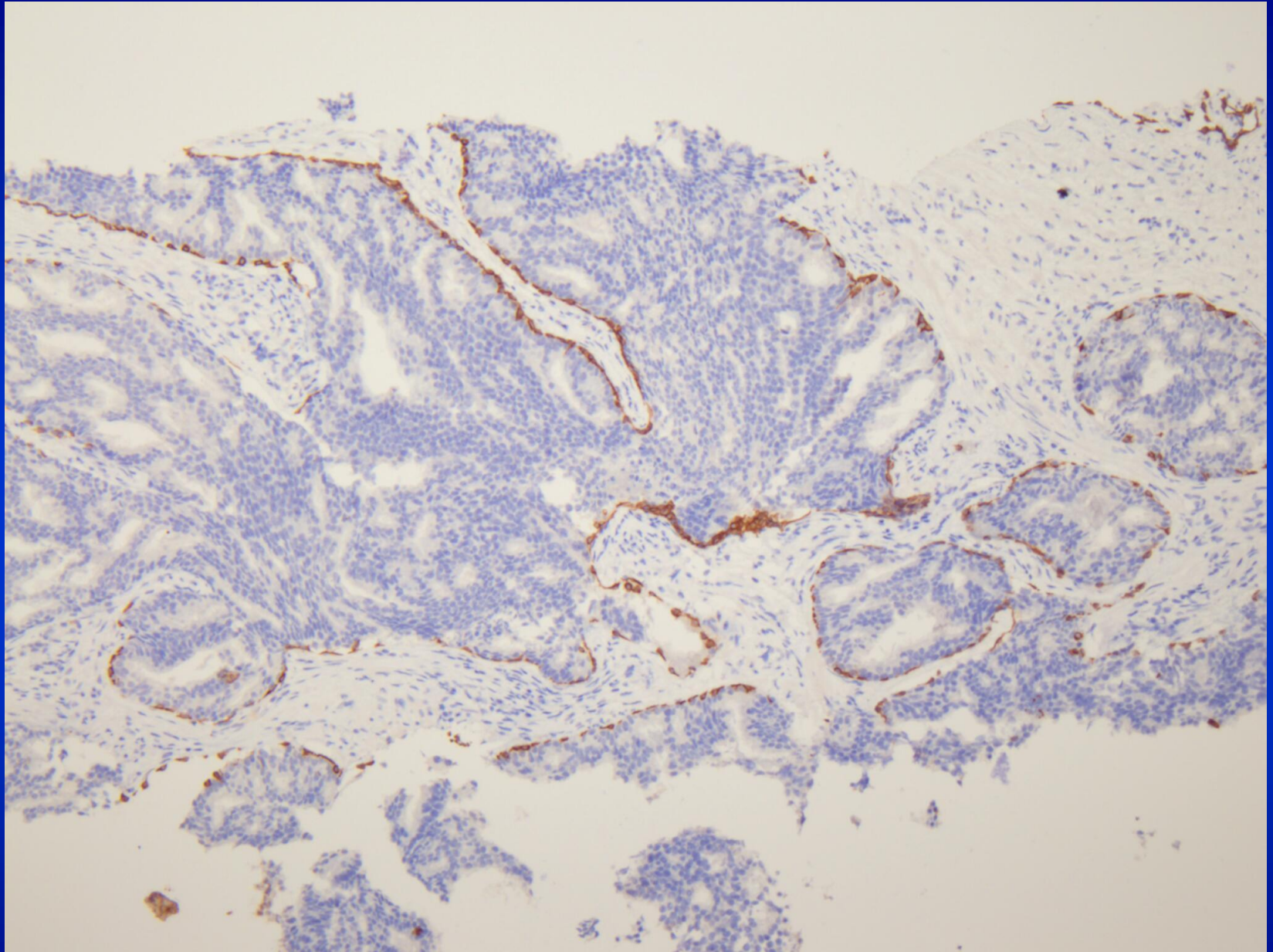
# Intraductal carcinoma











# Intraductal carcinoma (IDC-P)

- McNeal & Yemoto, **AJSP 1996;20:802**
- Guo and Epstein, **2006, Mod Pathol 19:1528**
  - Epithelial cells filling large ducts/acinar with preservation of basal cells
    - 1) Solid or dense cribriform pattern
    - 2) Loose cribriform or micropapillary with marked cellular atypia (6 normal or larger) or presence of comedonecrosis
- Shah et al, **2010, AJSP, 34:470 (ACLs)**
  - > 6 glands with cribriform hyperplastic epithelium with pleomorphic nuclei, nucleomegaly and complex architecture (necrosis, solid architecture, or branching): > 1mm

---

**TABLE 3. Pathologic Features That Distinguish IDC-P From Cribriform HGPIN**

---

Pathologic Features Associated With IDC-P

No. glands ( $> 6$ )

Size ( $> 1$  mm)

Branching contour

Dense cribriform or solid architecture

Comedonecrosis

Nuclear size  $> 6 \times$  the size of adjacent nuclei or pleomorphic nuclei

---

HGPIN indicates high-grade prostatic intraepithelial neoplasia; IDC-P, intraductal carcinoma of the prostate.

---

# Atypical cribriform lesions

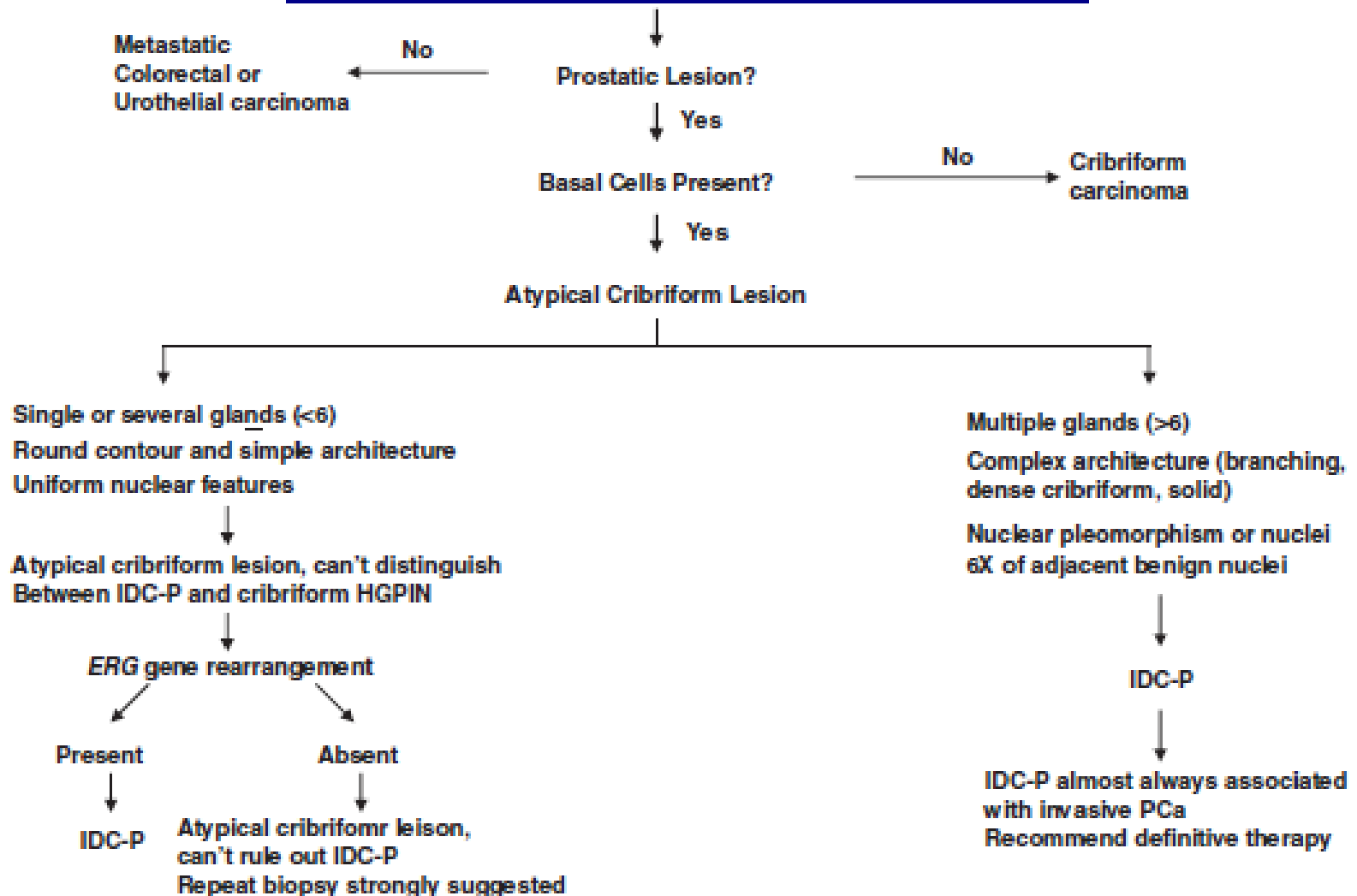
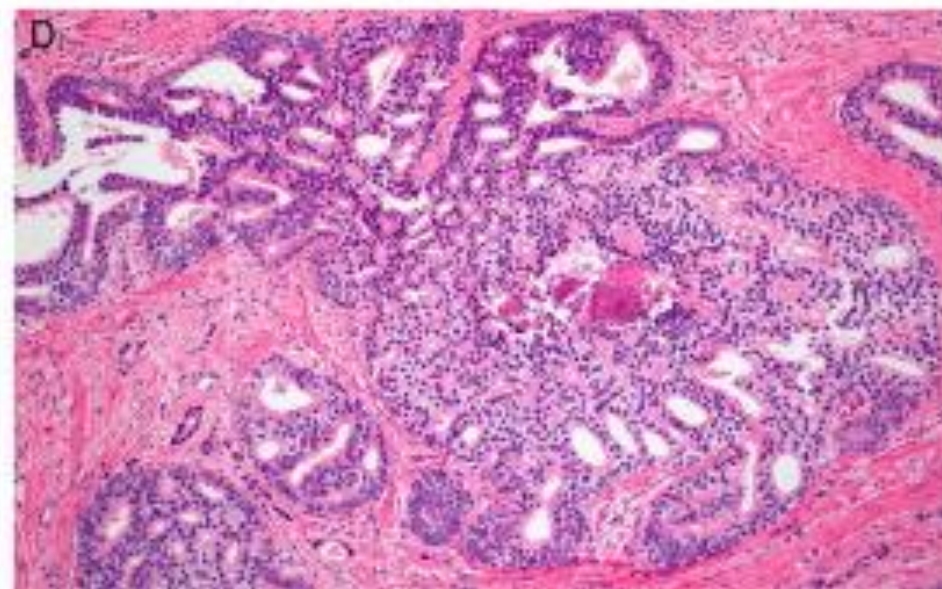
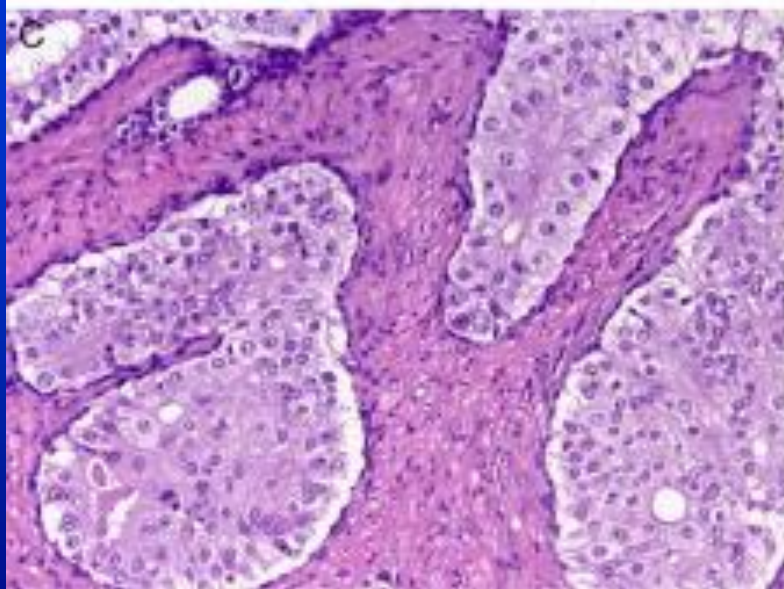
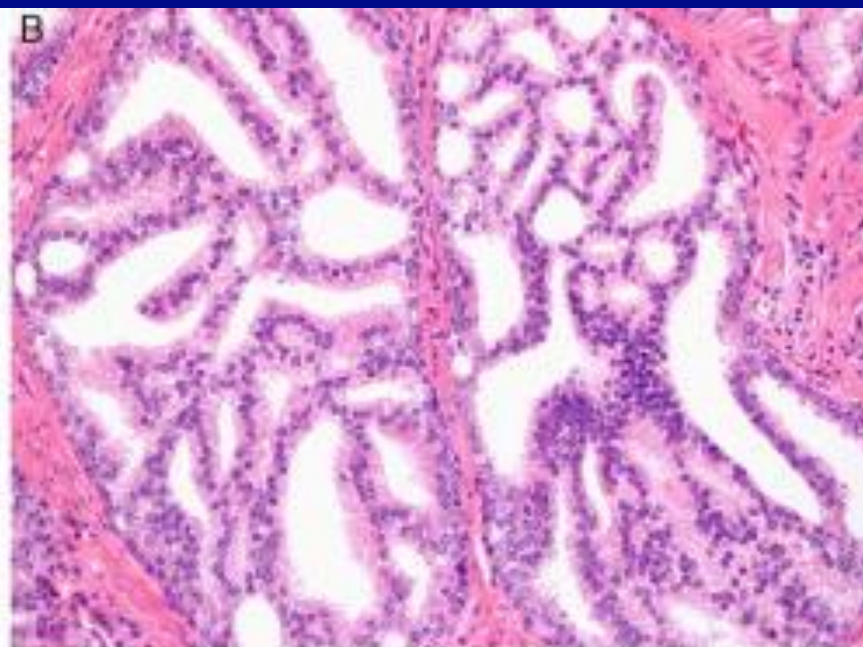
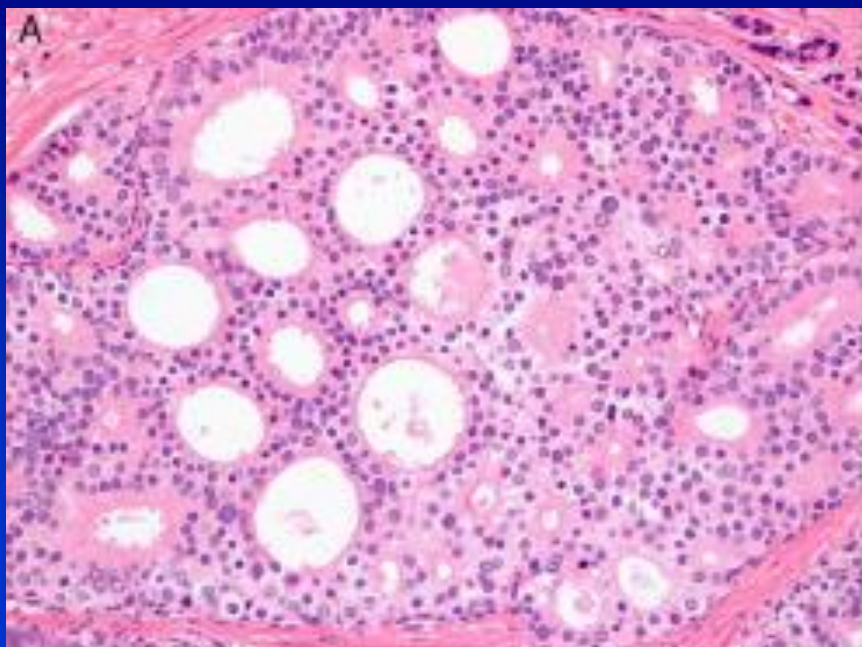
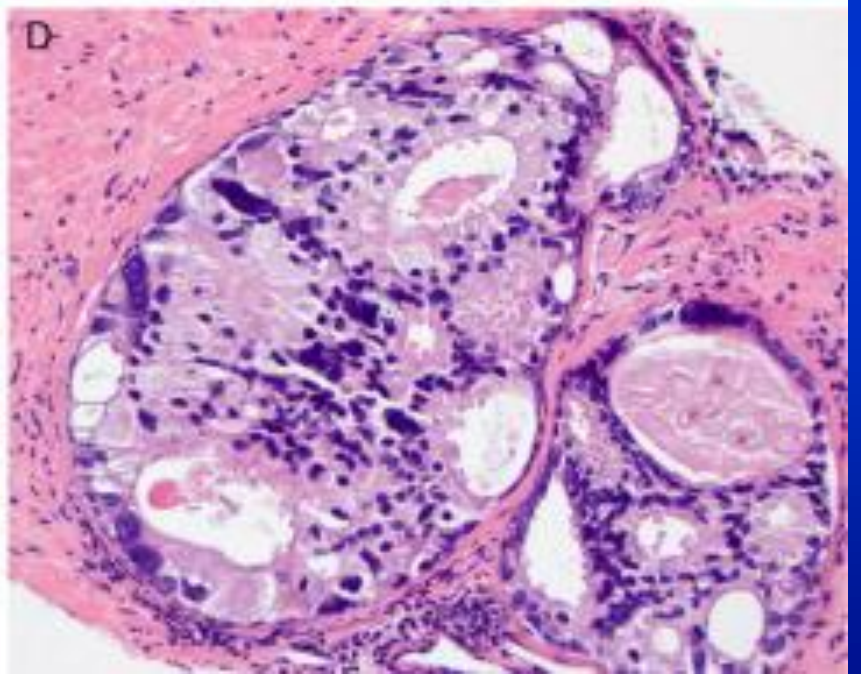
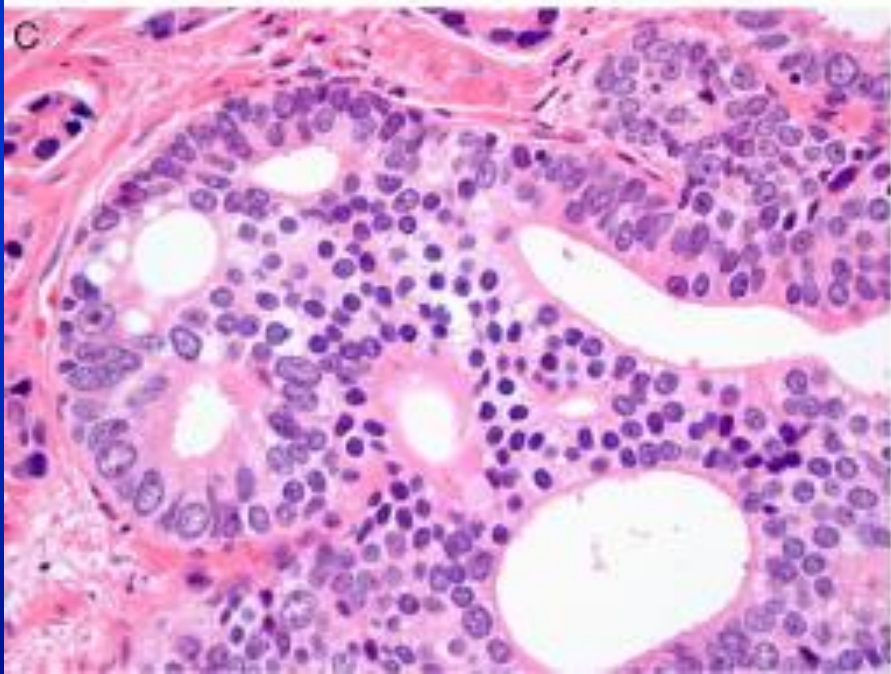
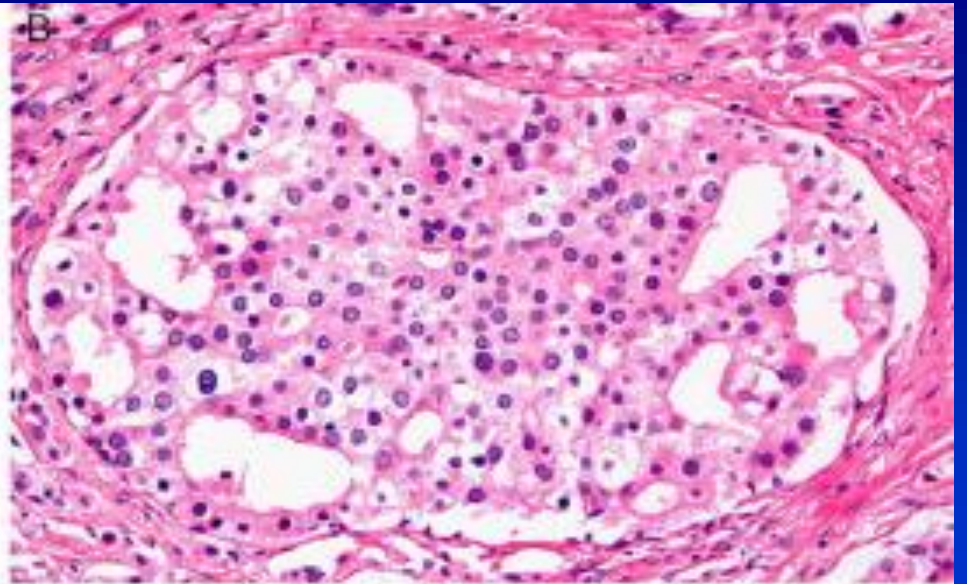
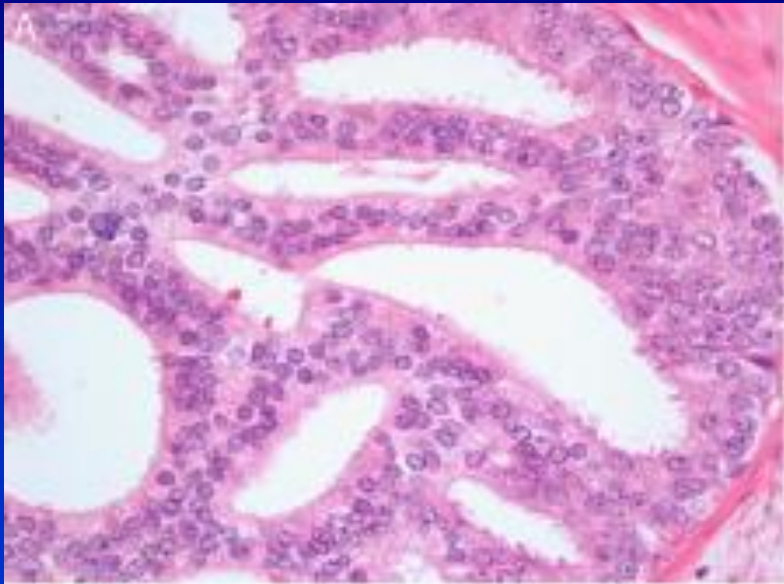
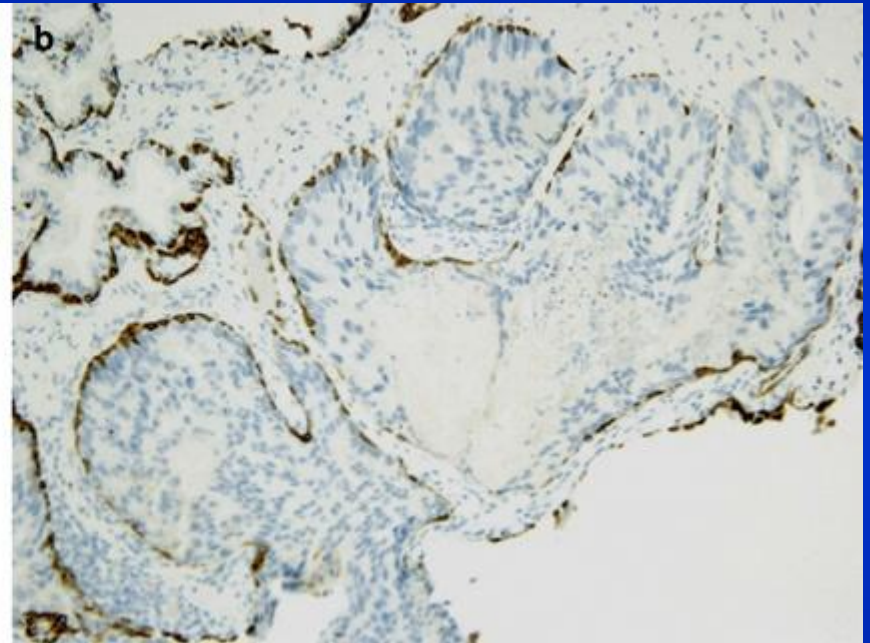
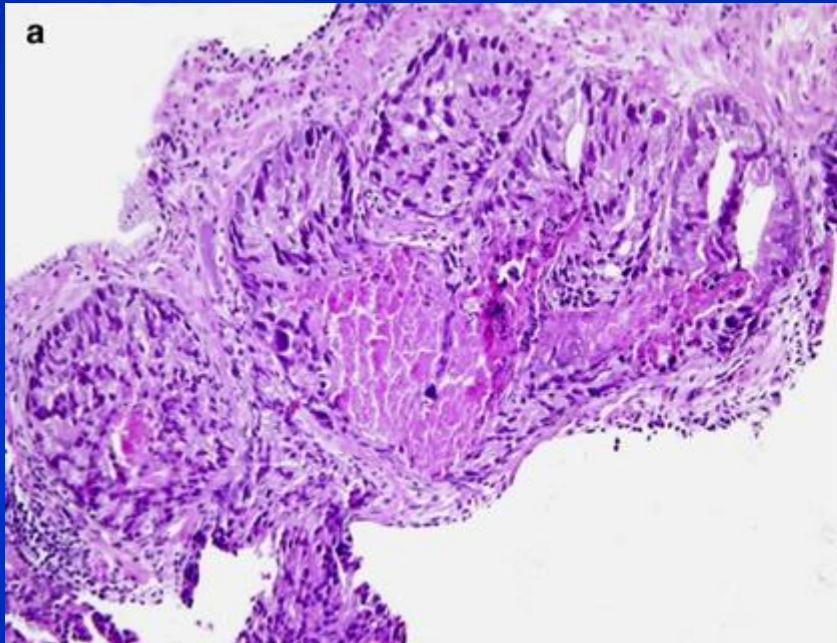


FIGURE 5. A diagnostic approach to the prostate biopsy containing atypical cribriform lesions.

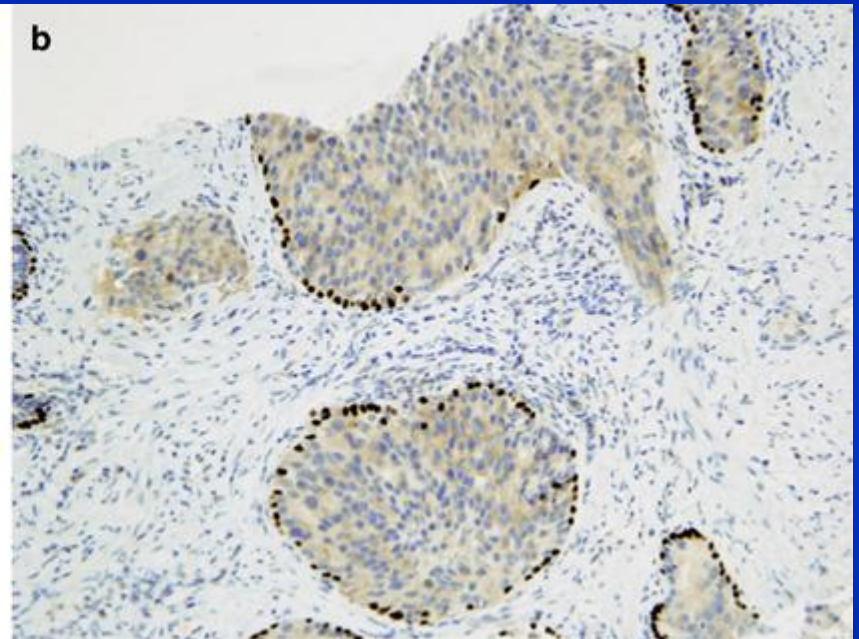
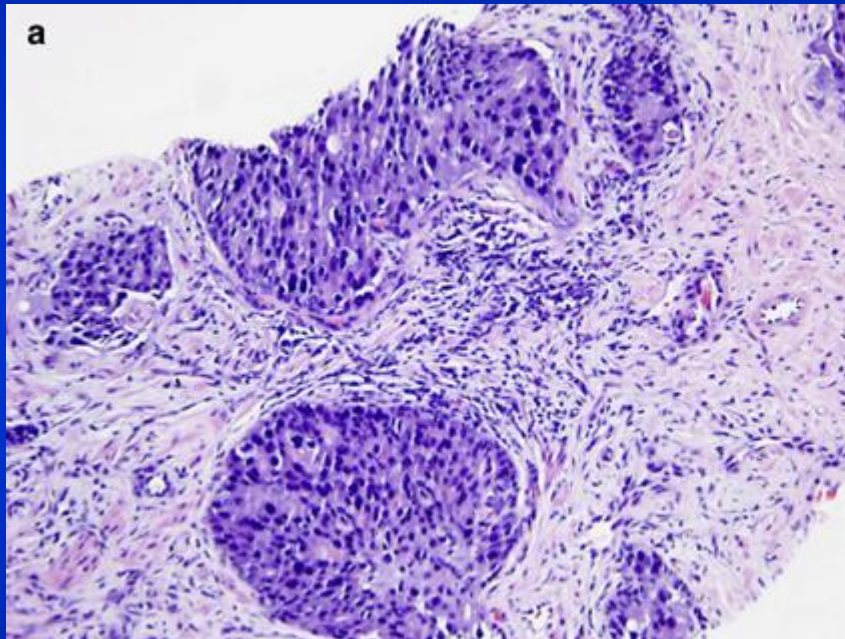




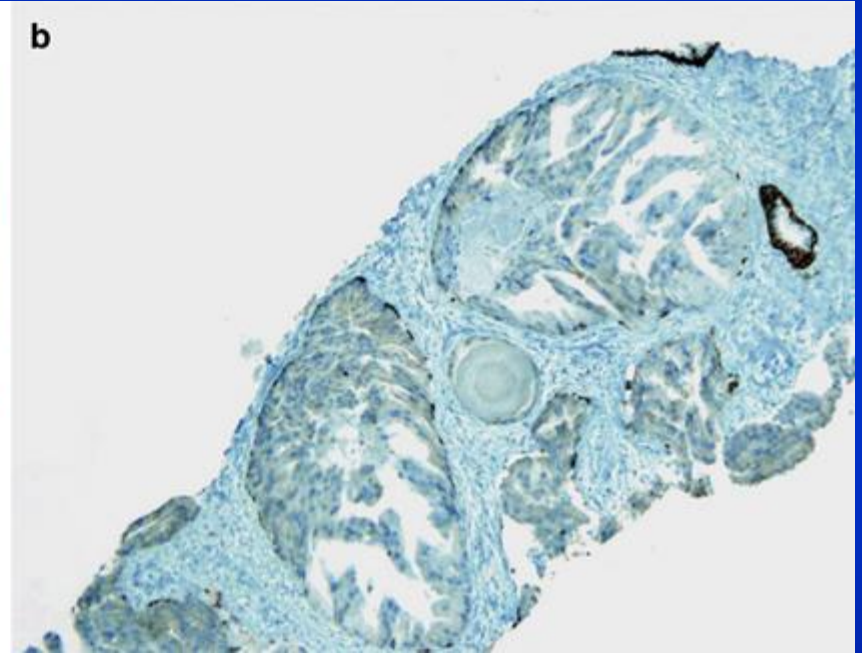
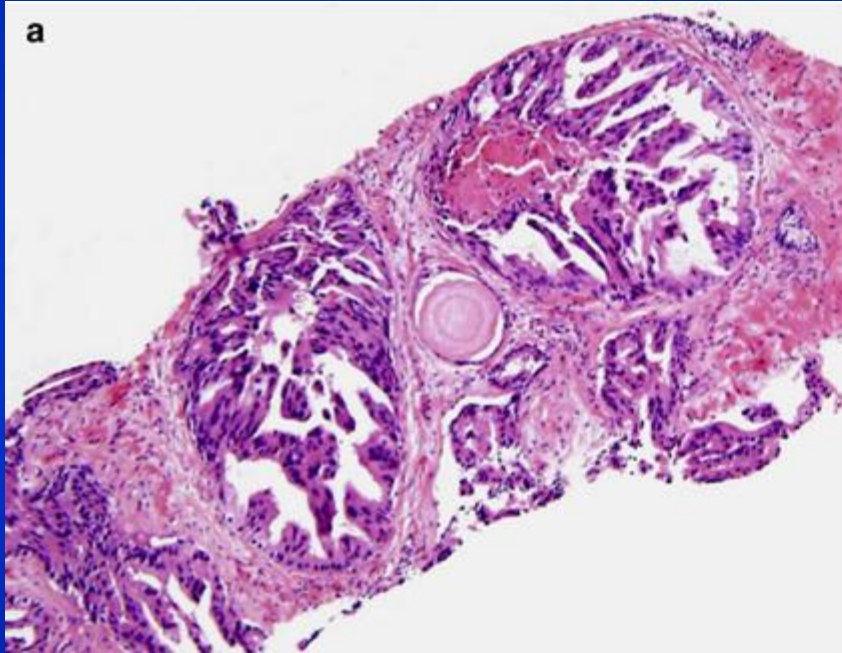
# IDC-P



## IDC-P, solid pattern



## IDC-P, micropapillary & necrosis

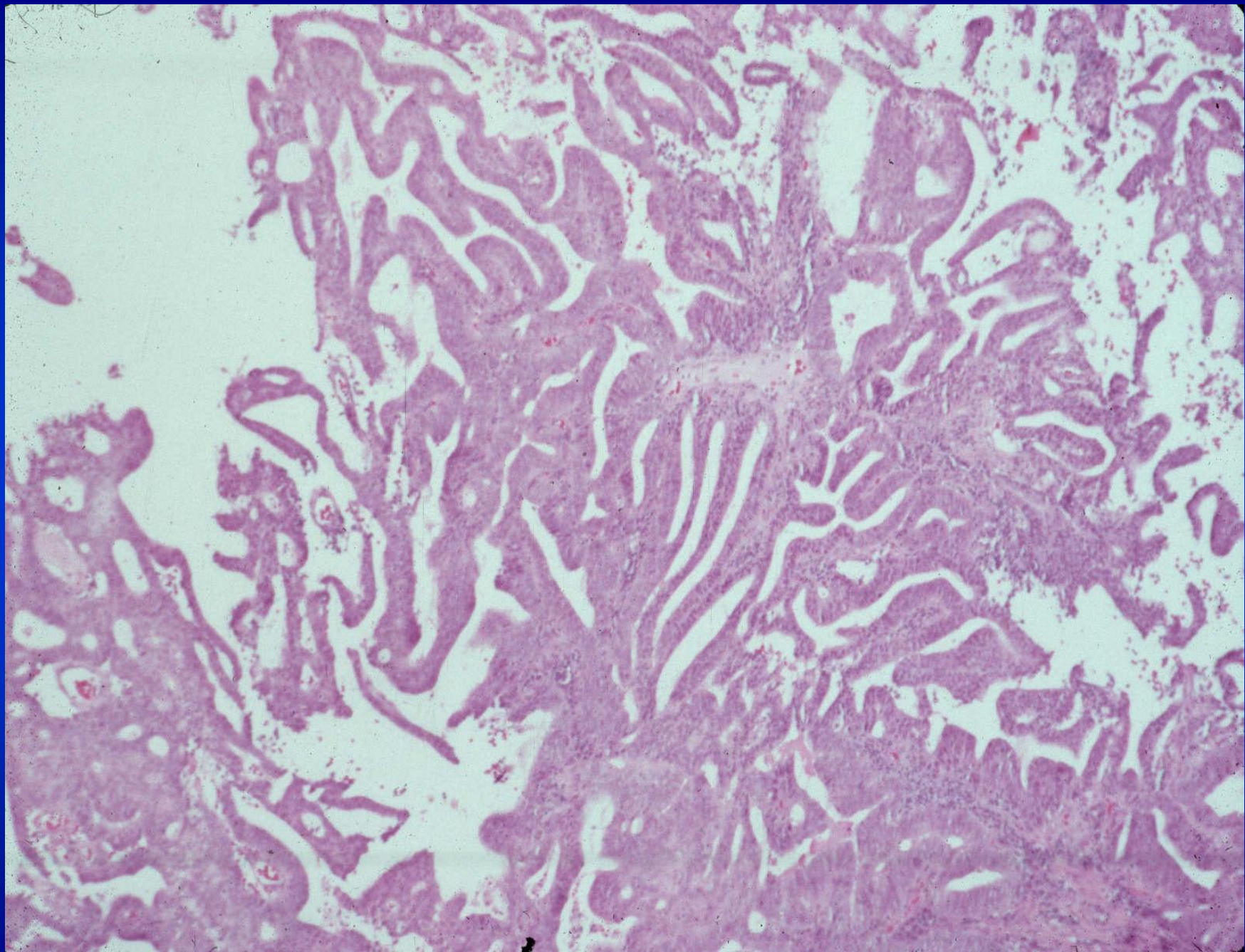


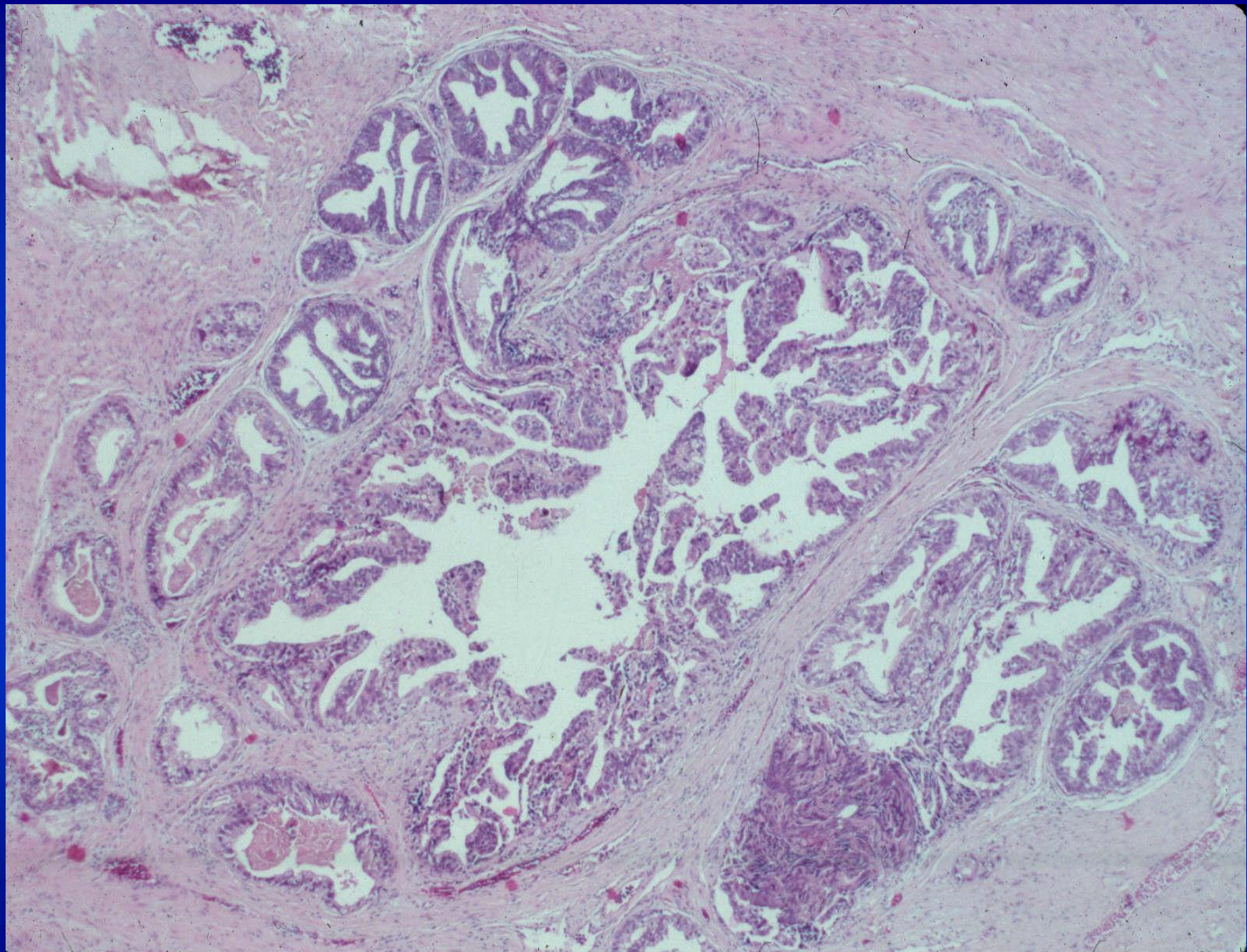
# Intraductal Carcinoma

- Ductal spread of high grade cancer?
- May be a possible lesion?

# **Our data (not published yet)**

- **Of 901 radical prostatectomy specimens (2006-2012)**
- **141 regular type IDC-P cases and 14 precursor-like IDC-P cases (3 IDC-P without coexisting invasive cancer and 11 predominant IDC-P with foci of invasive carcinoma)**
- **at least a subset of IDC-P precursor lesion of invasive carcinoma.**





# Prostatic Duct Ca with Endometrioid Features

- First described in 1967 by Melicow and Pachter
- Because of histologic similarity to endometrial ca, reported that it originated from Mullerian remnant (prostatic utricle)
- Estrogen Rx or orchiectomy was considered contraindicated
- Melicow and Tannenbaum reported 6 pts. All stage B, no orchiectomy, no hormone: survival excellent in 3 pts (less than 1 year follow-up)

# Prostatic Duct Ca with Endometrioid Features

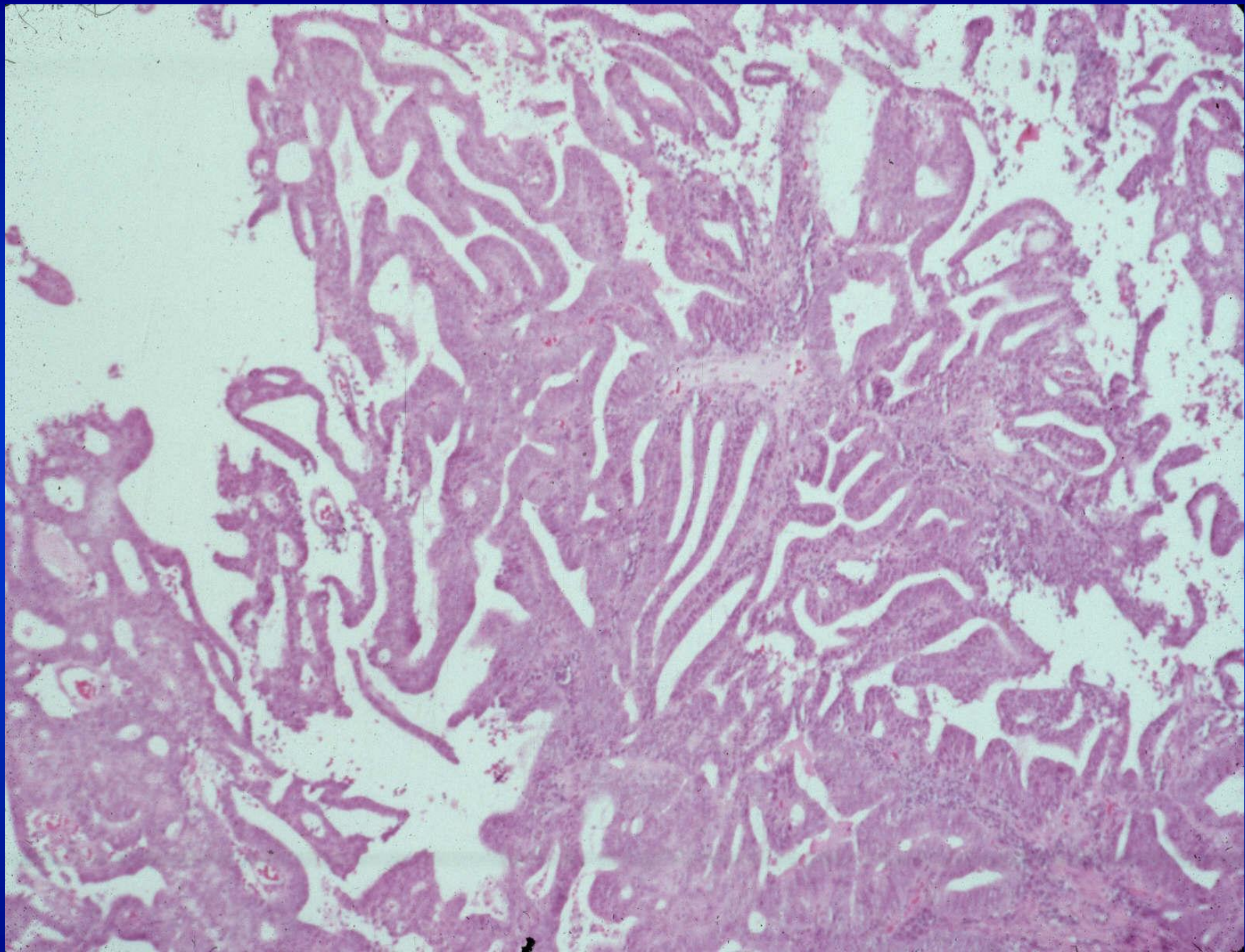
- Zaloudek et al: PAP positivity in tumor cells; tumor cells resemble prostate than endometrial carcinoma by EM
- Young and Lagios: orchiectomy produced tumor regression and clinical improvement
- Bostwick et al (13 cases), Epstein et al (10 cases) and Ro et al (35 cases)
- Those studies demonstrated that this tumor is prostatic origin and behavior is more aggressive than previously thought

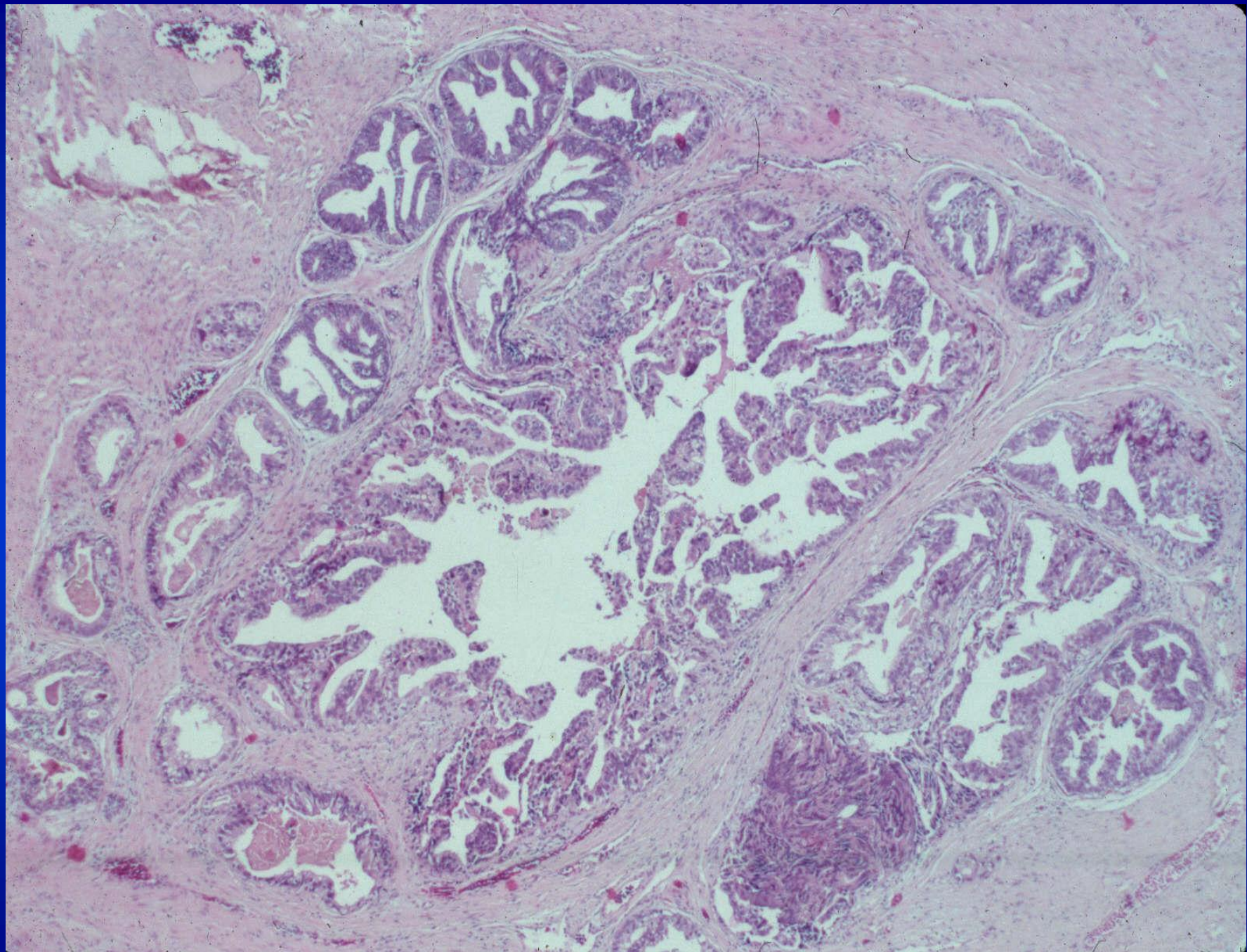
# Prostatic Duct Carcinoma

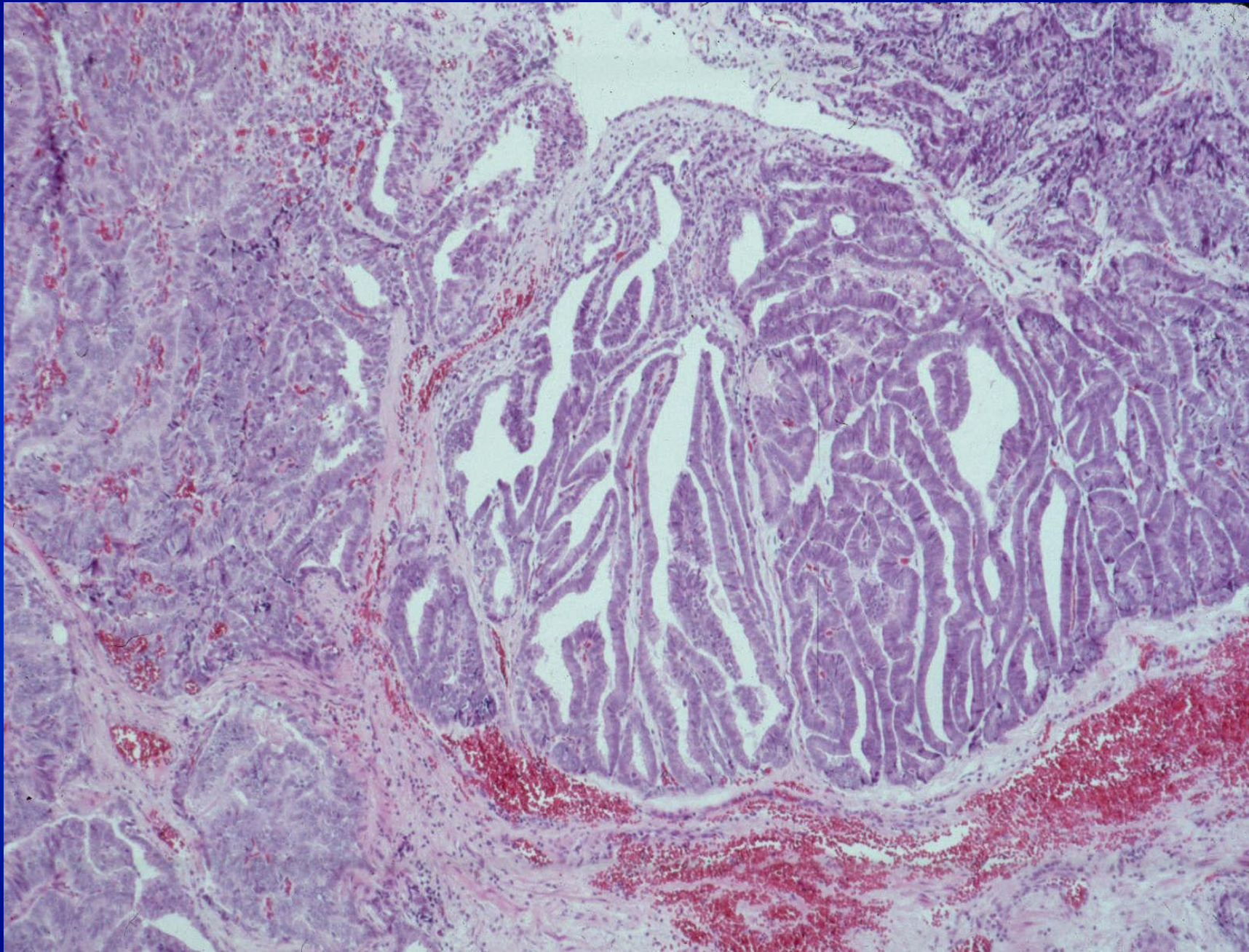
- **Clinical presentation is similar to usual prostatic adenocarcinoma**
- **May be exophytic into urethra producing a papillary lesion visible cystoscopically**
- **May present earlier with hematuria or obstruction and can be diagnosed in TURP specimen**
- **Have lower levels of serum PSA elevation than usual adenocarcinoma**
- **Metastatic pattern is similar to usual prostatic adenocarcinoma**

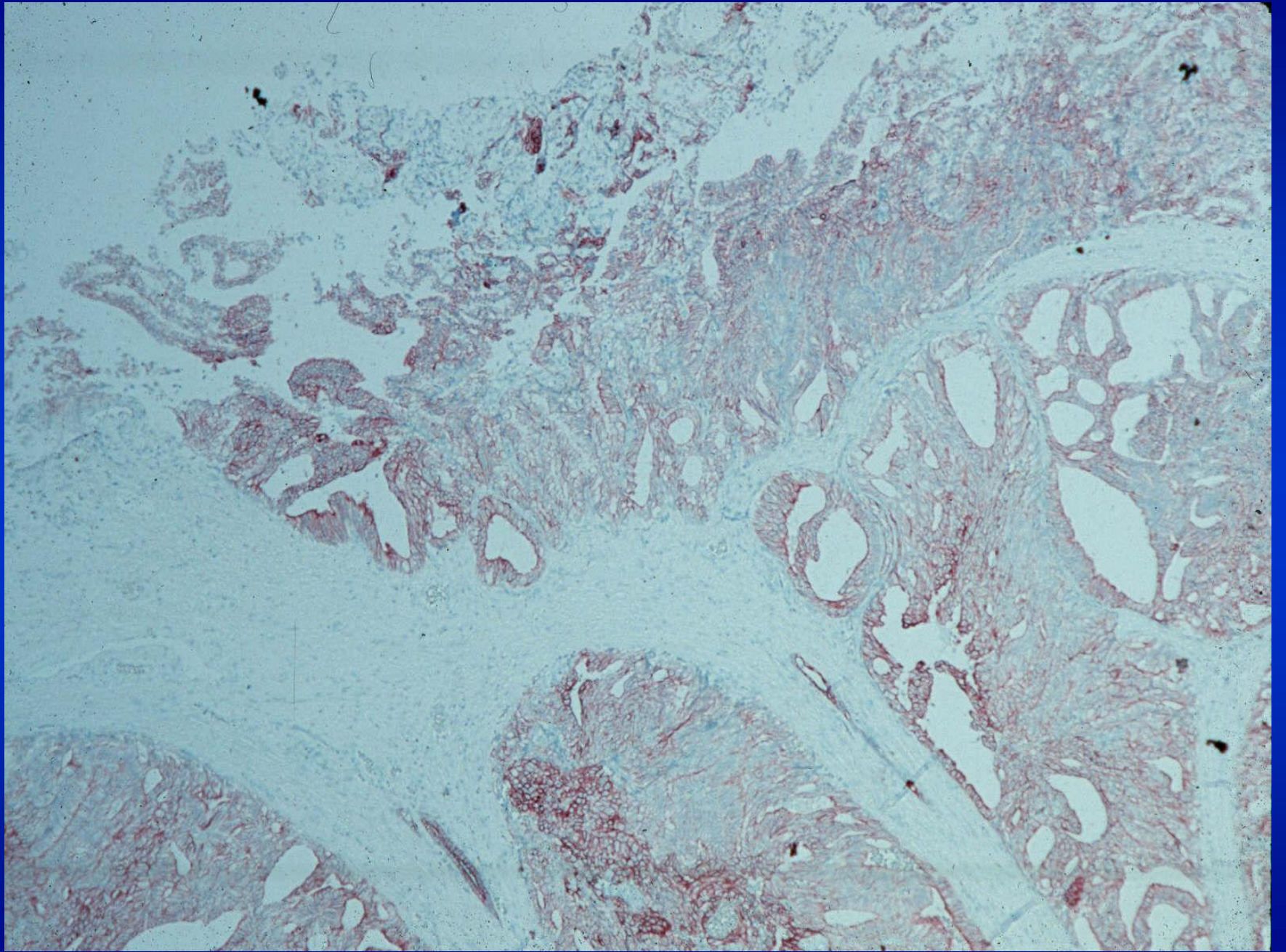
# Prostatic Duct Carcinoma

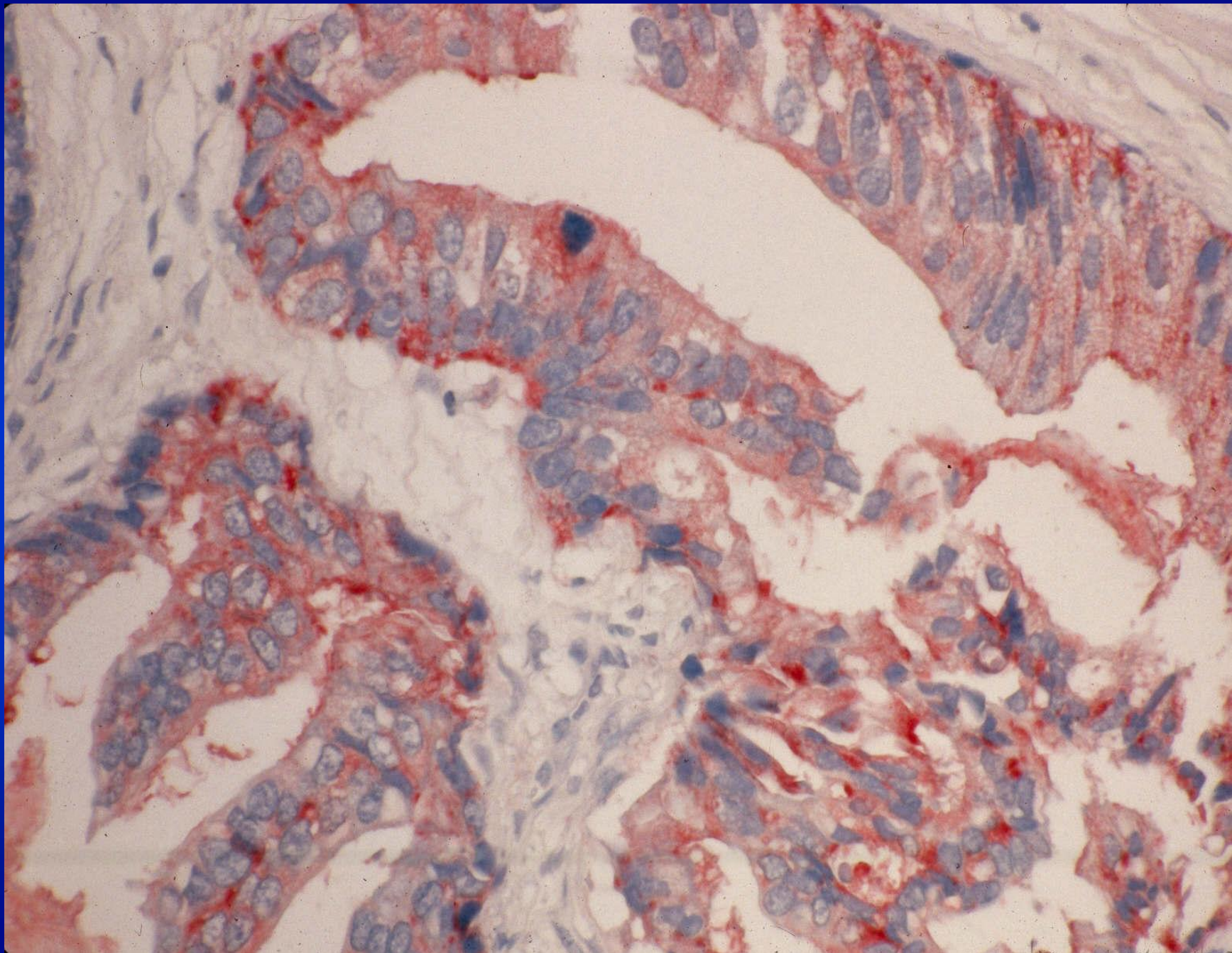
- Exuberant papillary pattern (type A)
- Predominantly intraductal component (type B)
- Types A and B coexist in half of cases
- Single to stratified tall columnar epithelium
- Tumor cell have basally located nuclei, prominent nucleoli and abundant eosinophilic cytoplasm

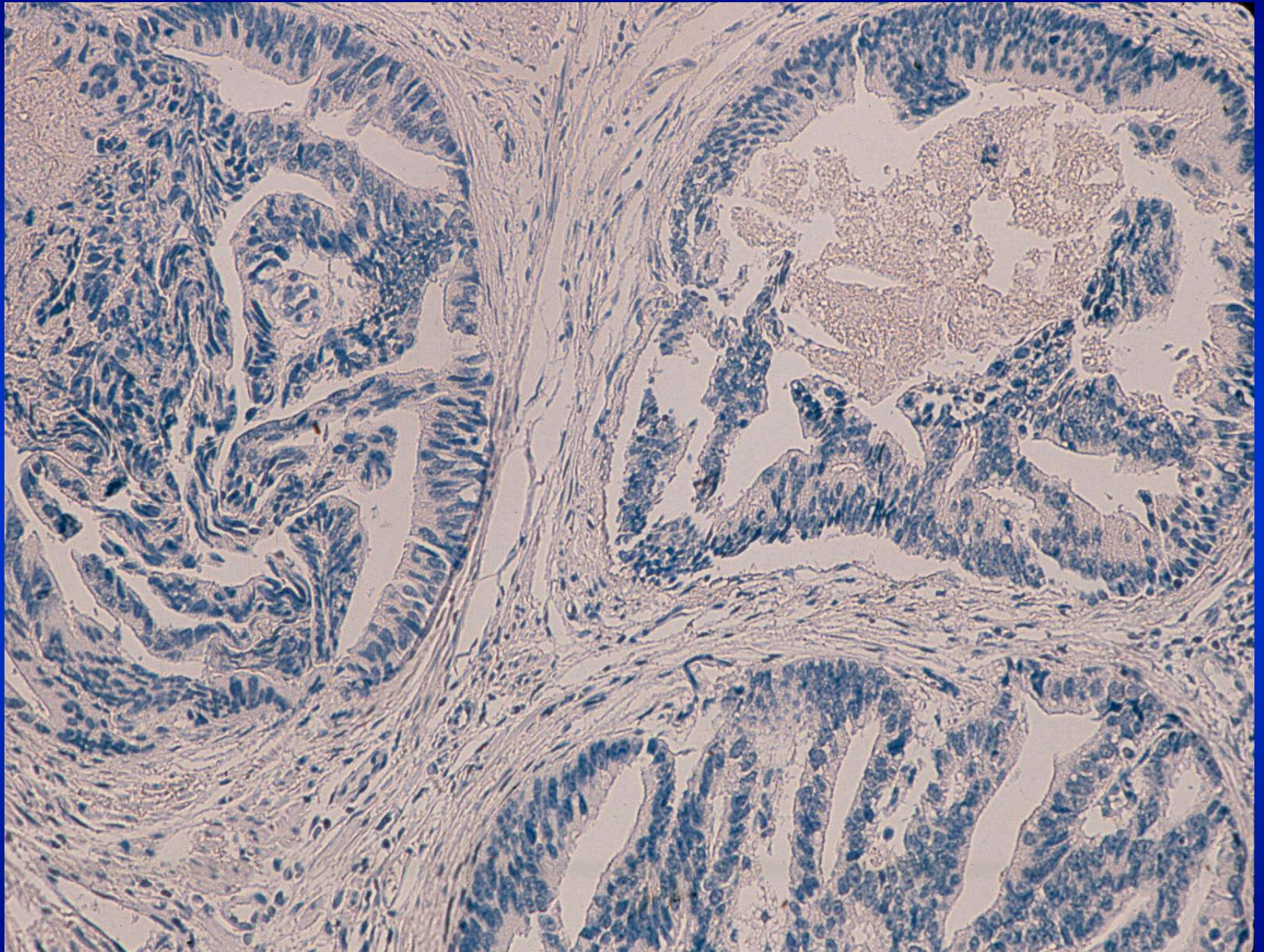






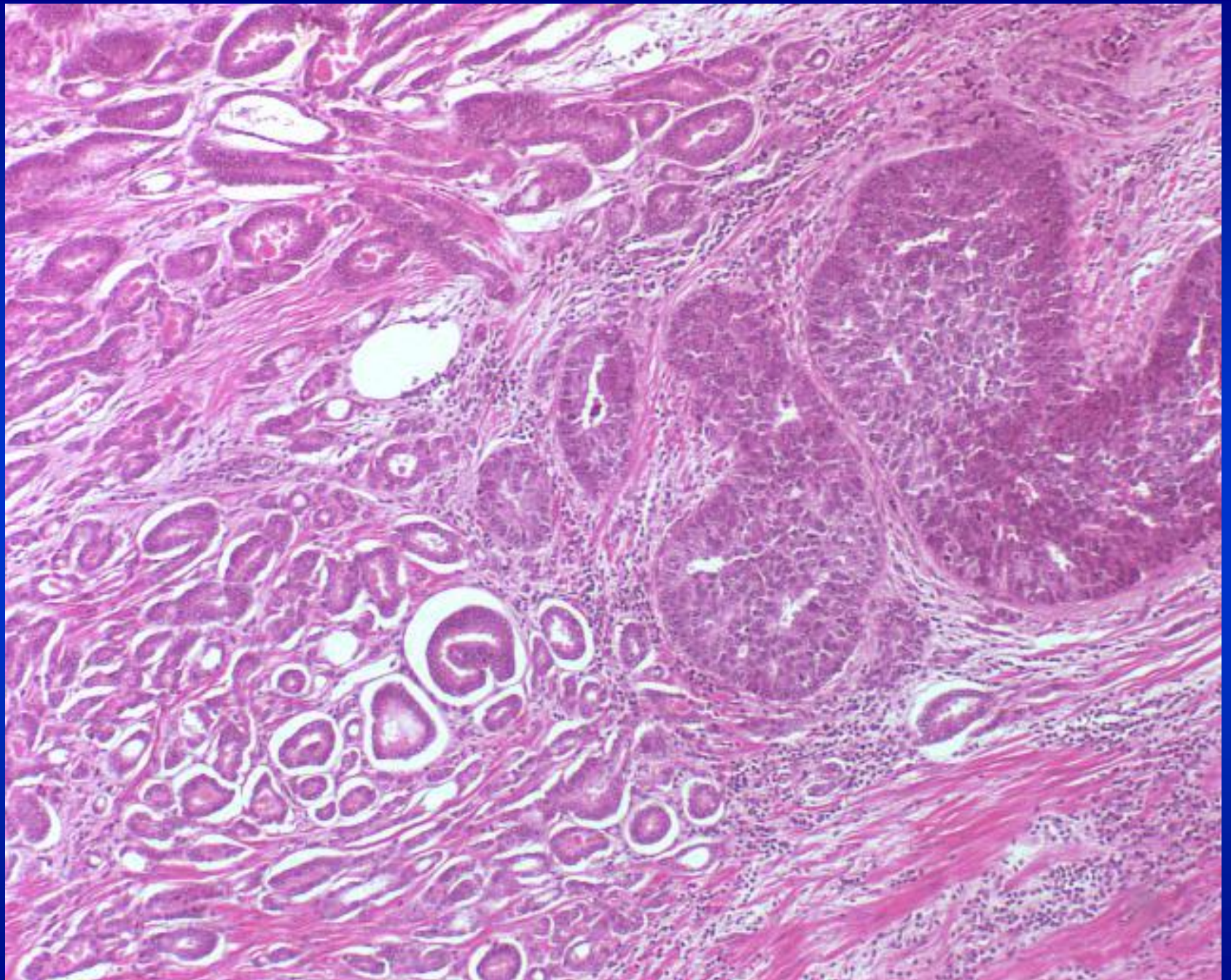






# Prostatic Duct Carcinoma

- Association with microacinar ca in half of cases
- Grade of microacinar ca is generally low grade: Gleason's score  $\leq 6$
- PSA and PAP positive: CEA may be positive (CK 20 may be positive)
- Electron microscopy: prostatic secretory cells with no endometrial feature



# Prostatic Duct Carcinoma

## *Treatment & Prognosis:*

- Radical prostatectomy, hormone, castration and/or radiation
- Hormonal response: unpredictable
- 5 year survival rate: 30%
- Median survival time: 46.3%

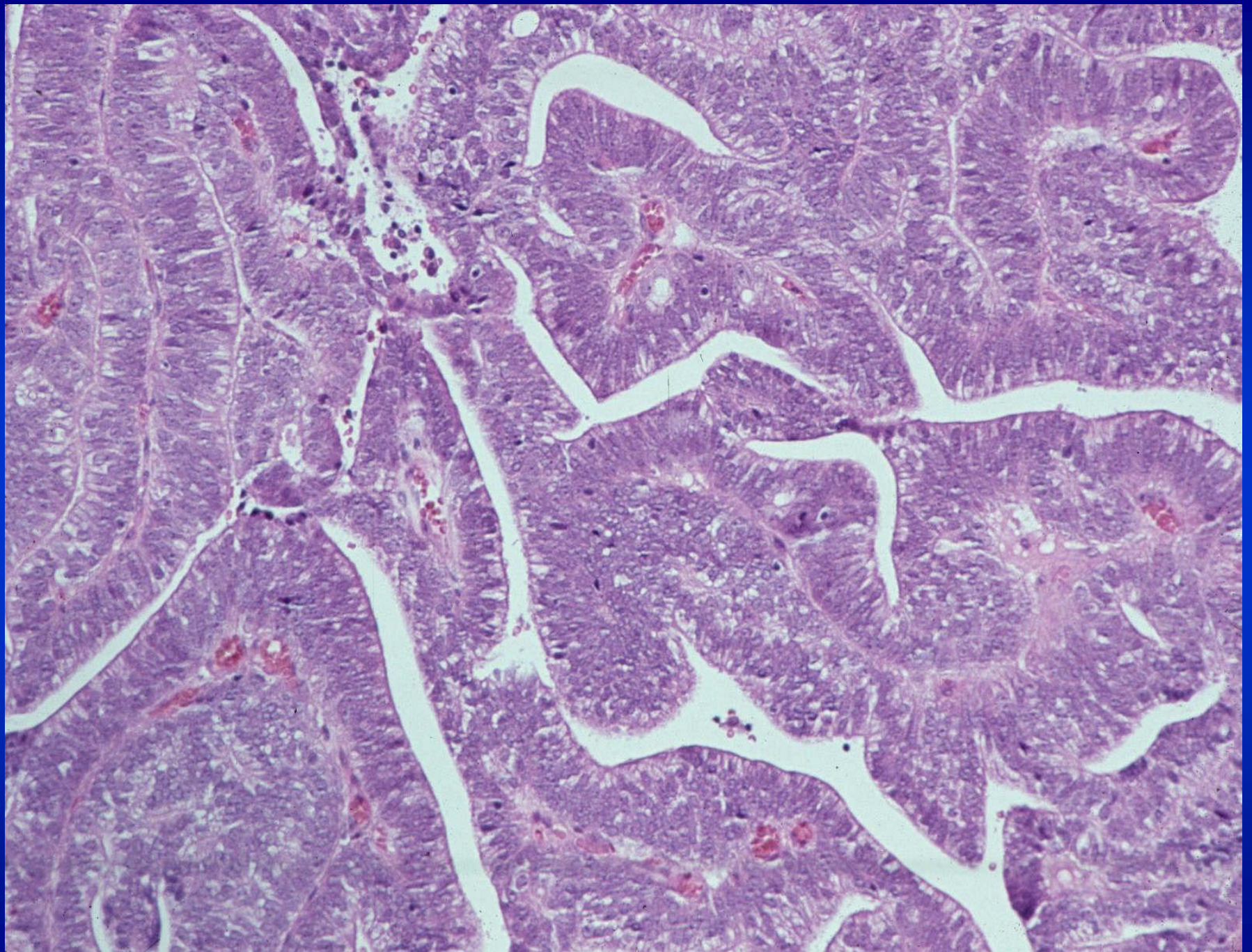
# Prostatic Duct Carcinoma

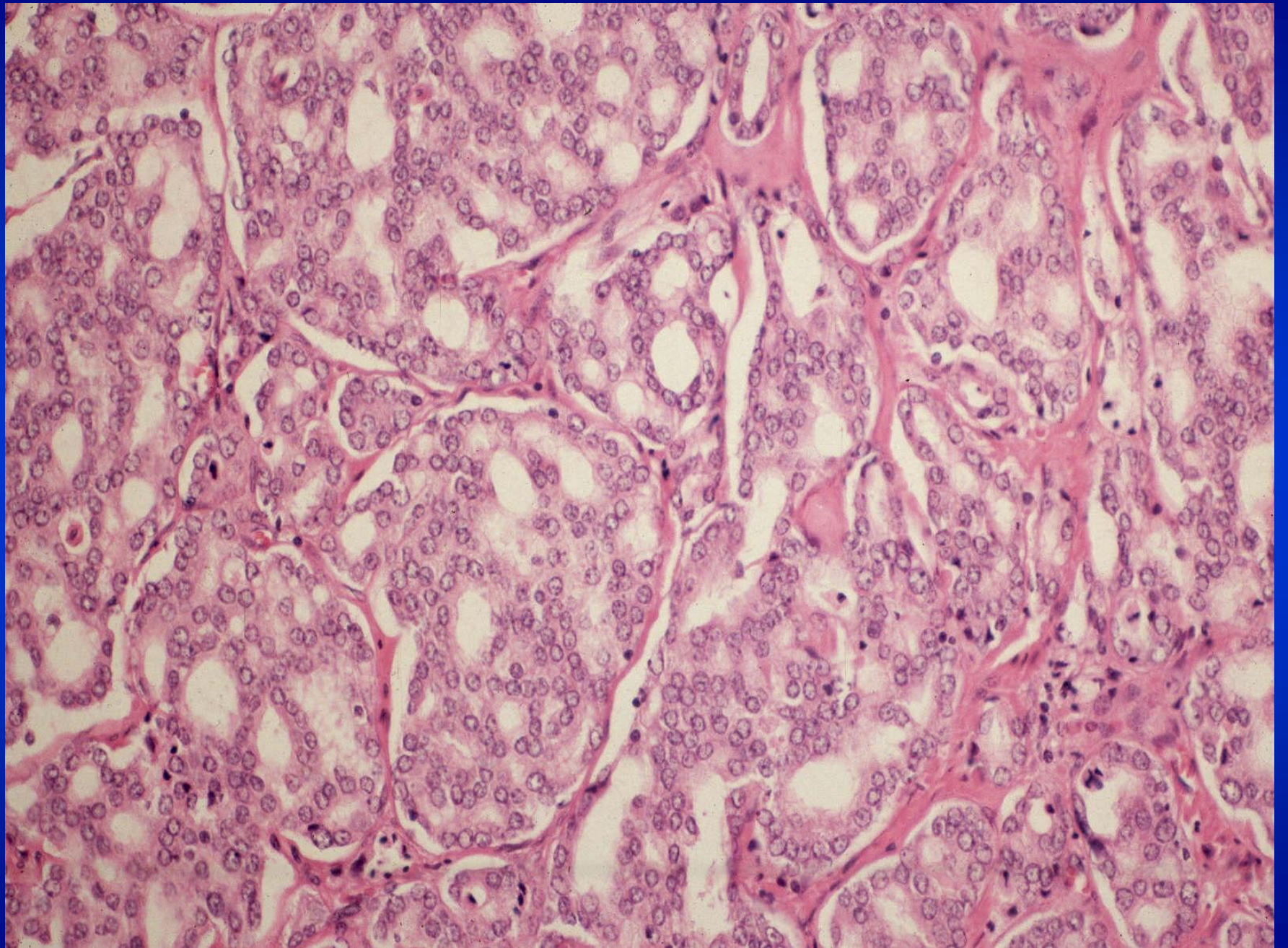
- Christensen et al studies in radical prostatectomy (15 cases) - clinical stage B
- Compared c acinar ca of similar stage
- Ductal ca were larger and occupied larger portion of the glands
- Advanced final pathologic stage and higher short-term failure than acinar ca

# Prostatic Duct Carcinoma

## Differential diagnosis

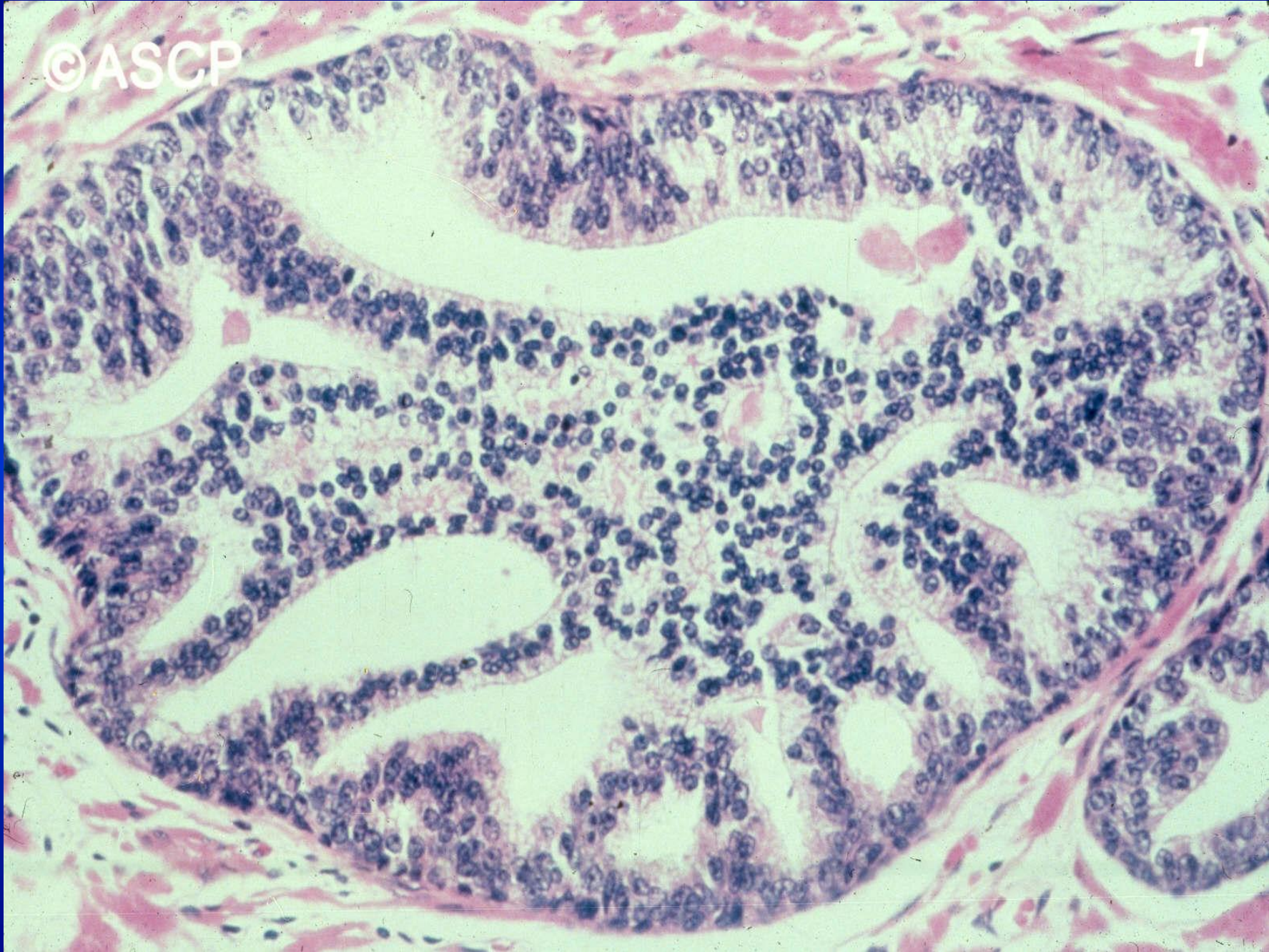
	PDC	Cribriform ca	PIN
<b>Cell type</b>	<b>Columnar</b>	<b>Cuboidal</b>	<b>Columnar</b>
<b>Stratified</b>	<b>+</b>	<b>-</b>	<b>+</b>
<b>Maturation</b>	<b>-</b>	<b>-</b>	<b>+</b>
<b>Lumina</b>	<b>Slit-like</b>	<b>Punched-out round lumina</b>	<b>Complex</b>
<b>Fibrovas core</b>	<b>+</b>	<b>-</b>	<b>+</b>
<b>Comedo Nec</b>	<b>+</b>	<b>+</b>	<b>-</b>
<b>Periurethral/TZ</b>	<b>+</b>	<b>-/+</b>	<b>-/+</b>
<b>TURP</b>	<b>+</b>	<b>-/+</b>	<b>-/+</b>





©ASCP

7



# Prostatic Duct Carcinoma

- **McNeal et al raised question on the entity of ductal carcinoma: may be ductal spread of acinar ca**
- **Grade matched ductal ca and acinar ca demonstrated higher mitotic no. and proliferative activity in ductal ca**

# Prostatic Duct Carcinoma

## *Summary:*

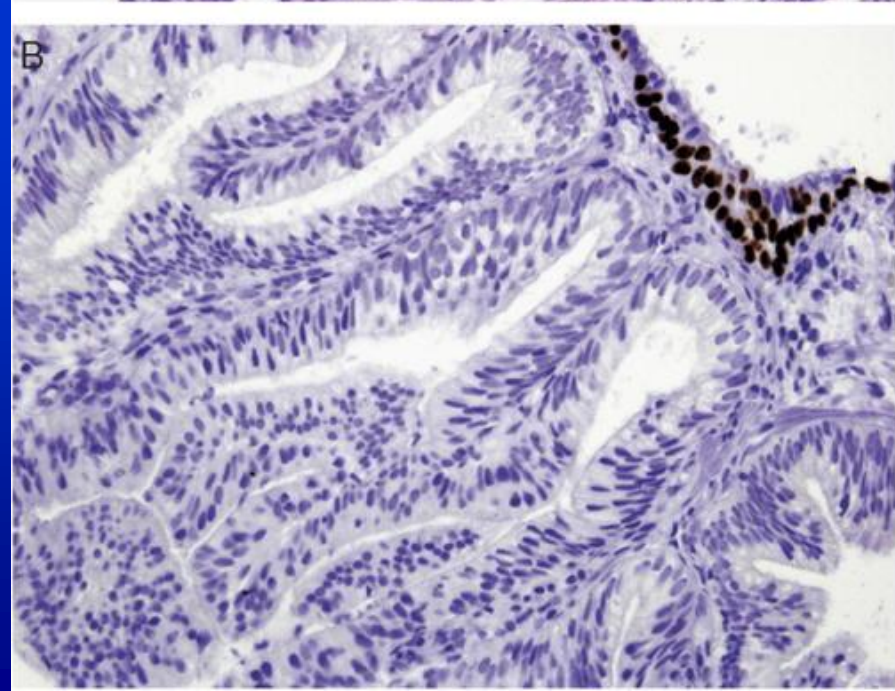
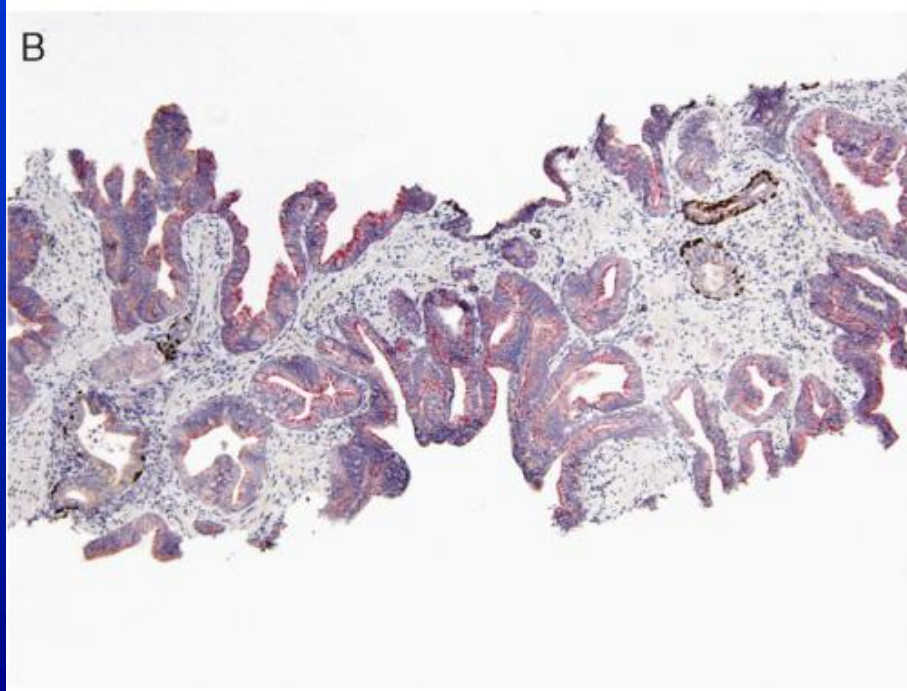
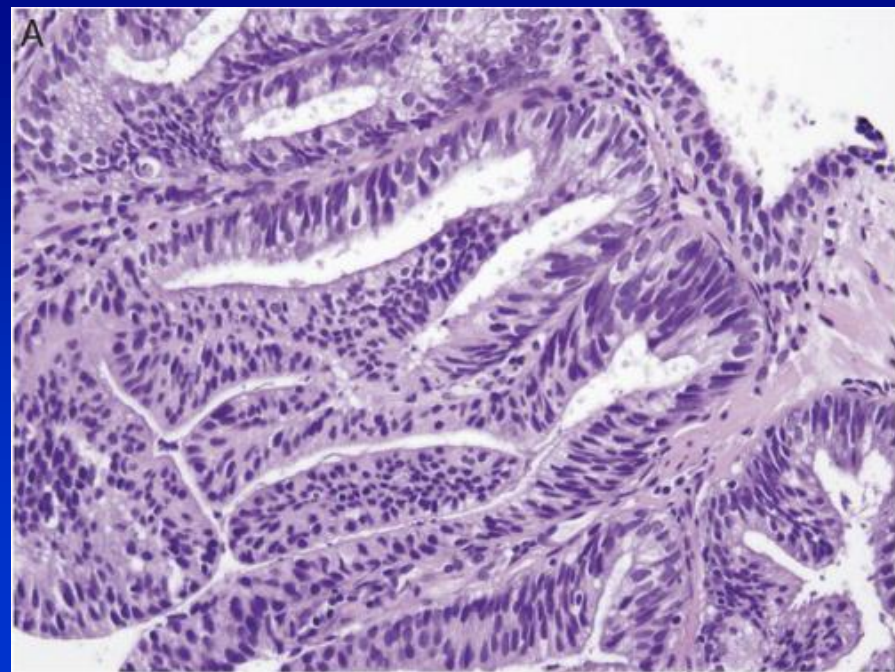
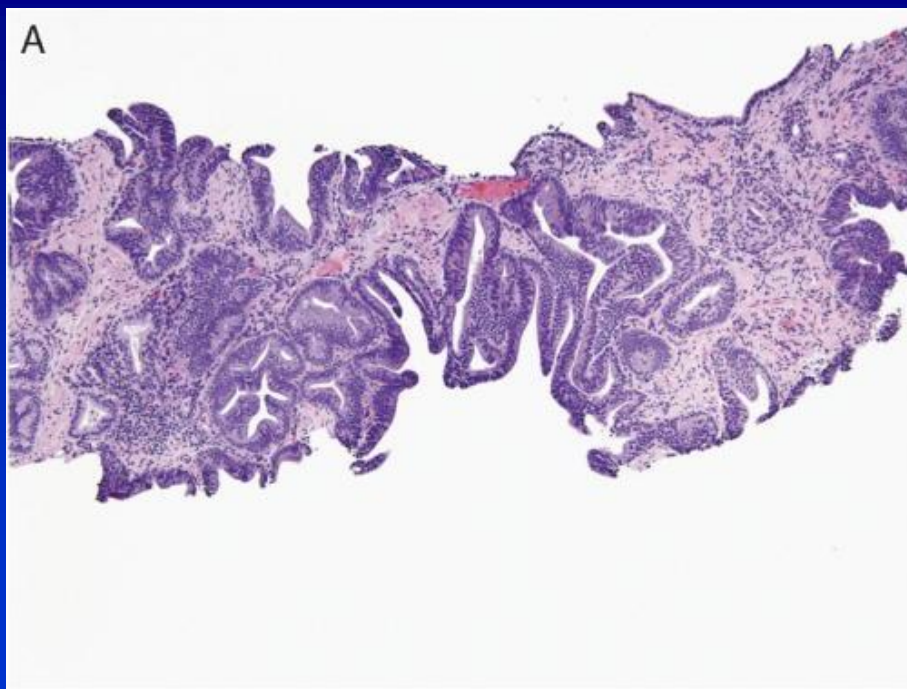
- Patients frequently presented with obstruction/hematuria
- Carcinoma of ductal origin
- Role of hormone/orchiectomy is still uncertain
- Its biologic behavior is more aggressive than previously thought

# **PIN-like (Intraductal-like) Prostatic Duct Carcinoma**

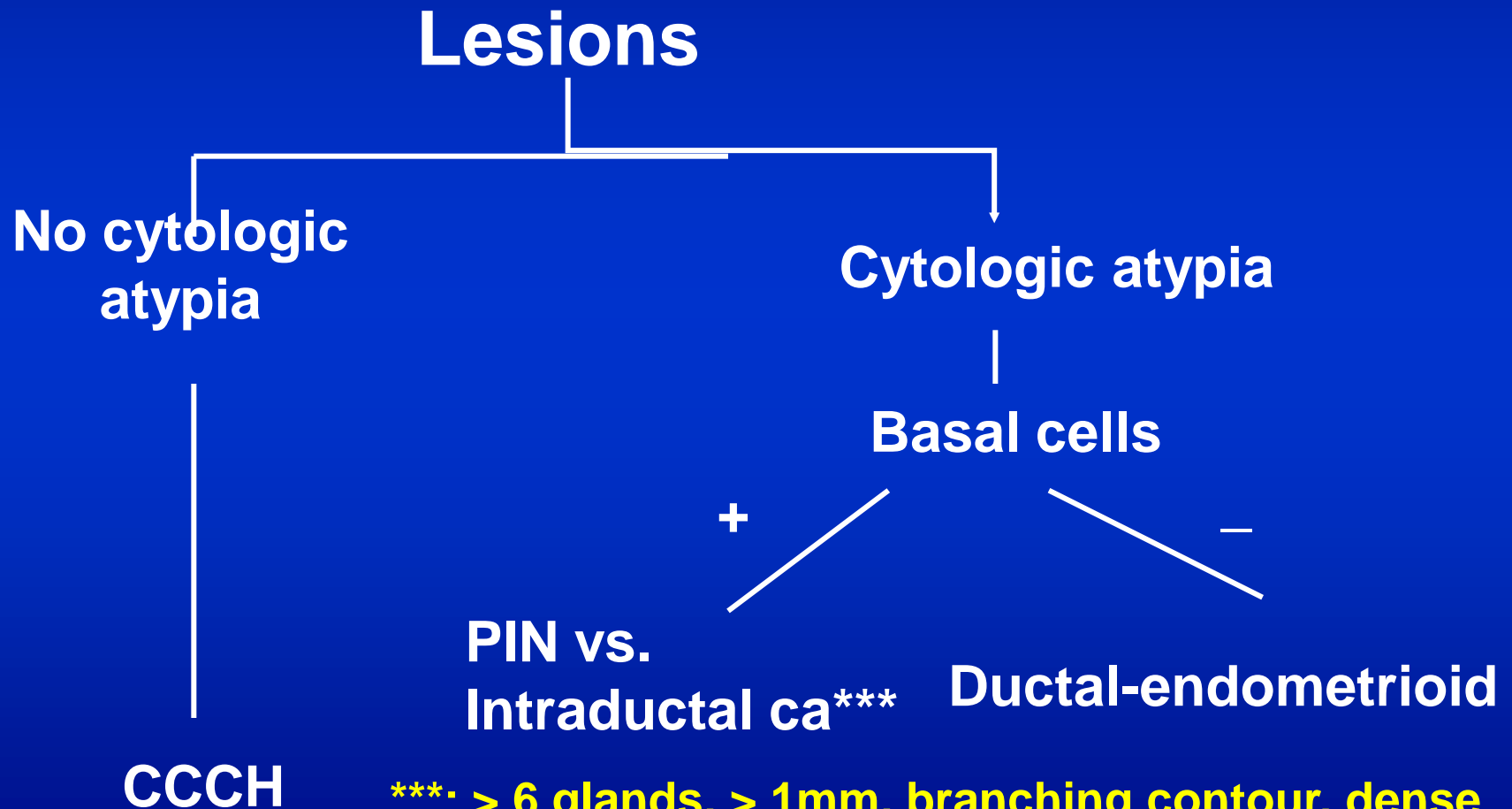
- **Hammed and Humphrey: Mod Pathol(2006)  
19, 899–906**
- **Tavora and Epstein: Am J Surg Pathol  
(2008)32,1060–1067**
- **PIN-like prostatic ductal carcinoma**
- **Variant?**
- **Need more studies**

# **PIN-like prostatic Duct Carcinoma**

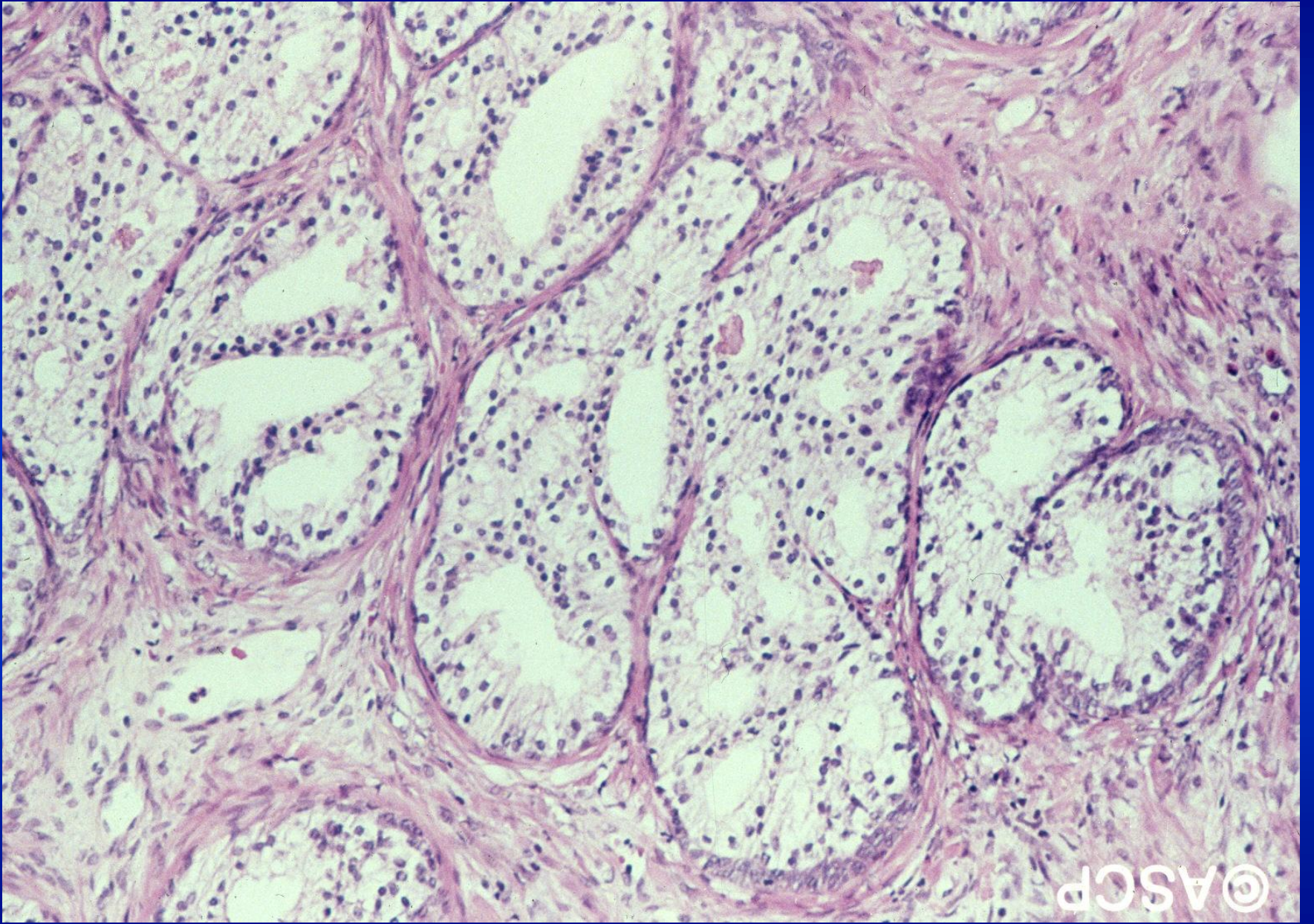
- **Gleason pattern 3**
- **No basal cells, AMACR freq +**
- **6 of 9 RP cases associated with GS 6 carcinoma and small volume tumor up to 1.2 cm<sup>3</sup>**
- **Only one had EPE**
- **DD from HGPIN and conventional ductal carcinoma**

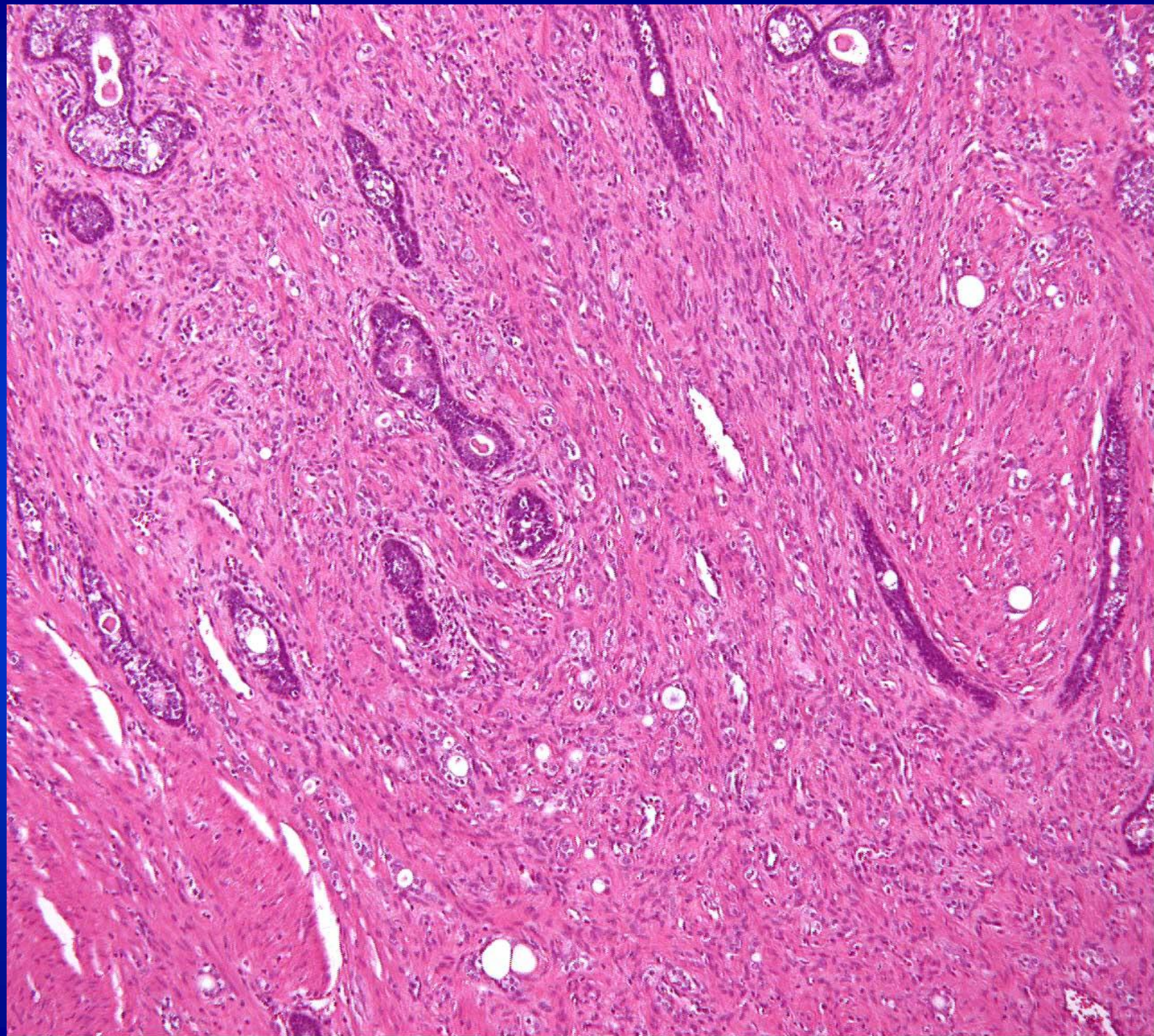


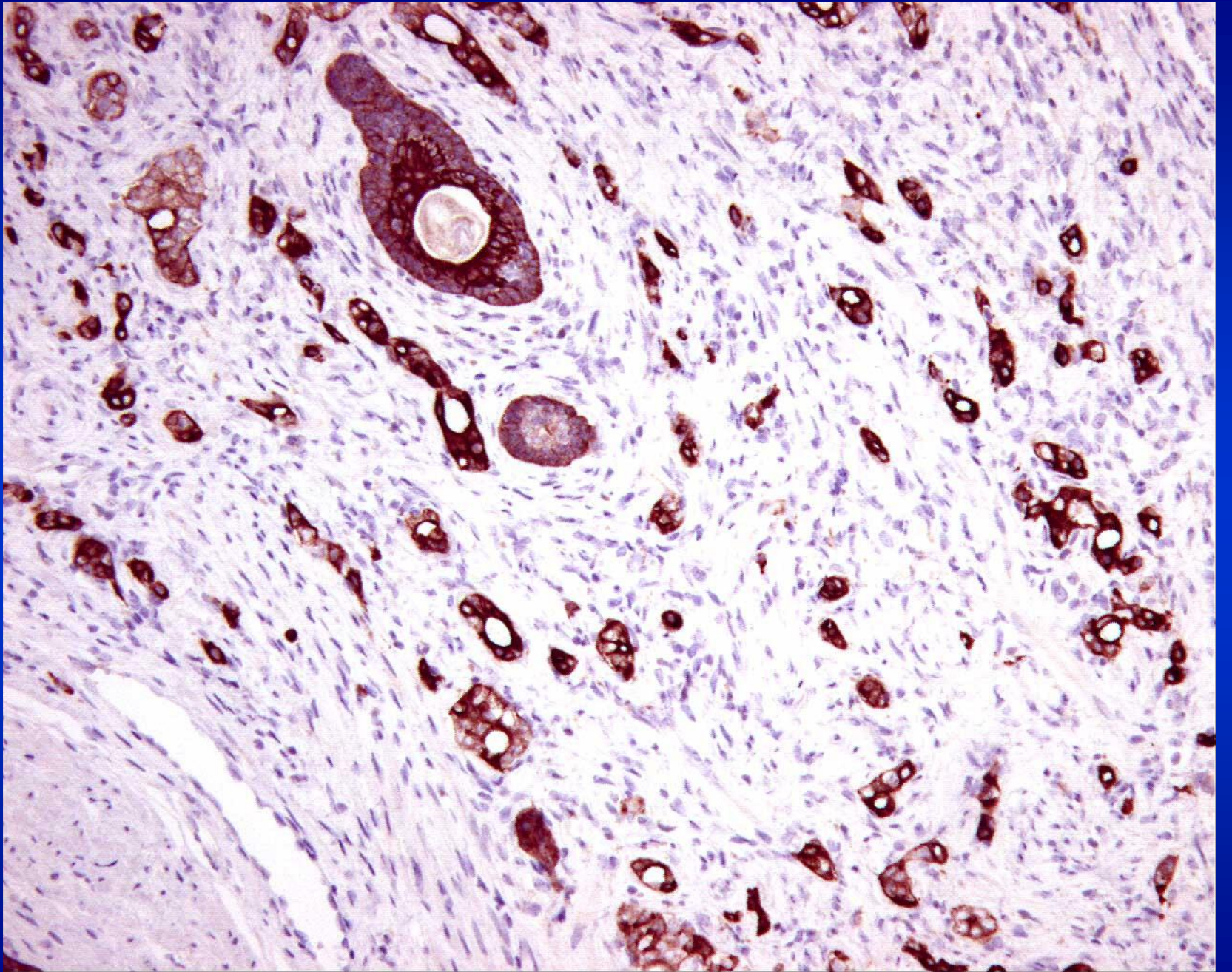
# Large Cribriform Gland Lesions

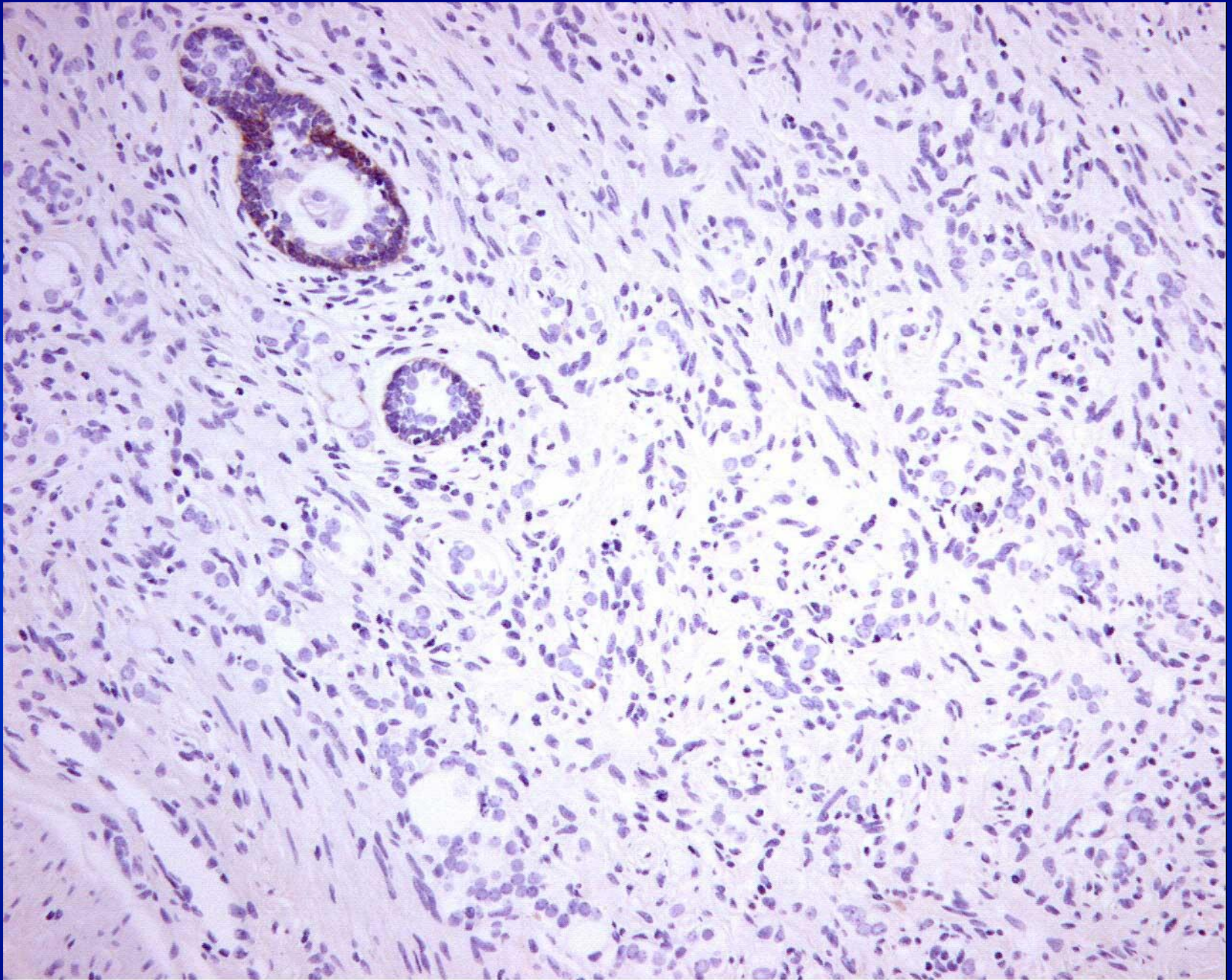


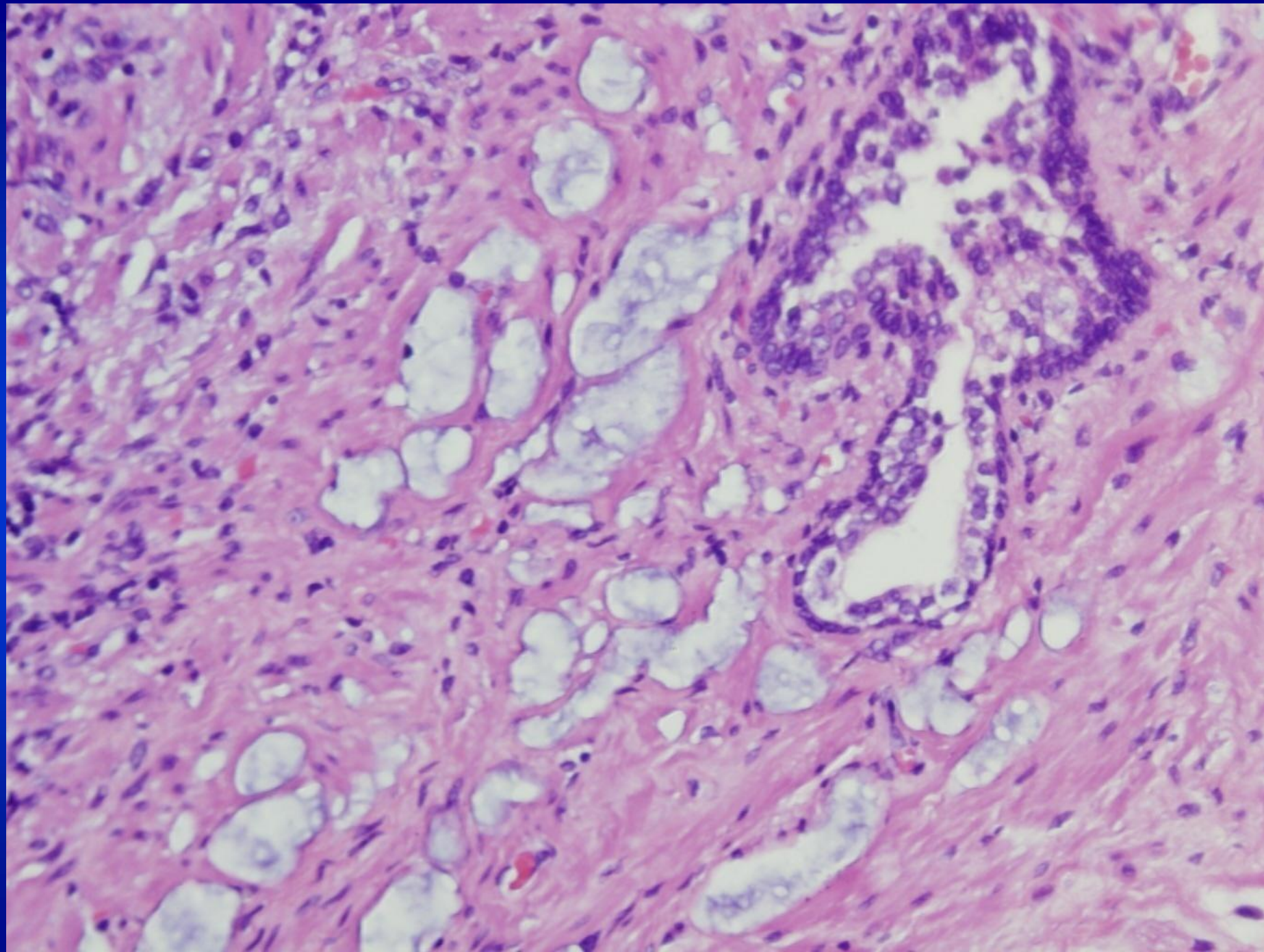
\*\*\*: > 6 glands, > 1mm, branching contour, dense cribriform/solid, comedonecrosis, pleomorphism

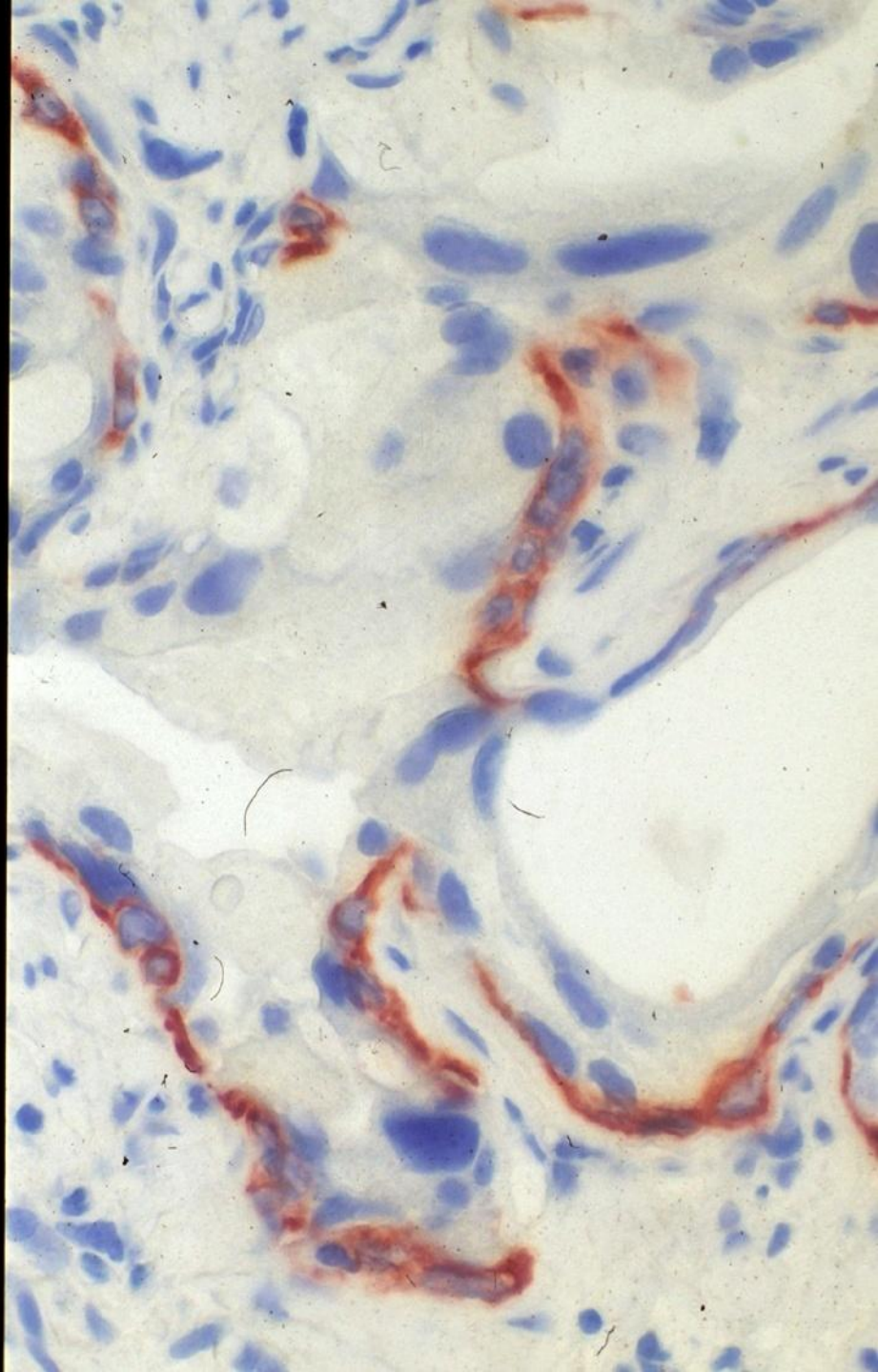
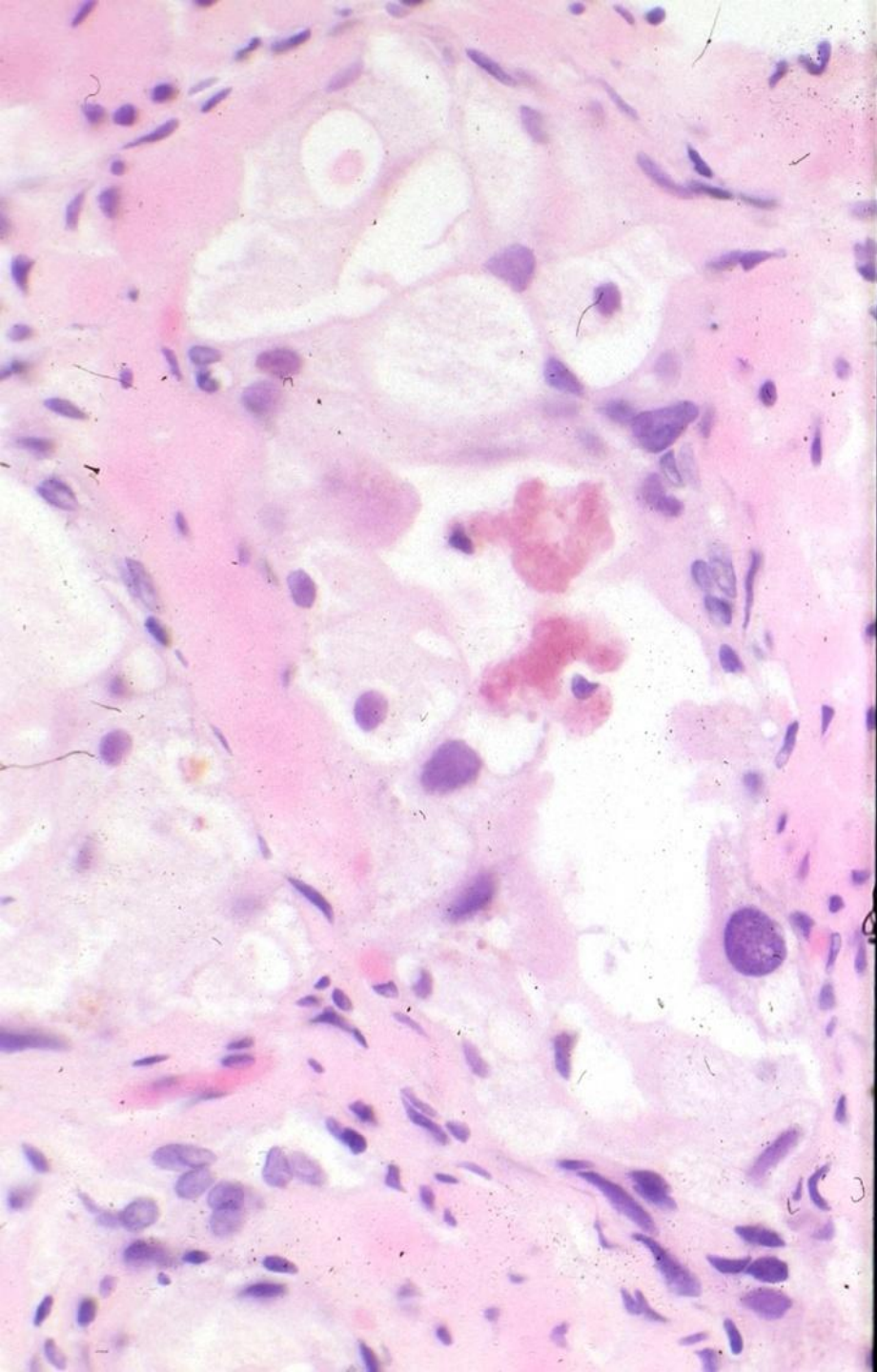


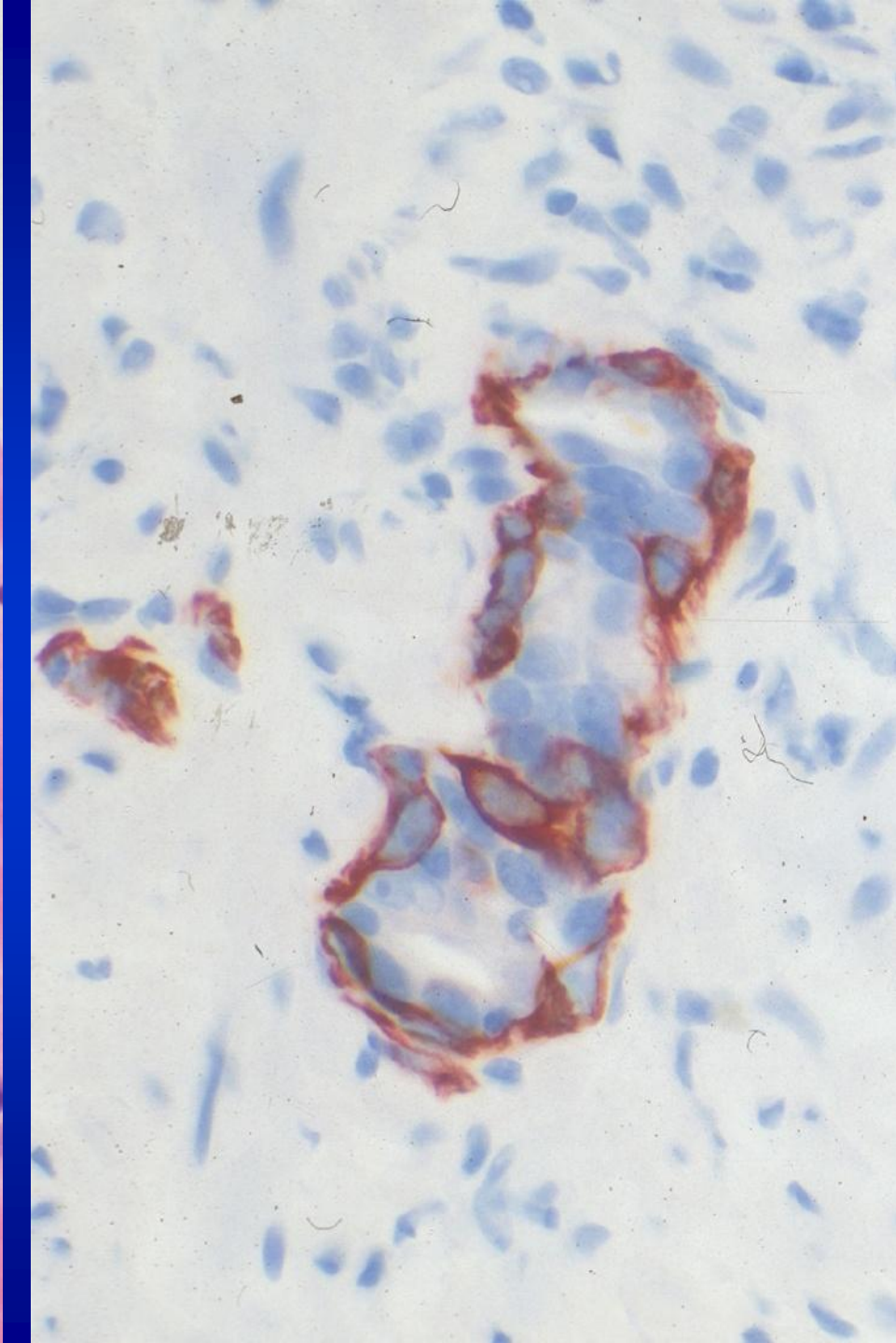
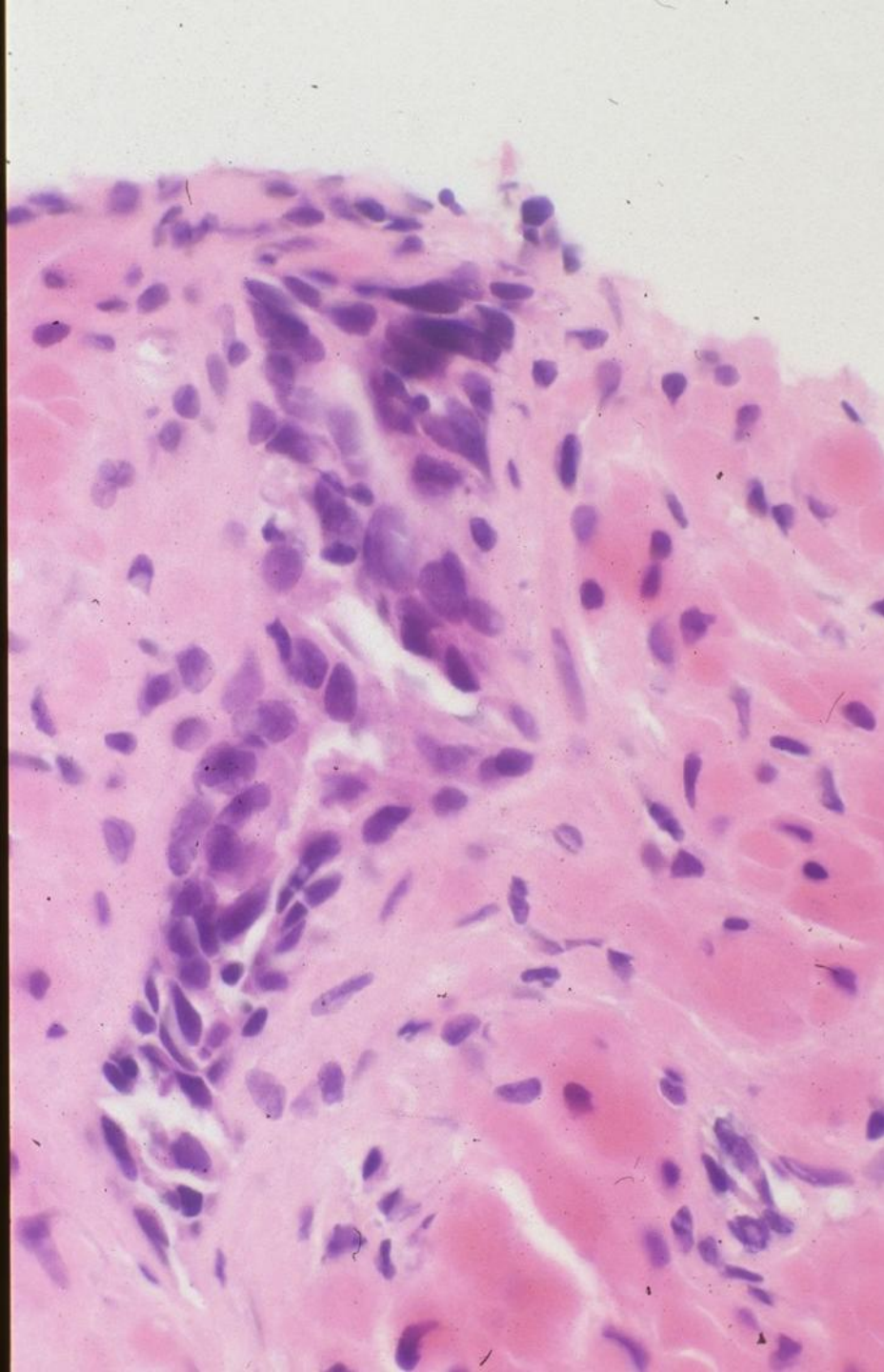


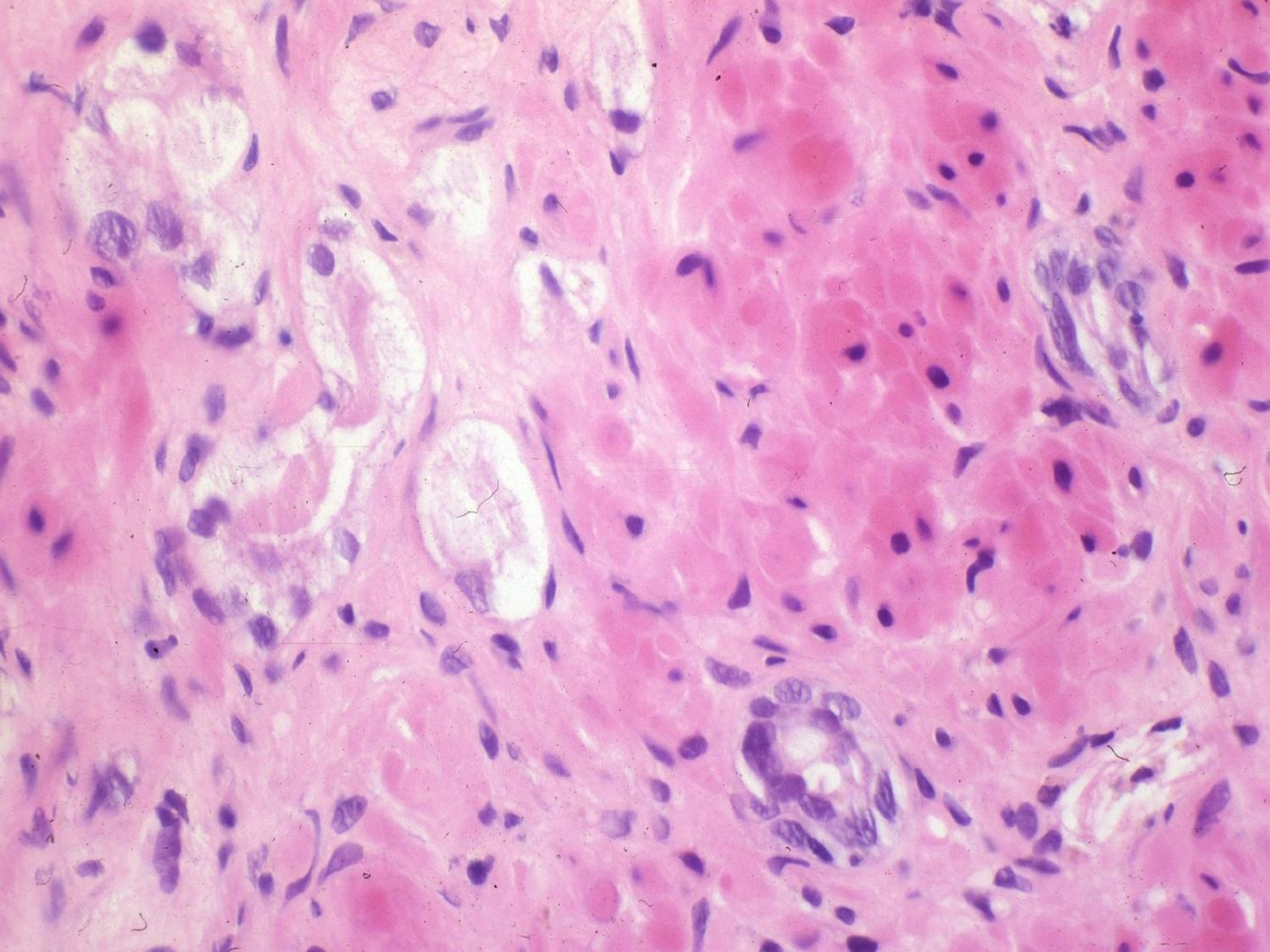


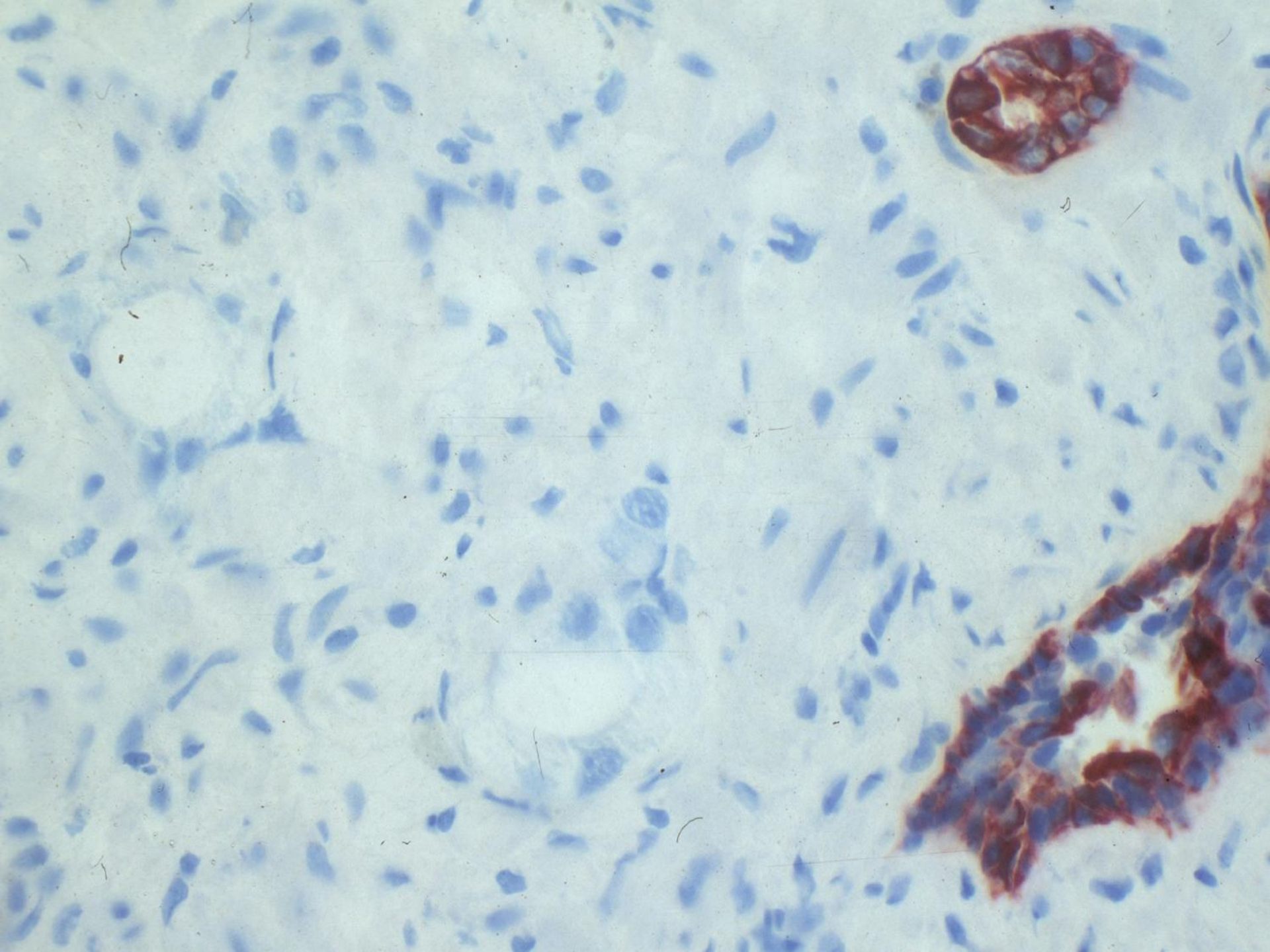










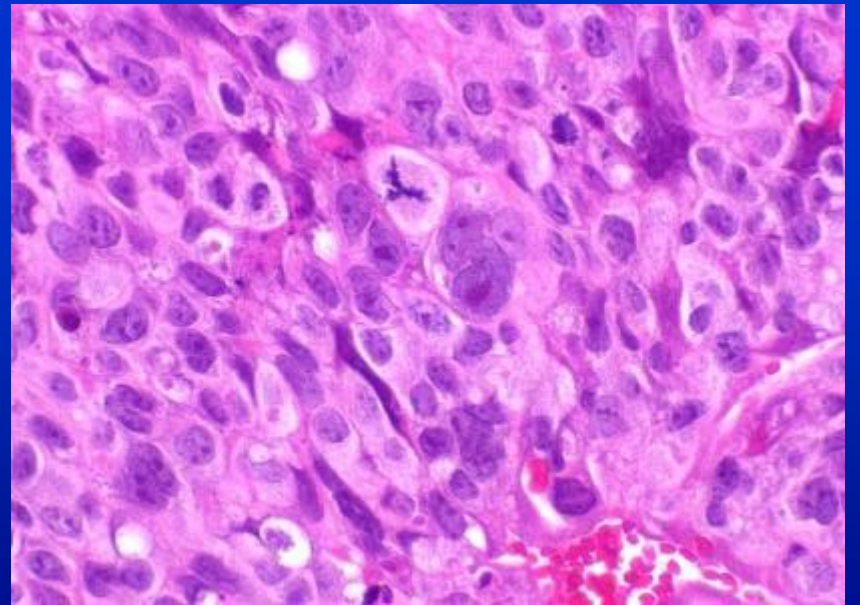
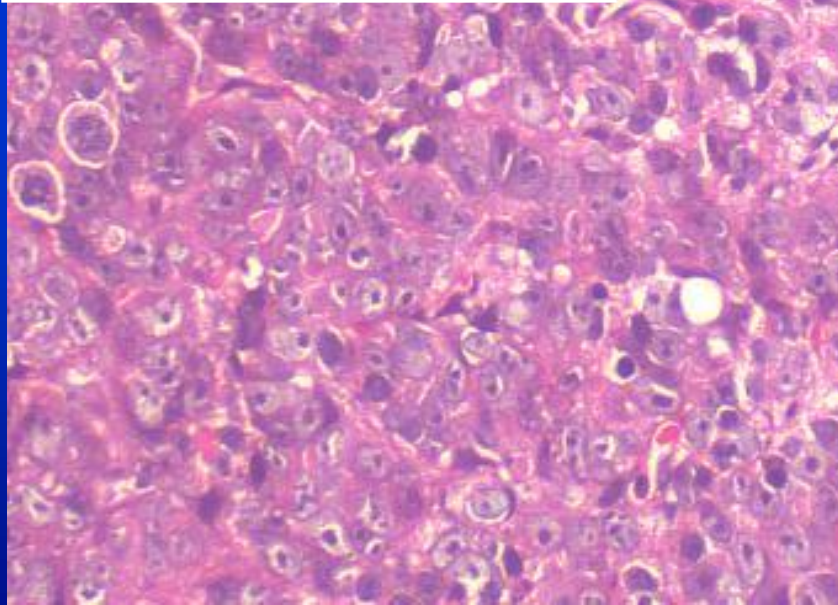
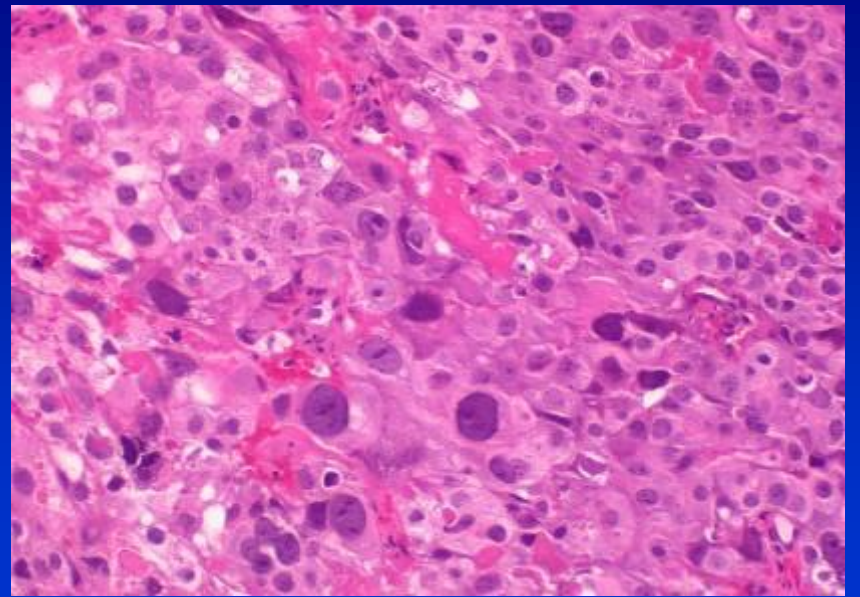
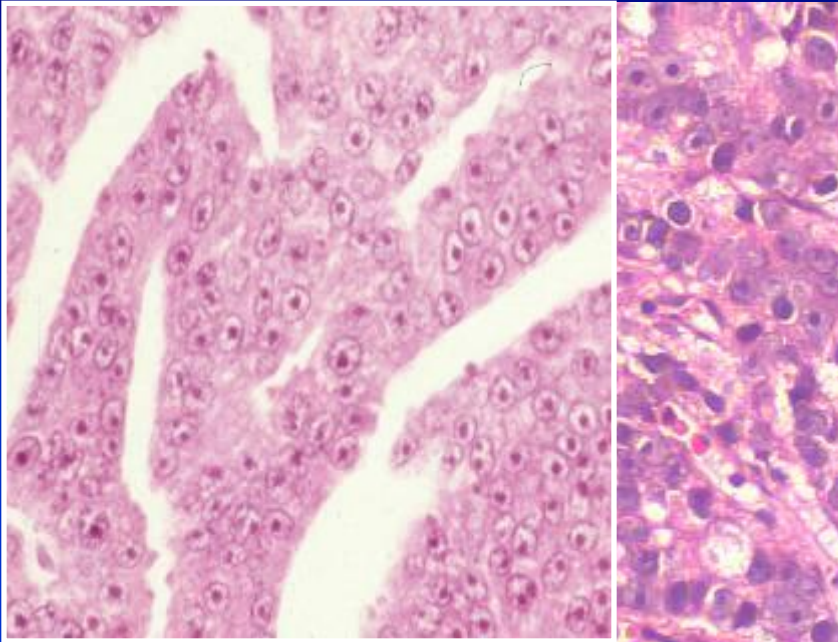


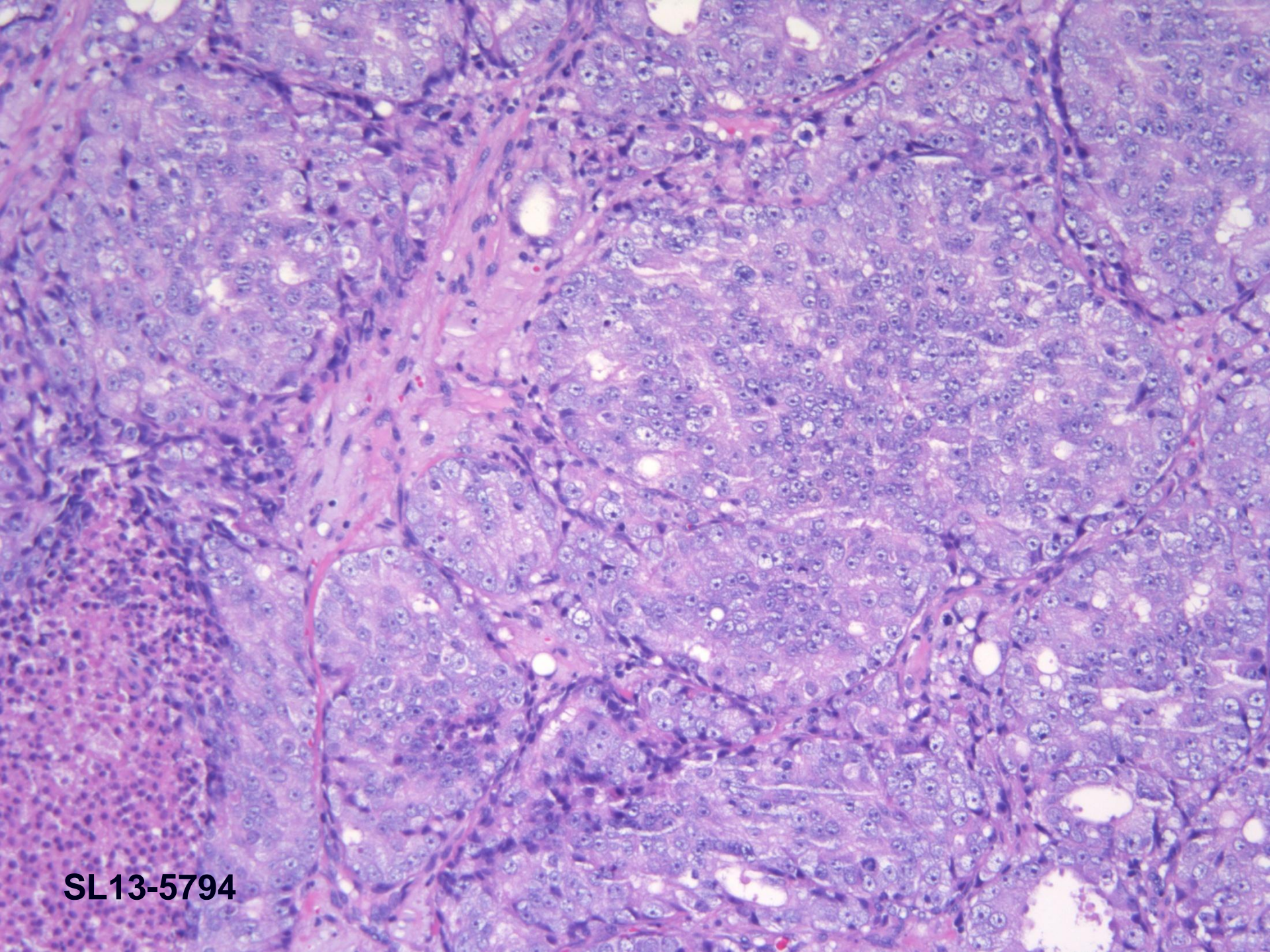
# High grade prostatic carcinoma vs. Non-prostatic carcinoma

---

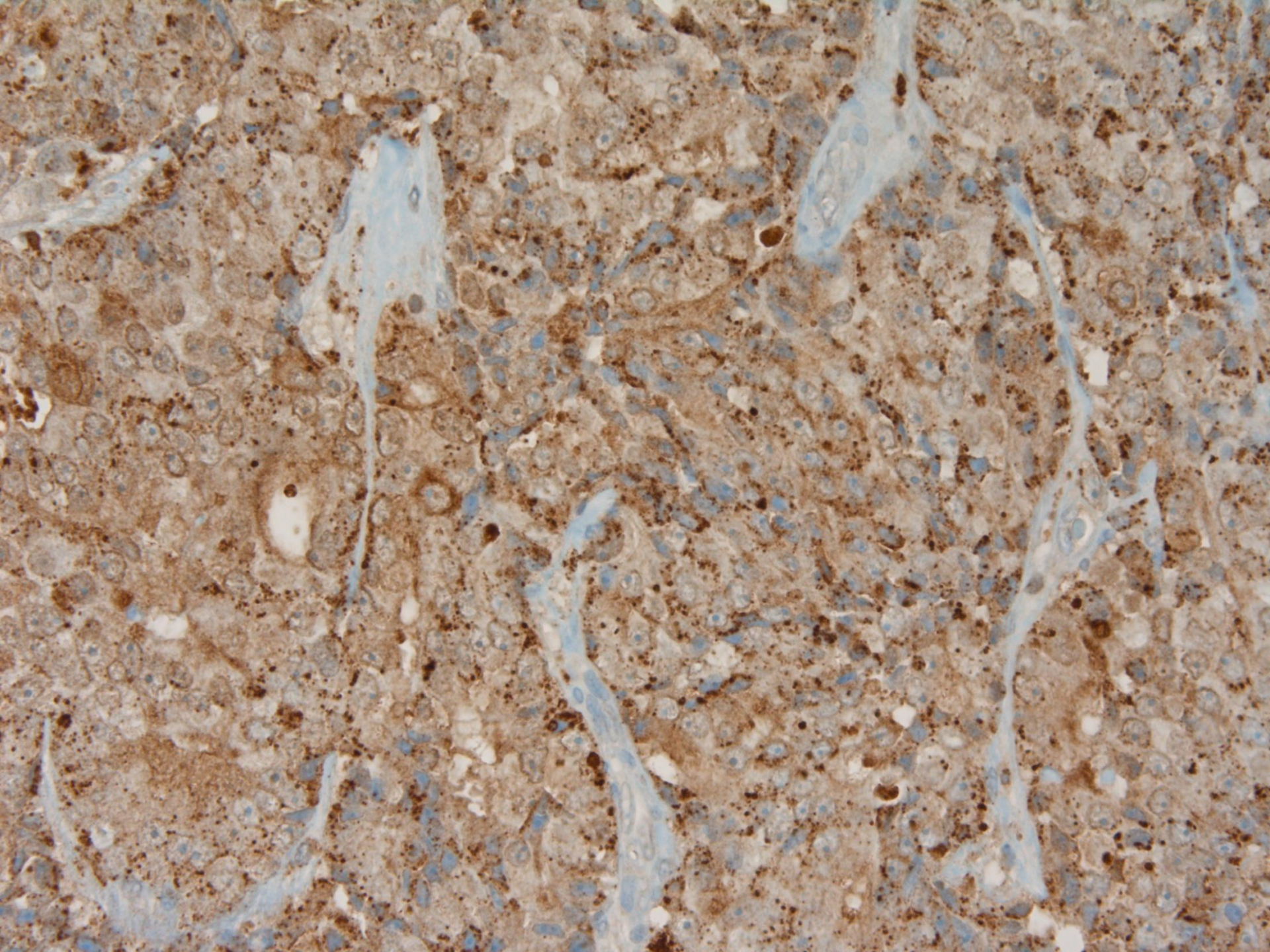
	Prostate	Non-prostate
N. monotony	+	-
Nucleolus	prominent	variable
Mitoses	rare	frequent

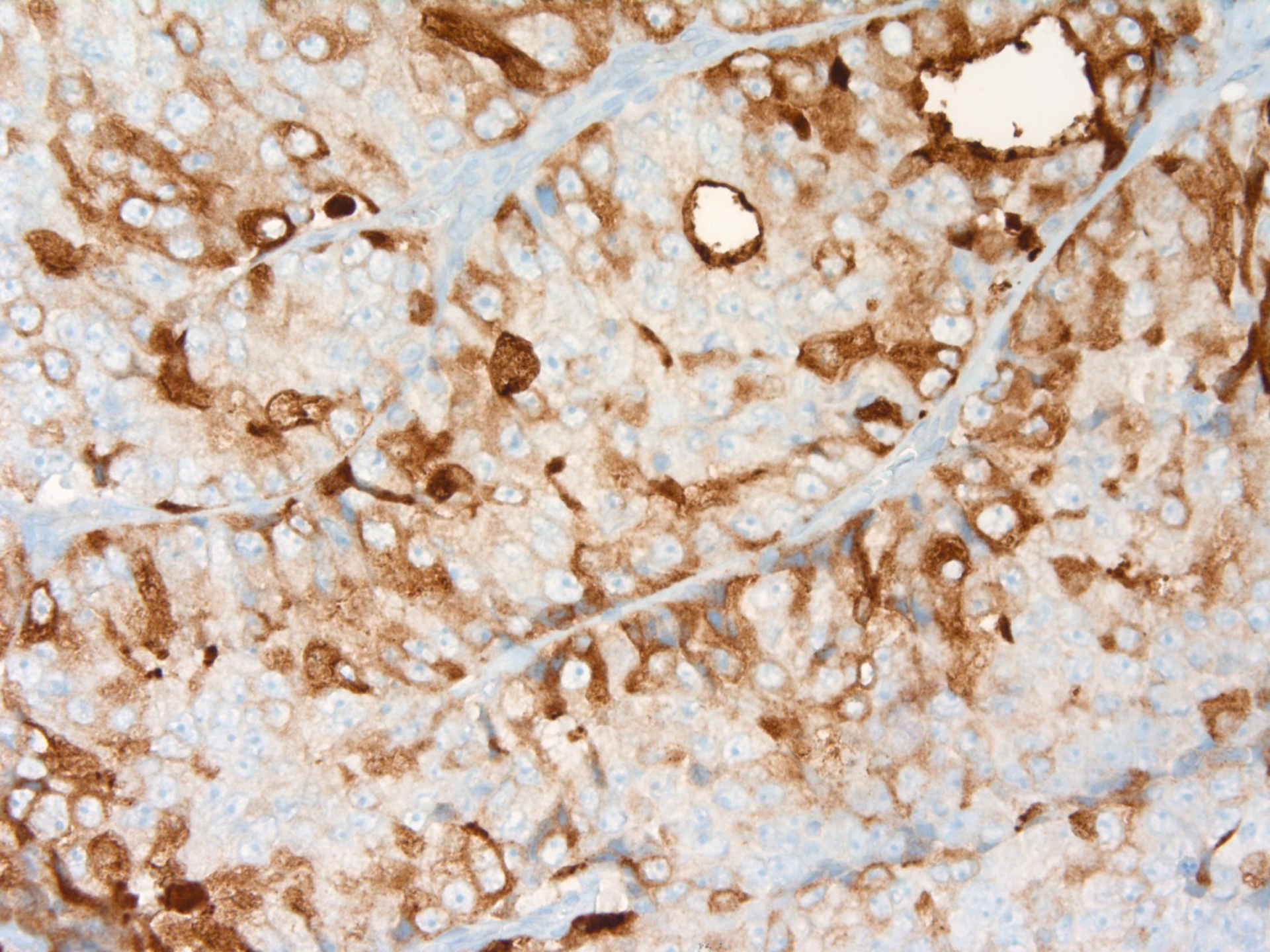
---

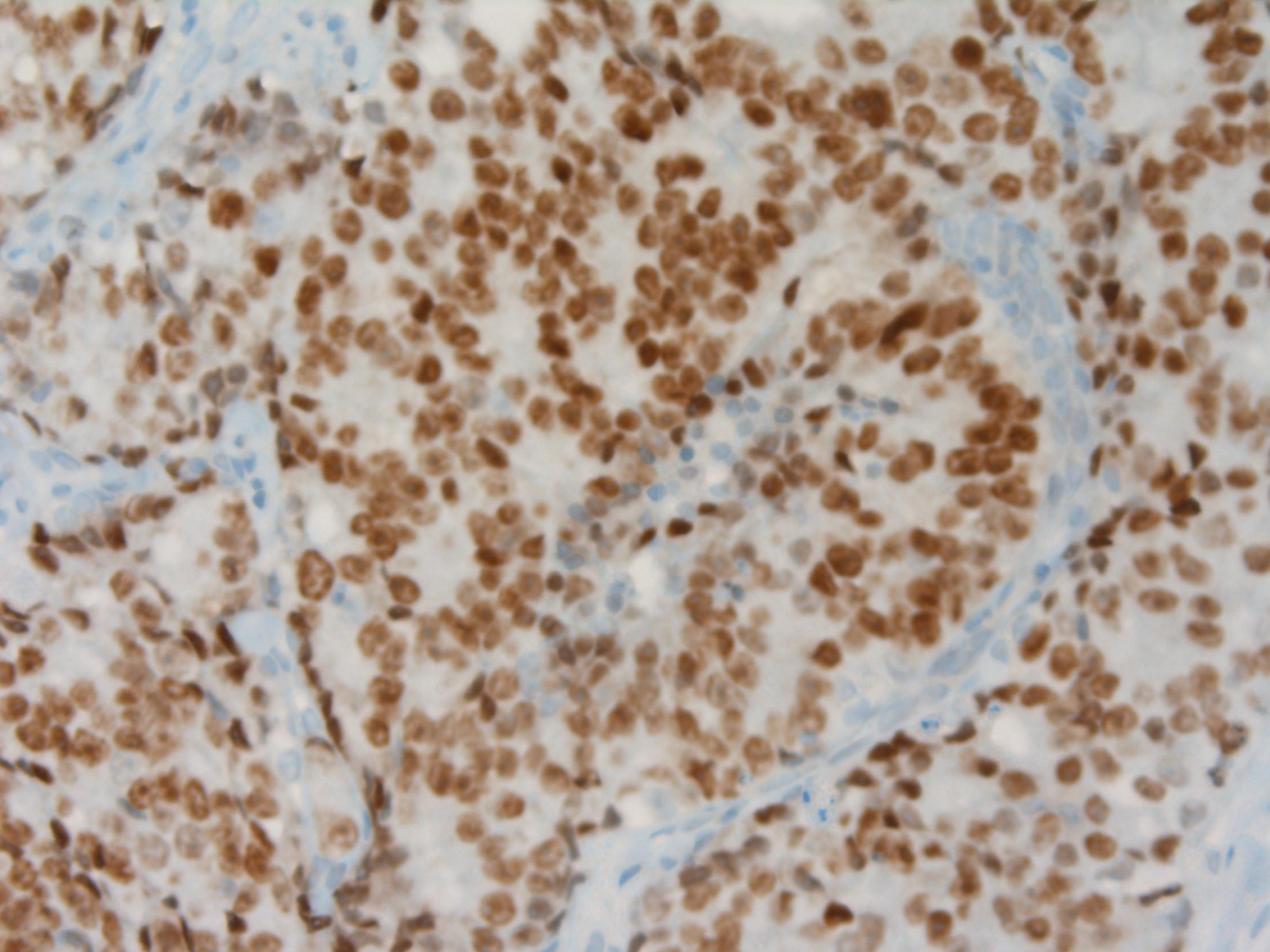




SL13-5794





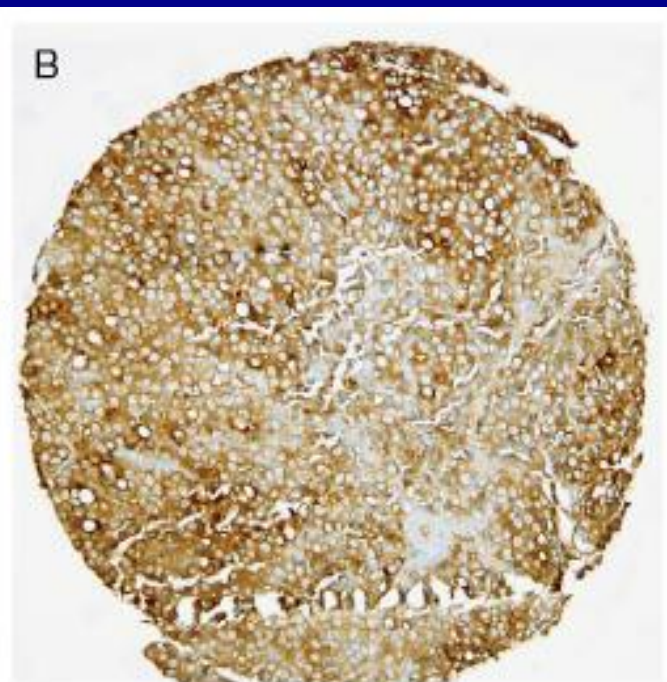
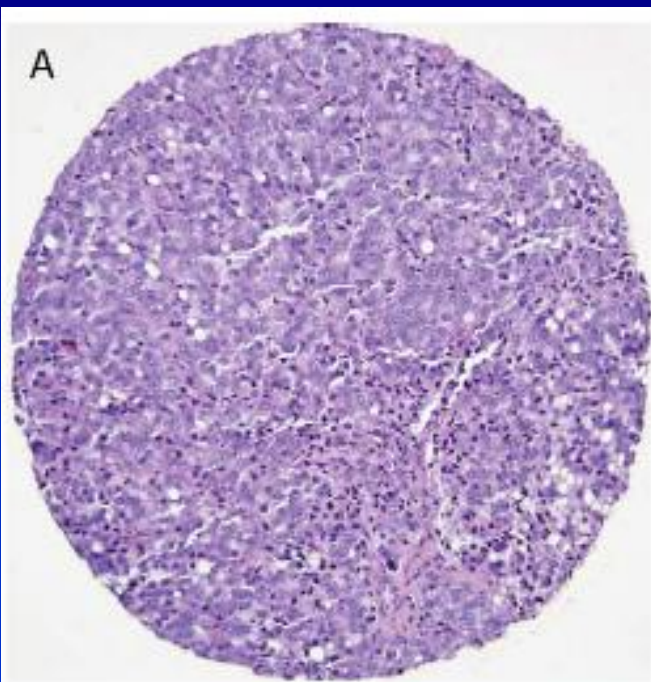


# High grade Undiff Ca

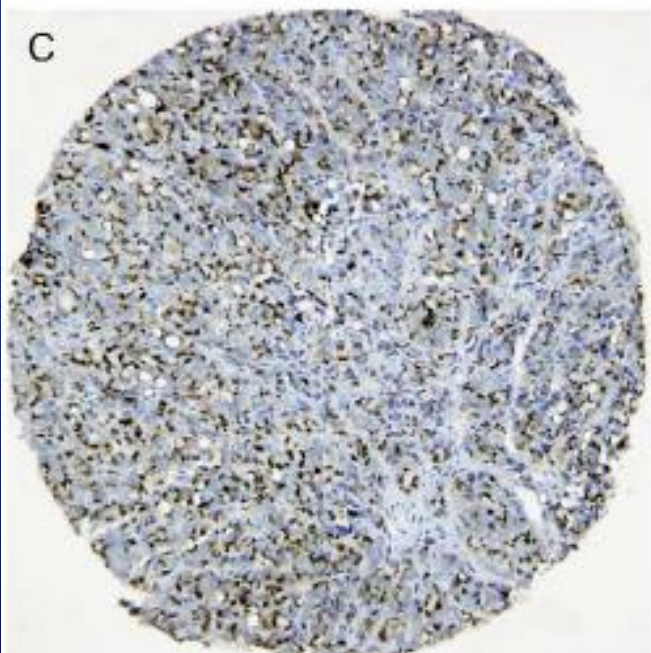
prostate

urothelial

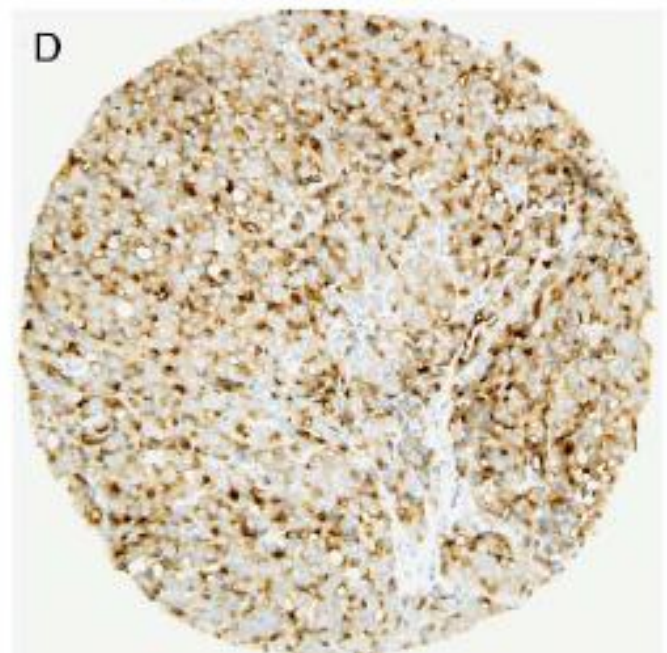
<b>PSA/PAP/PSMA</b>	<b>+</b>	<b>-</b>
<b>AMACR/NKX3.1.</b>	<b>+</b>	<b>-</b>
<b>HMCK</b>	<b>-/+ (6-10%)</b>	<b>+</b>
<b>Uroplakin</b>	<b>-</b>	<b>+ (65-100%)</b>
<b>Thrombomodulin</b>	<b>-</b>	<b>+ (49-69%)</b>
<b>P63</b>	<b>-/+ (-18%)</b>	<b>+ (70-75%)</b>
<b>CD57</b>	<b>+</b>	<b>-/+ (- 17%)</b>
<b>S100p</b>	<b>-</b>	<b>+ (78-86%)</b>
<b>GATA</b>	<b>-</b>	<b>+ (67%)</b>



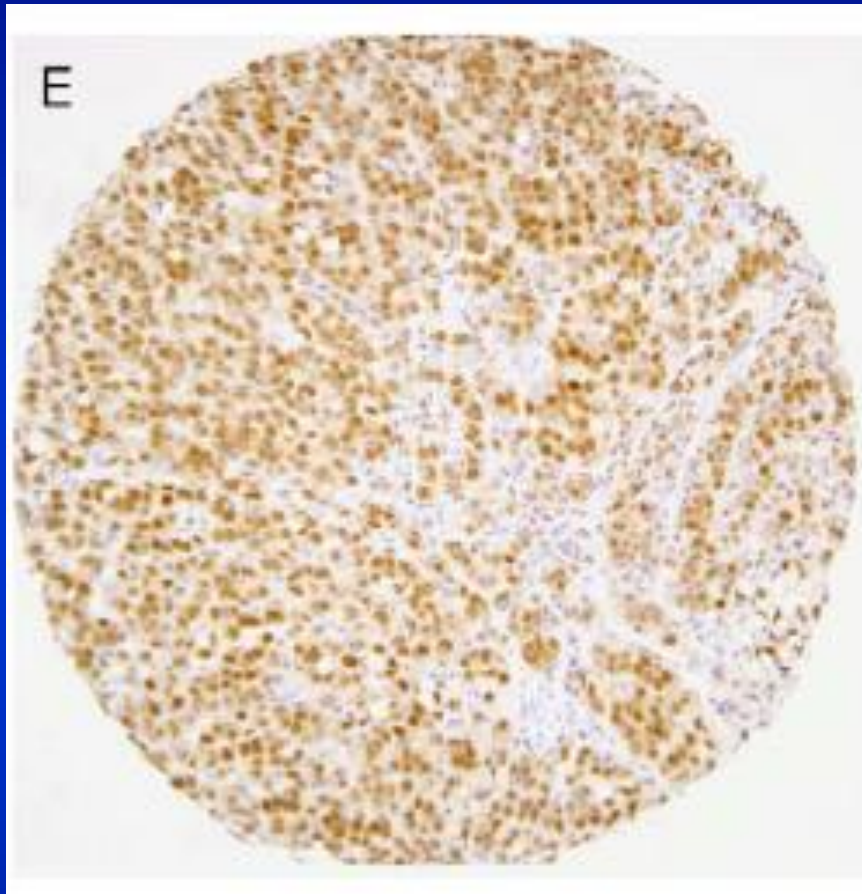
**PSA**



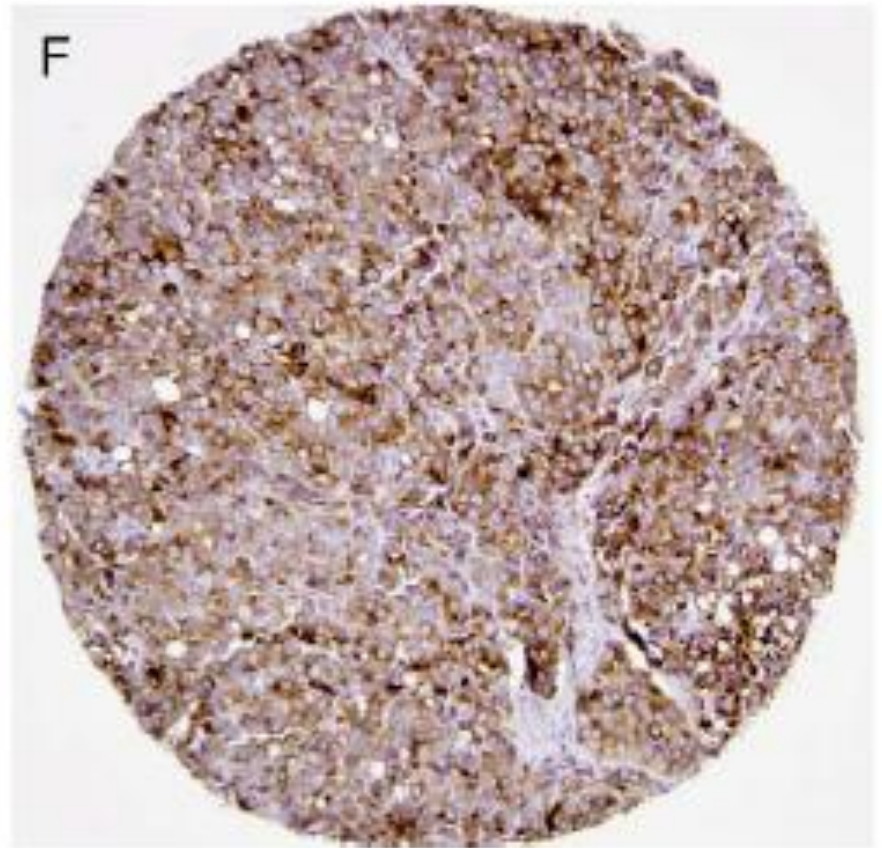
**P501S**



**PSMA**

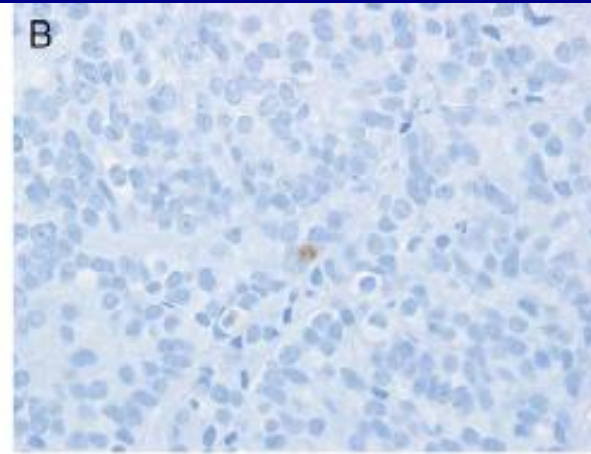
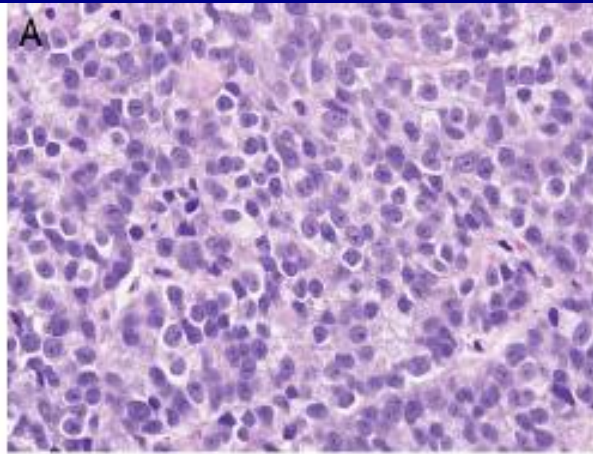


**NKX3.1.**

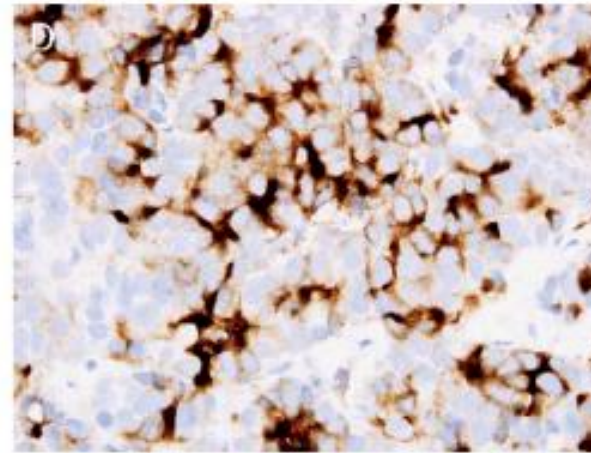
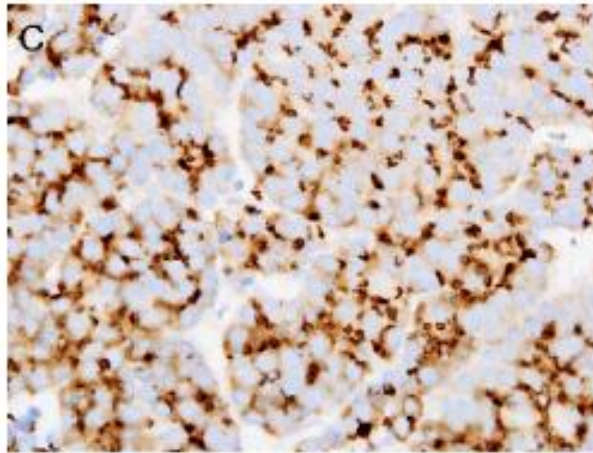


**pPSA**

**Am J Surg Pathol 2007;31:1246–1255**

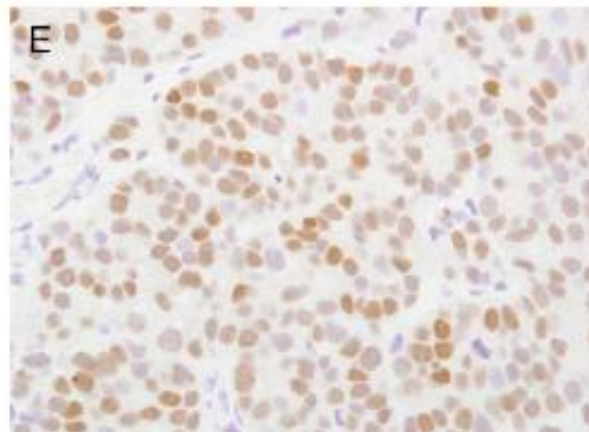


**PSA**

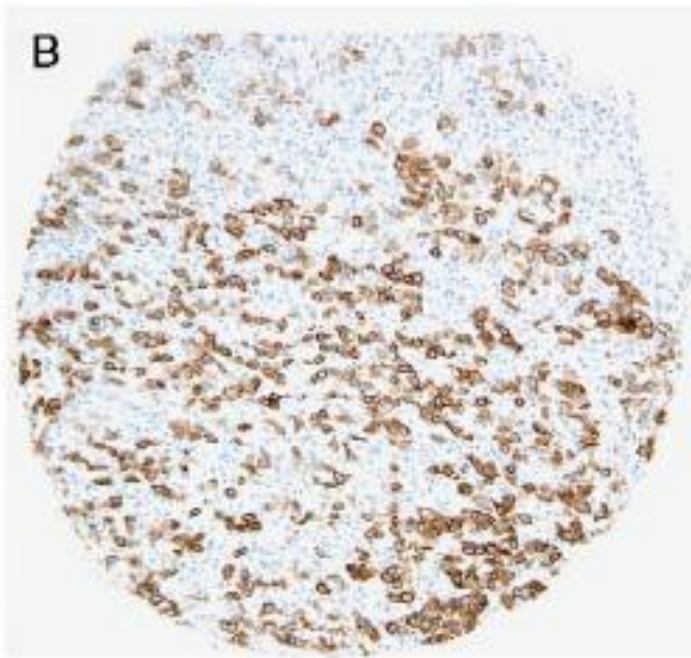
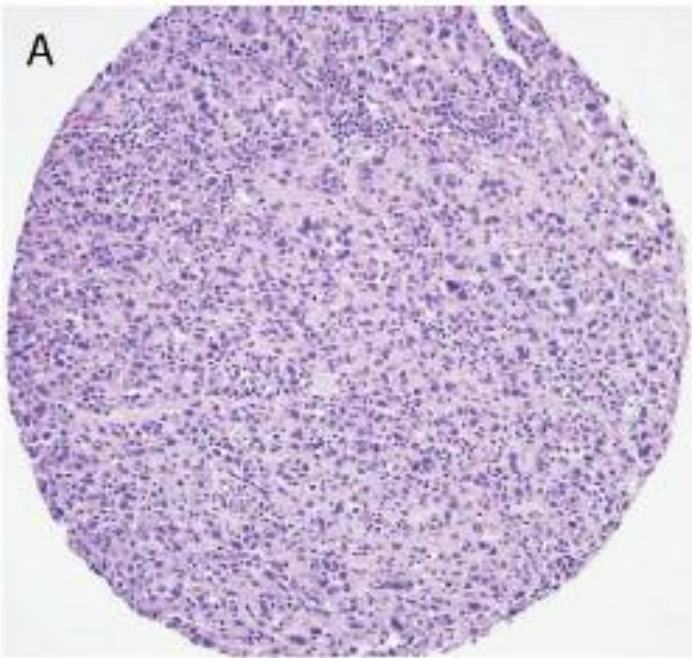


**PSMA**

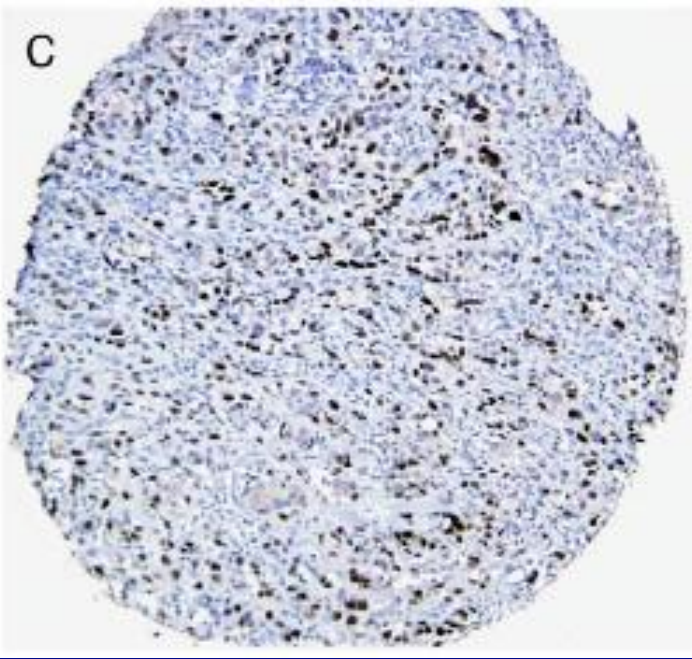
**P501S**



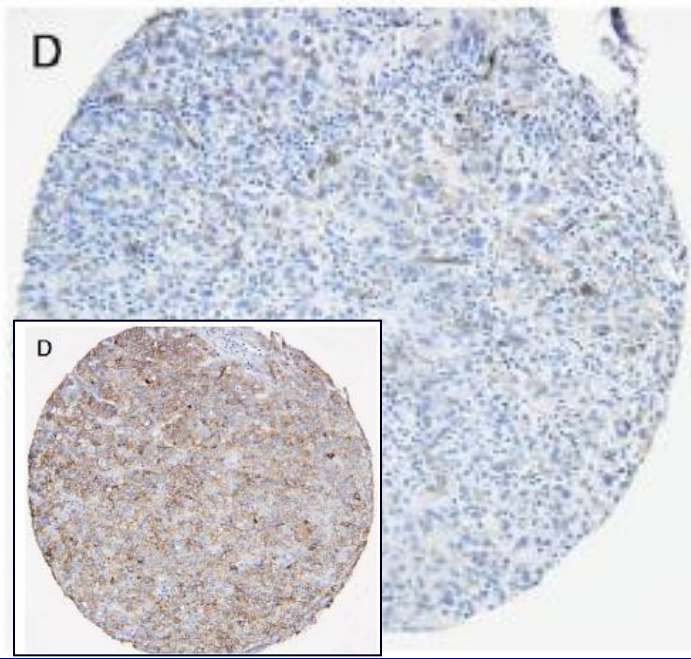
**NKA3.1**



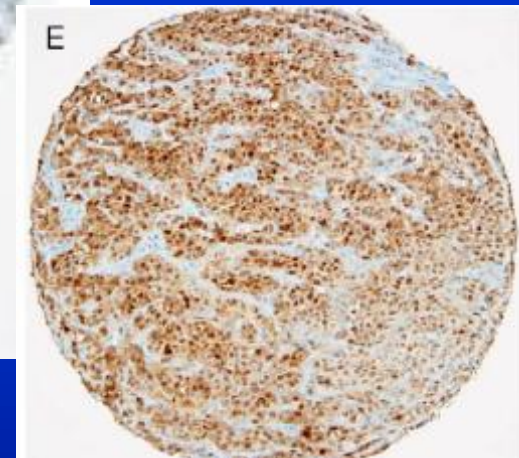
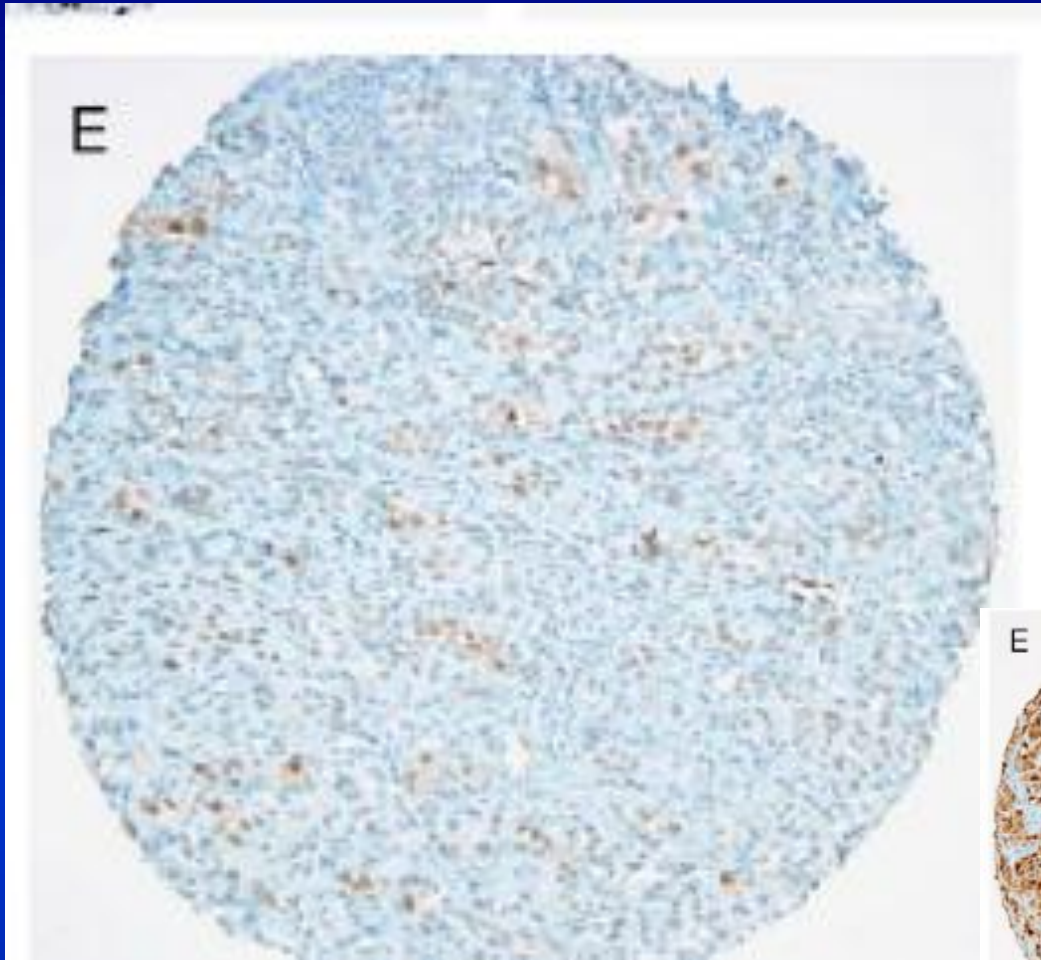
**HMCK**



**P63**



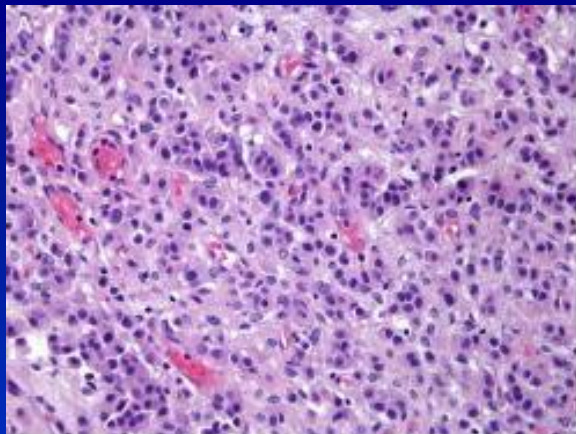
**Throm**



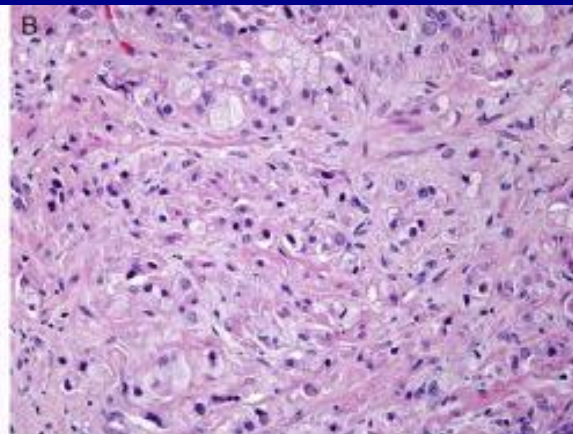
**S100P**

**Am J Surg Pathol 2007;31:1246–1255**

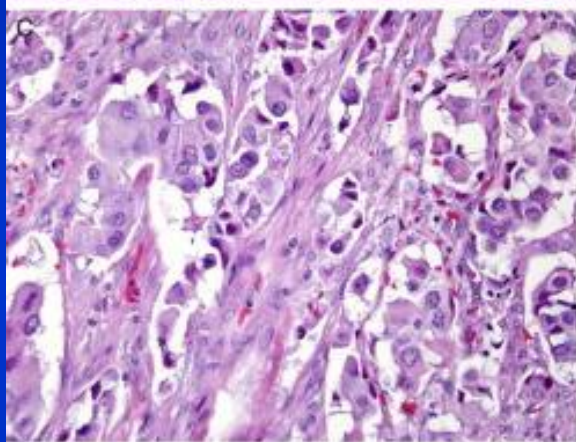
**UC**



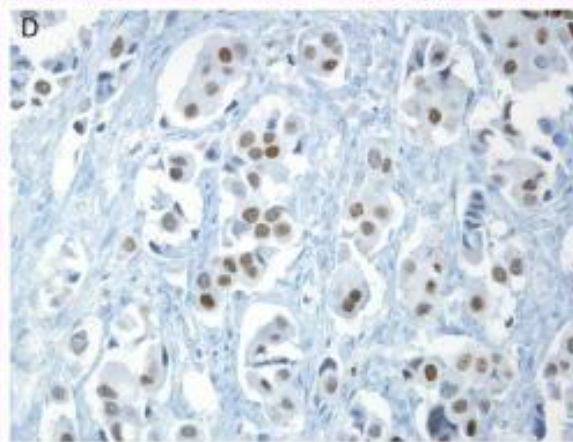
**Pca**



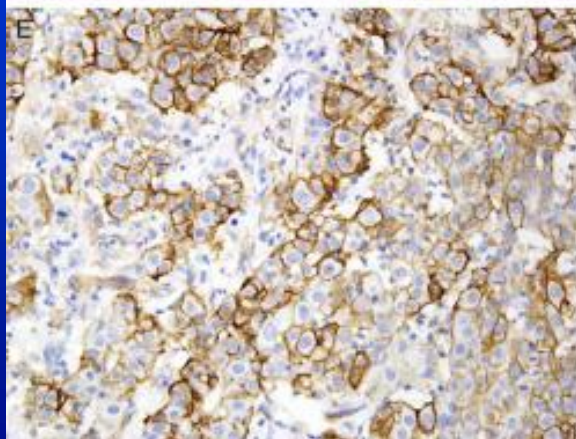
**UC**



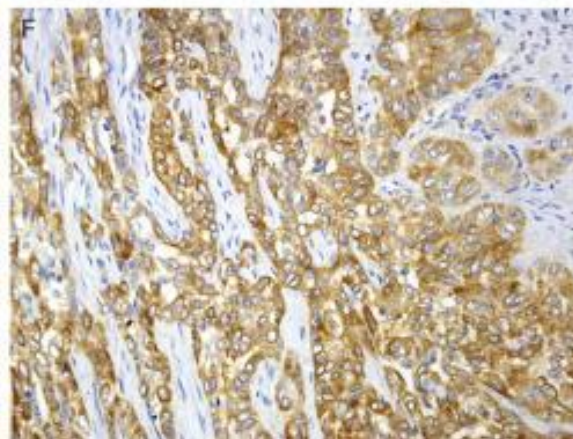
**GATA**



**Throm**



**Uroplakin**



# 3. Think

- **Diagnostic accuracy**
- **Prognostic/predictive factors**
- ✓ **Stage**
- ✓ **Grade (Gleason score)**
- ✓ **Non-anatomic factors (e.g., PSA)**
- **Keep 3 Cs practice (communication, consultation, collaboration)**

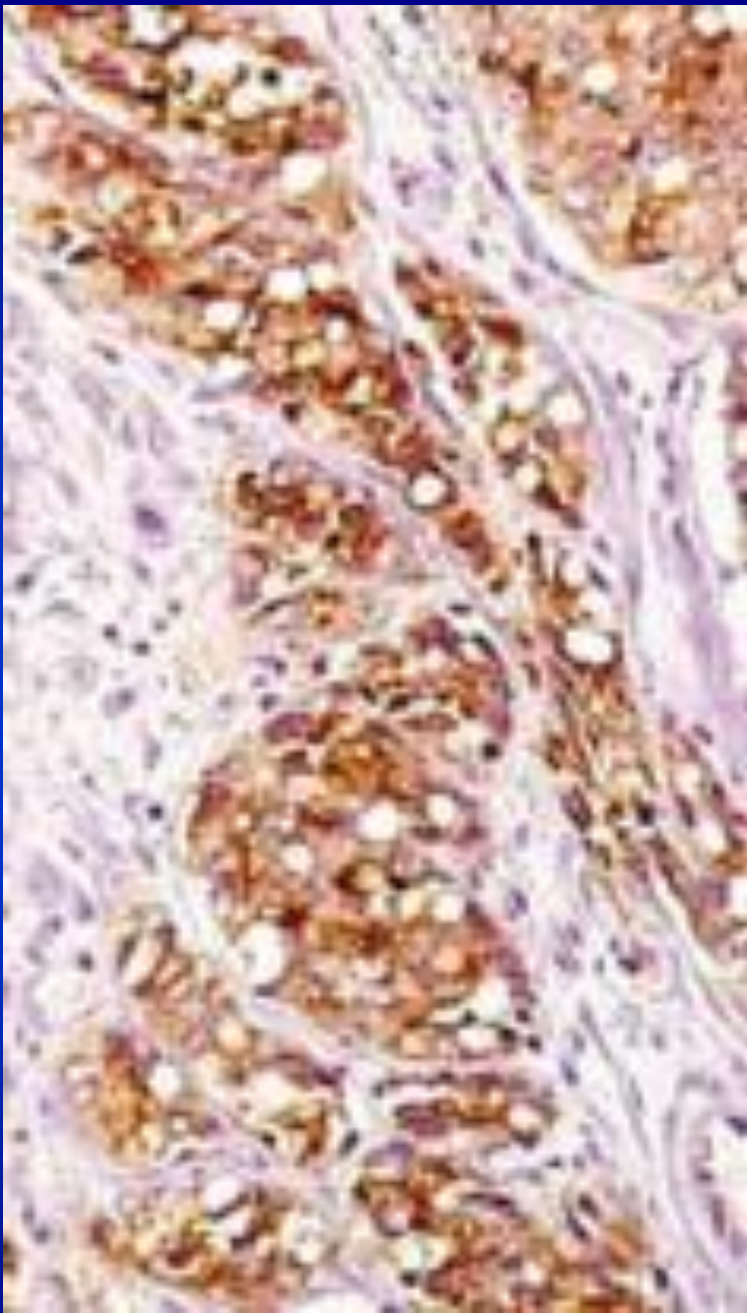
# 3. Think!

- **Prognostic factors**
  - **Category I (well supported): pTNM stage, Gleason grade, margin status (serum PSA)**
  - **Category II (extensively studied but not well established): volume (intraglandular extent), tumor subtype**
  - **Category III (currently studying): vascular invasion, perineural invasion**

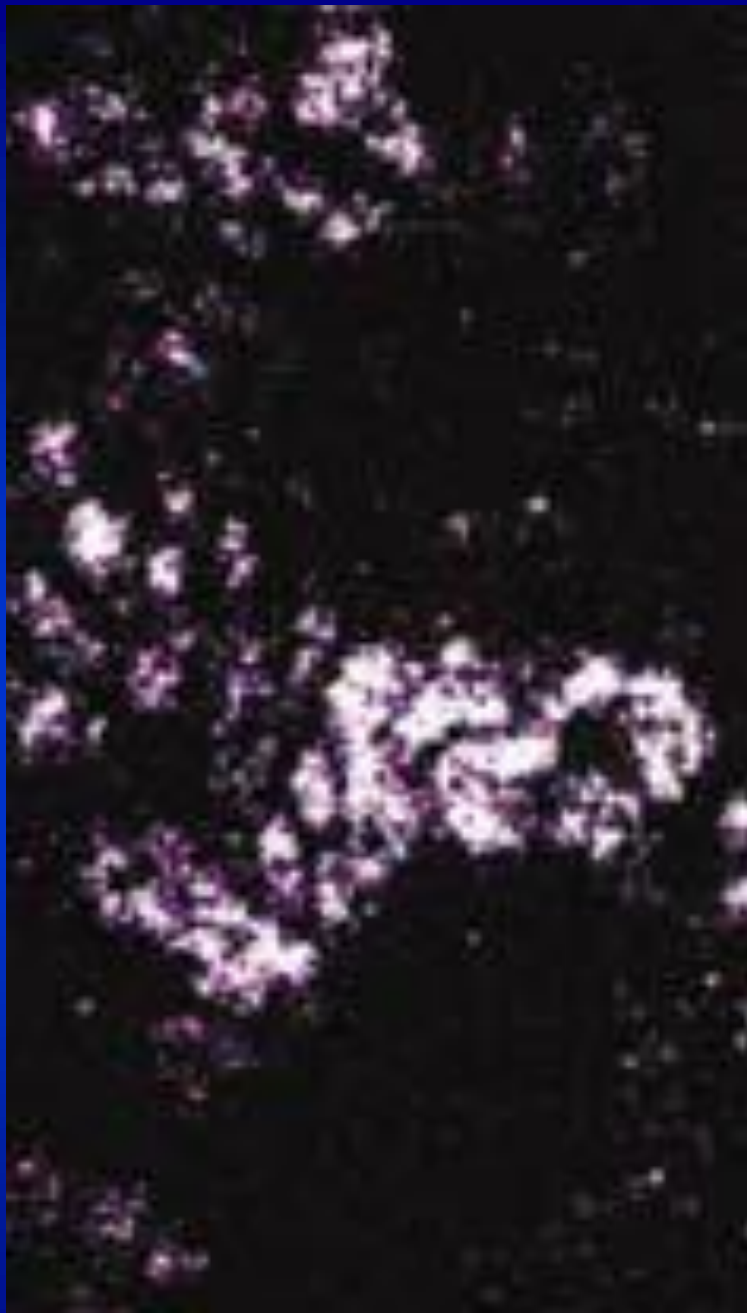
Serum PSA	ELISA	I	Standard practice
Pathologic stage	Routine pathologic examination	I	Standard practice
Tumor grade	Routine pathologic examination	I	Standard practice
Surgical margins	Routine pathologic examination	I	Standard practice
Tumor volume			
Needle biopsy summed percentages of involvement	Routine pathologic examination	II	In common use
Prostatectomy whole mounts	Special pathologic examination	II	In clinical use in some centers
Tumor type	Routine pathologic examination	II	Standard practice
Tissue PSA	Immunohistochemical analysis		Research only
Tissue PSMA	Immunohistochemical analysis		Research only
Androgen receptor	Immunohistochemical analysis	III	Research only
Ki-67 (MIB-1) labeling index	Immunohistochemical analysis	III	In clinical use in some centers
Other cell cycle (mitosis counts, PCNA, p27, p21, p34)	Immunohistochemical analysis		In clinical use in some centers
DNA ploidy	Flow or image cytometry	II	In clinical use in some centers
Cytogenetics	Karyotype and FISH		Research only
Morphometric features: roundness, texture	Image cytometry	III	Research only
→ Microvessel density	Immunohistochemical analysis; image cytometry	III	In clinical use in some centers
Nuclear matrix proteins	Immunohistochemical analysis		Research only
Cytokine expression	Immunohistochemical analysis		Research only
Growth factors and receptors	Immunohistochemical analysis; in situ hybridization		Research only
Cell adhesion molecules: E-cadherin, CD44, integrins	Immunohistochemical analysis; gene methylation assays	III	Research only
Invasion proteases	Immunohistochemical analysis; bioassays		Research only
Dominant oncogenes	Immunohistochemical analysis; sequencing		Research only
HER-2/neu	Immunohistochemical analysis; FISH; RT-PCR		Research only
p53	Immunohistochemical analysis; sequencing		In clinical use in some centers
PTEN/AKT	Immunohistochemical analysis		Research only
GST-π	Immunohistochemical analysis; gene methylation		Research only (RT-PCR test used in blood, urine, semen specimens in clinical use in some centers)
bcl-2 and apoptosis	Immunohistochemical analysis; TUNEL assay	III	In clinical use in some centers
Telomerase	TRAP assay; in situ hybridization		Research only
Microsatellite instability	PCR; electrophoresis		Research only
Human glandular kallikrein 2	Serum ELISA	III	Blood test in use in some clinical centers (prostate cancer detection)
Hepsin	Microarray		Research only
AMACR	Immunohistochemical analysis		In clinical use in some centers (diagnosis of microfocal cancers on needle biopsy specimens)
Ubiquitin and proteolysis	Immunohistochemical analysis; bioassays		Research only
NFκB	Immunohistochemical analysis		Research only
Expression profiling	Microarray		Research only

# Other prognostic markers

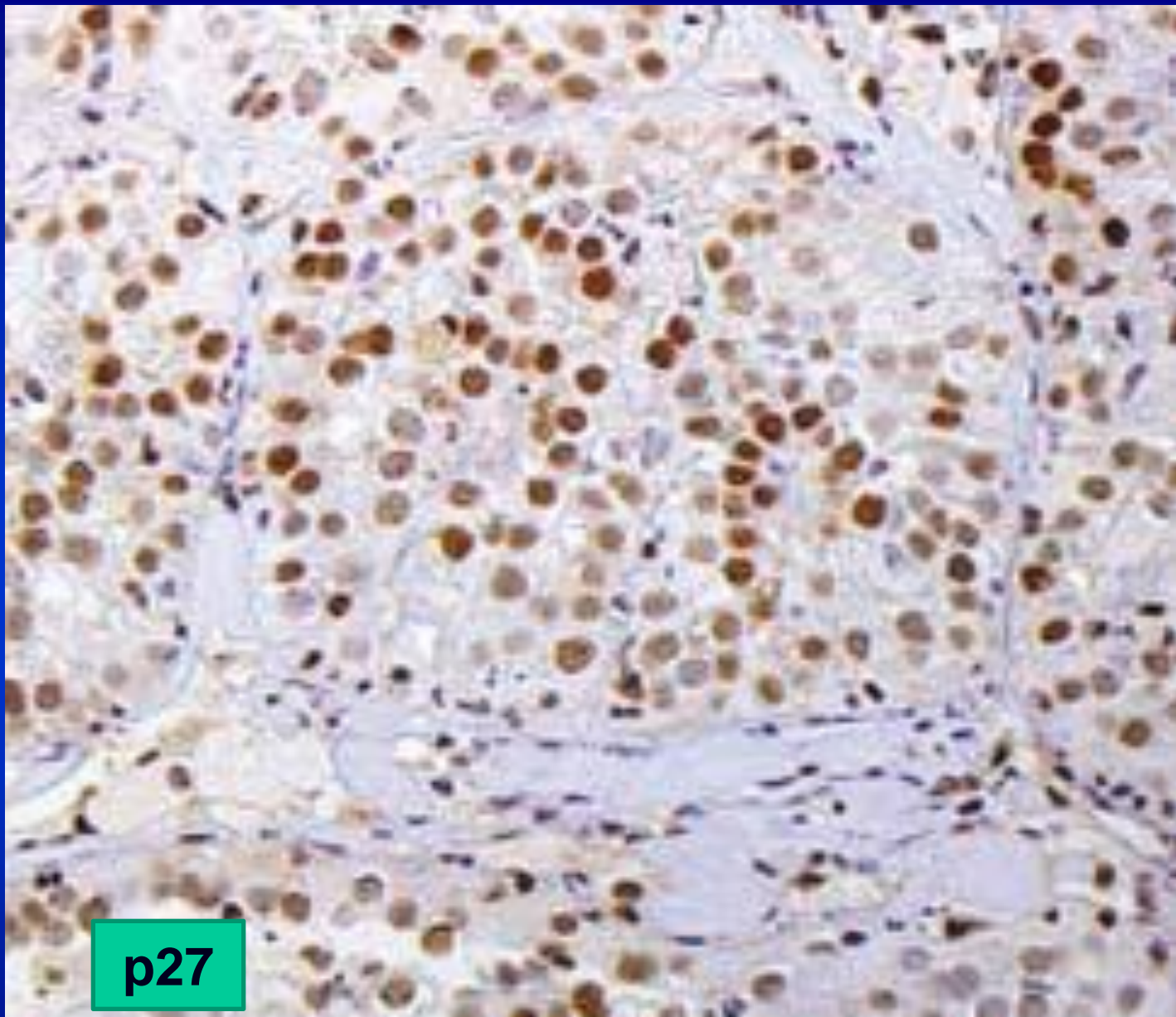
- The Ki-67 cell proliferation index
- p53
- bcl-2 immunostaining
- Anti-PSMA and p27
- Erg immunostaining
- INPP4B, and PTEN genes
- Claudin-4 and claudin-5
- DNA ploidy analysis



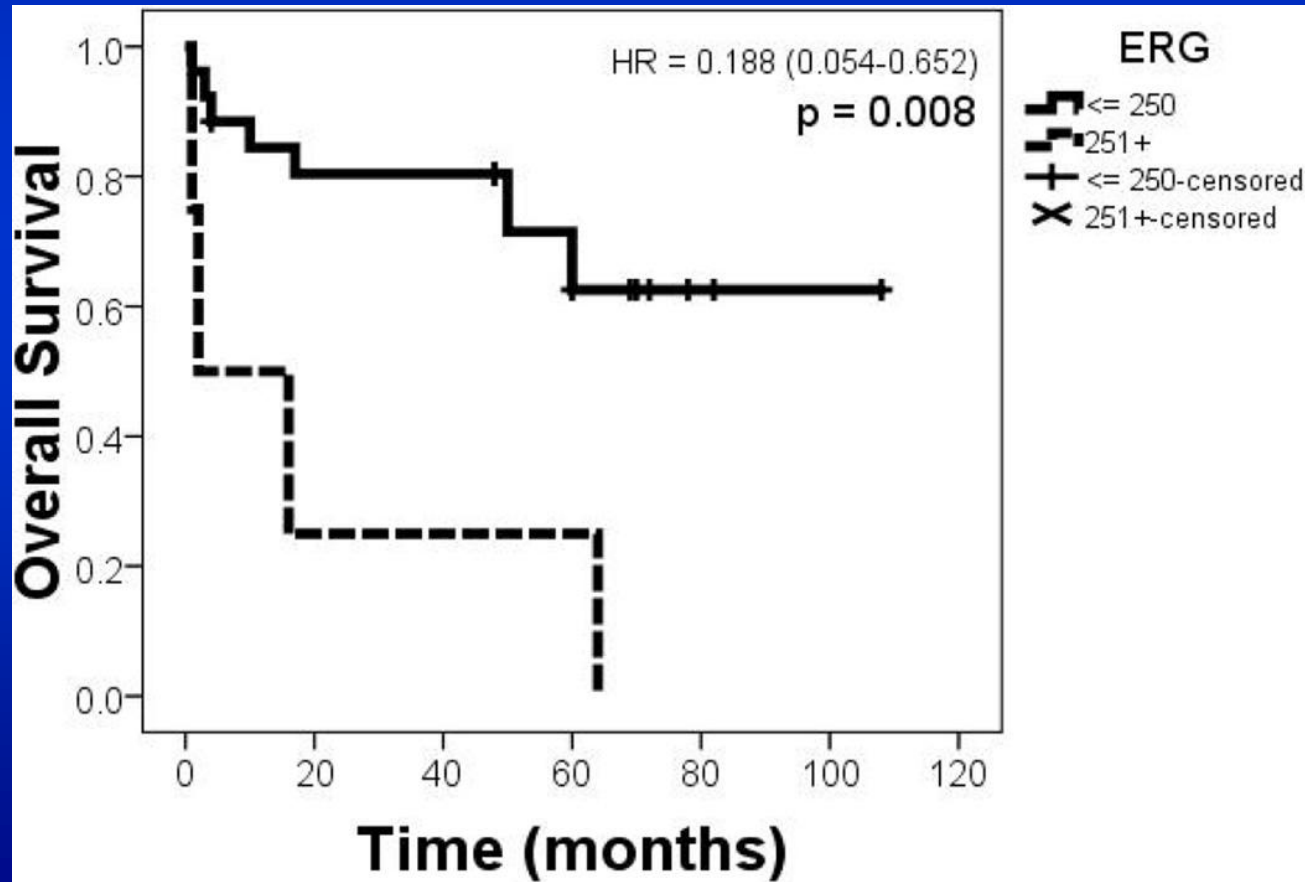
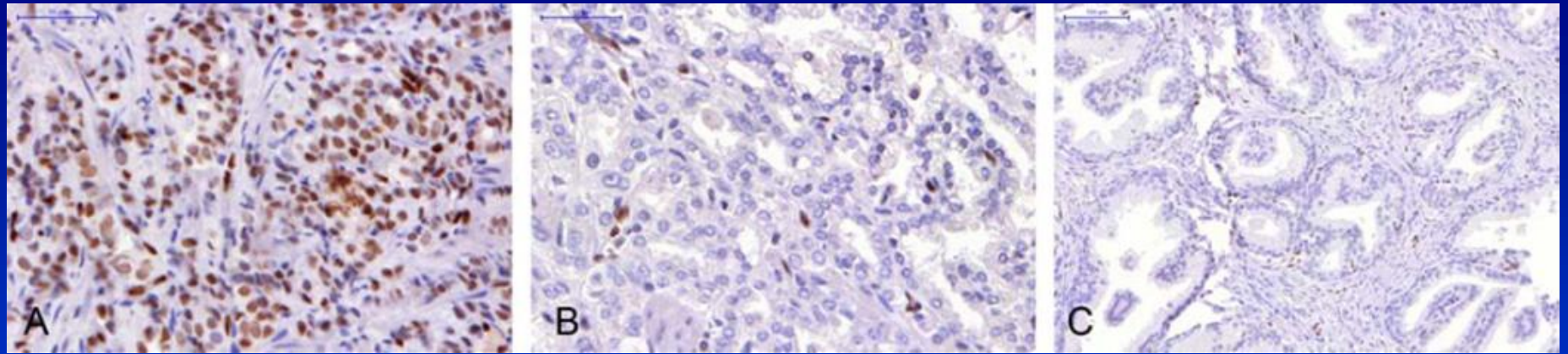
**Anti-PSMA**



**Anti-PSMA mRNA**

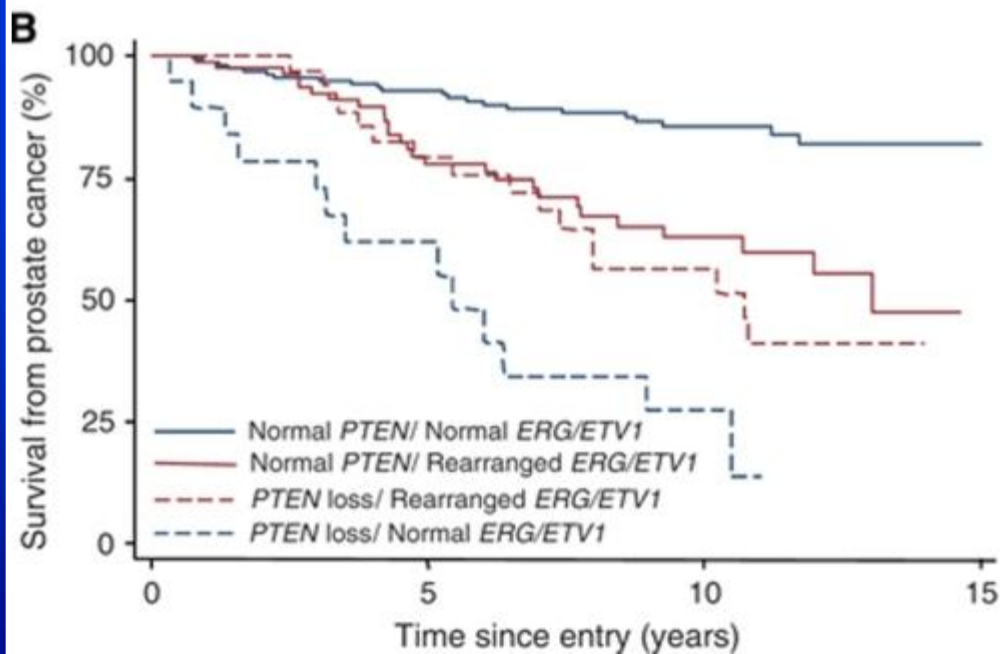
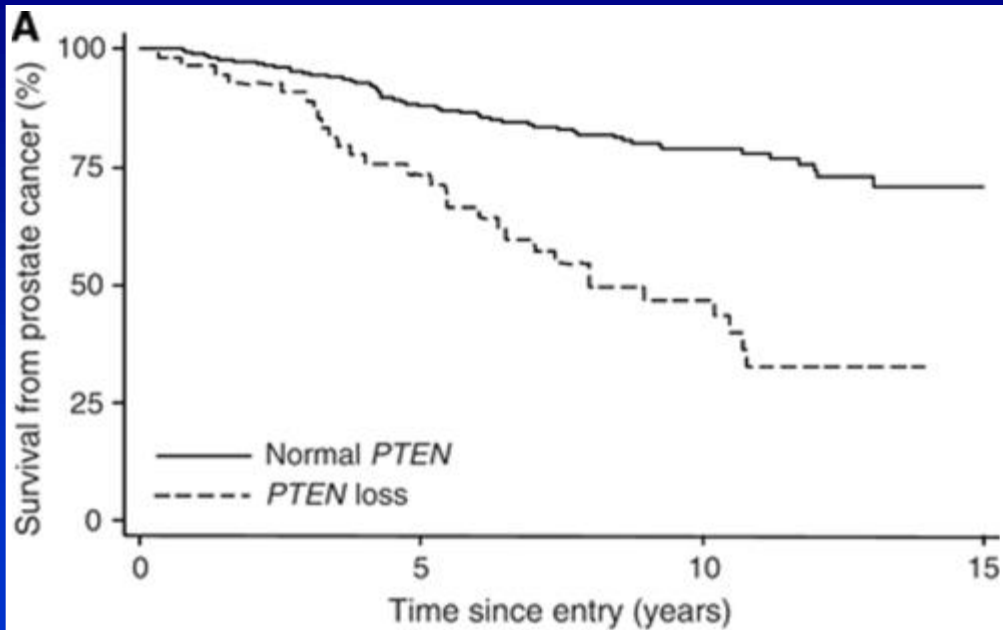


**Am J Clin Pathol 2003;120(Suppl 1):S85-S100**

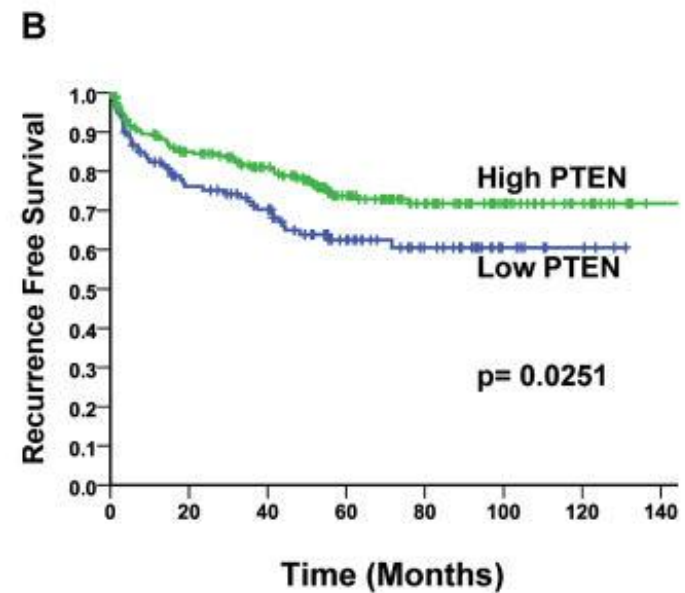
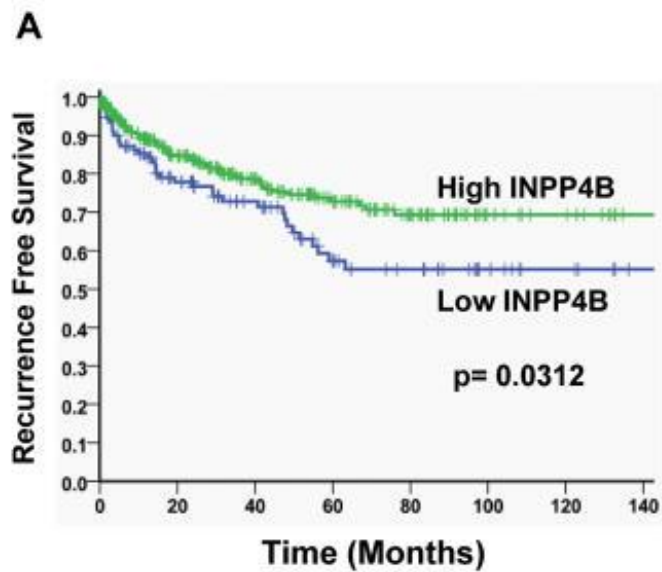


**Erg stain**

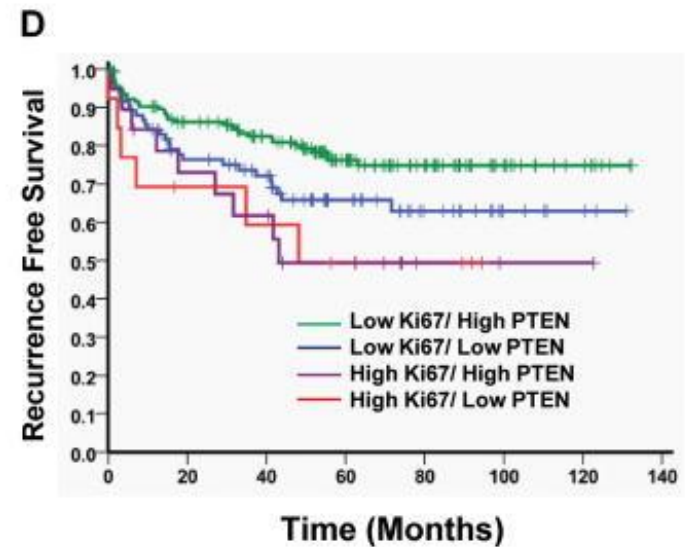
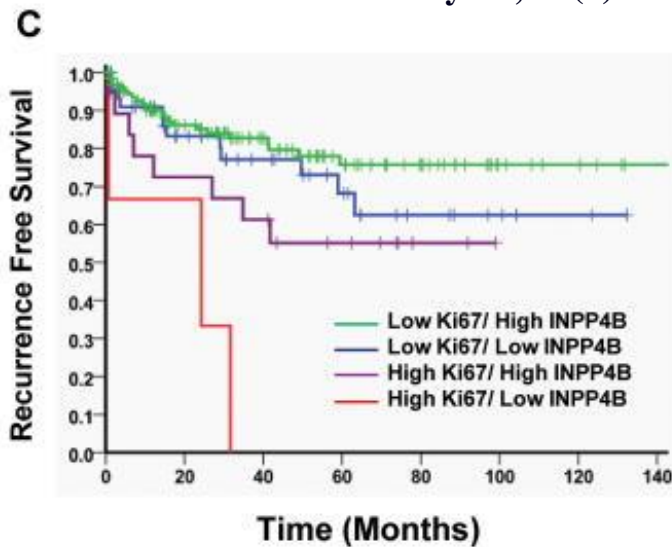
**Int Urol Nephrol**  
**2013;45:727-33.**



**Br J Cancer. 2010  
 February 16; 102(4):  
 678–684.**



Cancer Res. 2011 January 15; 71(2): 572–582.



**inositol polyphosphate 4-phosphatase type II (INPP4B)  
Phosphatase and tensin homolog (PTEN)**

# Prostate Cancer

- TX T0
- T1 clinically inapparent tumor (not palpable, not visible)
  - T1a  $\leq 5\%$  of tissue resected; T1b  $> 5\%$
  - T1c tumor identified by needle biopsy (elevated PSA)
- T2 Tumor confined within prostate
  - T2a involve  $\frac{1}{2}$  of one lobe or less
  - T2b more than  $\frac{1}{2}$  of one lobe
  - T2c both lobes
- T3 tumor extends through capsule,
  - T3a extracapsular, **bladder neck** extension (uni, bilateral)
  - T3b tumor invades seminal vesicle (s)
- T4 Rectum, ext sphincter, levator muscle, pelvic wall
- ✓ **No pathologic T1 classification**

# Regional Lymph Nodes (N)

<b>pNX</b>	Regional nodes not sampled
<b>pN0</b>	No positive regional nodes
<b>pN1</b>	Metastases in regional node(s)

## Distant Metastasis (M)

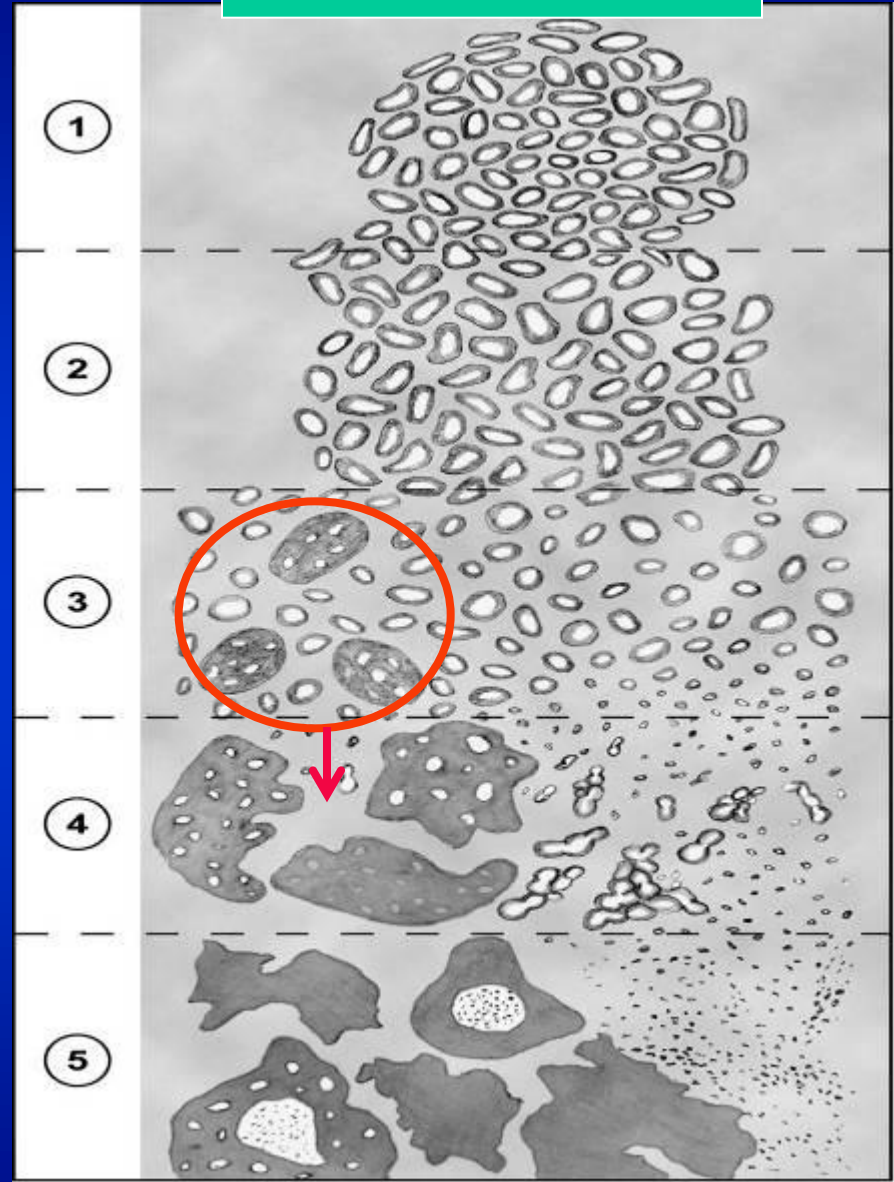
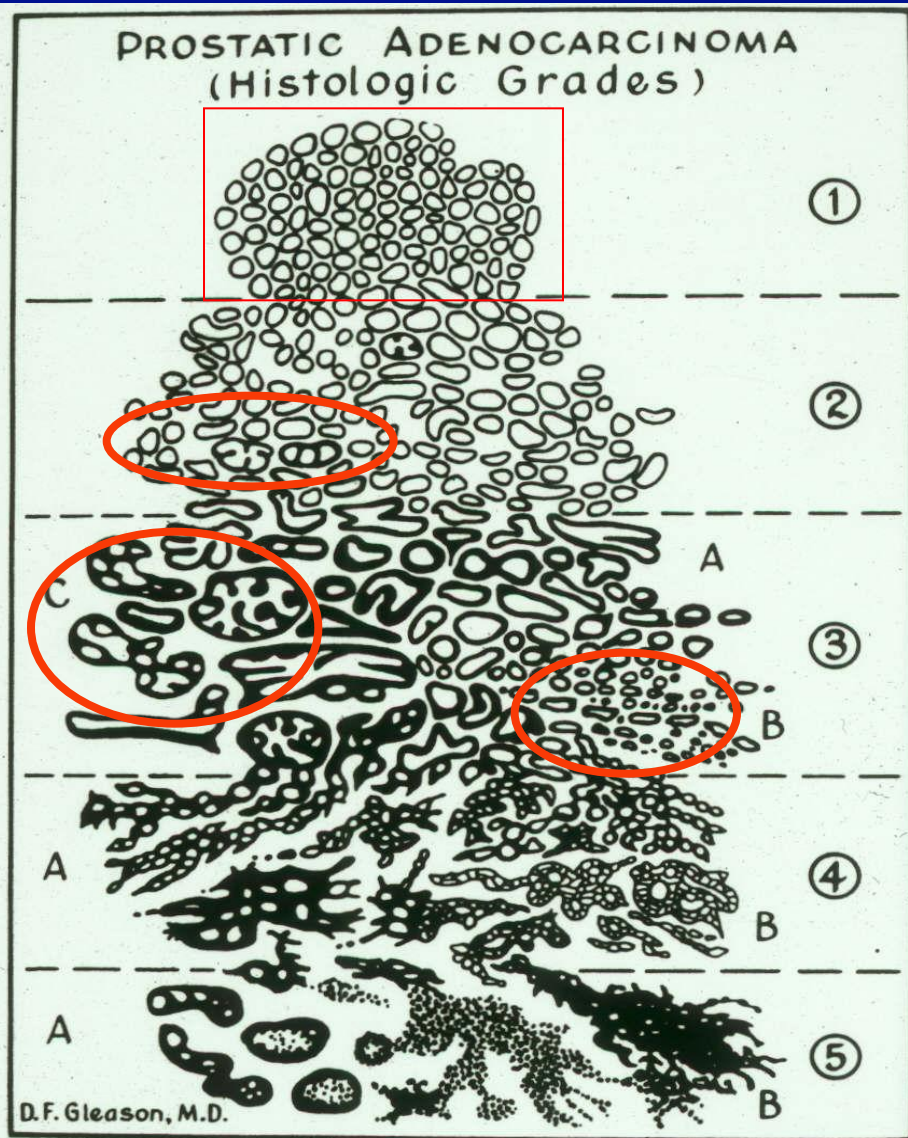
<b>MX</b>	No more MX in 7 <sup>th</sup> edition (AJCC, 2009)
<b>M0</b>	No distant metastasis
<b>M1</b>	Distant metastasis
<b>M1a</b>	Non-regional lymph node(s)
<b>M1b</b>	Bone(s)
<b>M1c</b>	Other site(s) with or without bone disease

# Anatomic stage/prognostic groups

<b>Group 1</b>	T1a-c	N0	M0 PSA<10	G <sub>≤</sub> 6
	T2a	N0	M0 PSA<10	G <sub>≤</sub> 6
	T1-2a	N0	M) PSA X	G X
<b>Group IIA</b>	T1a-c	N0	M0 PSA<20	G7
	T1a-c	N0	M0 PSA<20	G <sub>≤</sub> 6
	T2a	N0	M0 PSA<20	G <sub>≤</sub> 7
	T2b	N0	M0 PSA<20	G <sub>≤</sub> 7
	T2b	N0	M0 PSA X	G X
<b>Group IIB</b>	T2c	N0	M0 any PSA	Any G
	T1-2	N0	M0 PSA <sub>≥</sub> 20	Any G
	T1-2	N0	M0 any PSA	G <sub>≥</sub> 8
<b>Group III</b>	T3a-b	N0	M0 any PSA	Any G
<b>Group IV</b>	T4	N0	M0 any PSA	Any G
	Any T	N1	M0 any PSA	Any G
	Any T	Any N	M1 any PSA	Any G

Original, 1977

Revision, 2005

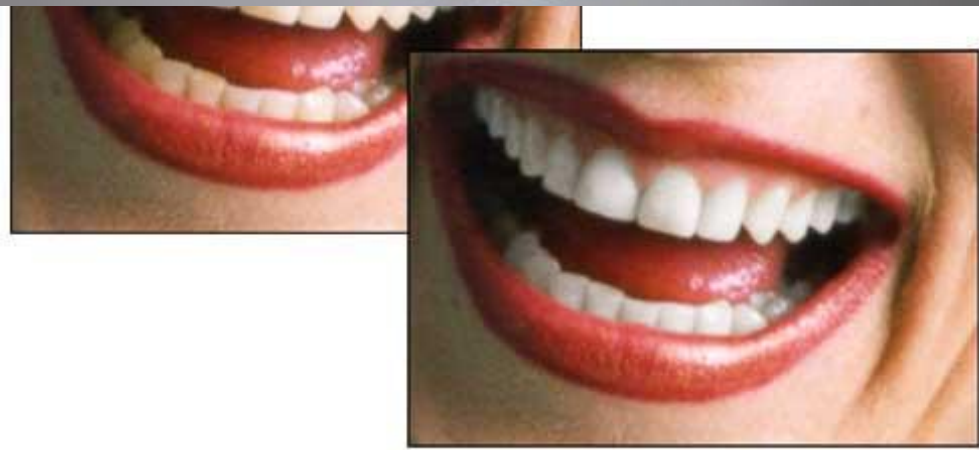


New Revision, 2010,2011, cribriform, 4 or 5

# **4. Enjoy**

**Joy and Fun**

**Enjoy what you are doing!**



# Take Home Message

- **Basic:**
- **Study:**
- ✓ **Diagnosis**
- ✓ **DD between prostate vs. non-prostate**
- ✓ **Prognosis/predictive markers**
- **Think:**
- ✓ **how to report pathologic findings,**
- ✓ **prognostic factors (stage and grade, PSA)**
- **Enjoy: joy and fun**

**Thank you for your attention!**



***Urological pathologists***